



**PATIENT**

Burney Tittle

**SPECIES**

Canine

**BREED**

Cavalier King Charles  
spaniel

**SEX**

Male, neutered

**AGE**

4 Yrs. 7 months

**WEIGHT**

**INTERPRETED BY**

Andrea Nicastro, DVM,  
Diplomate ACVIM  
(*Small Animal Internal  
Medicine*)

**IMAGING  
PERFORMED BY**

Andrea Nicastro, DVM,  
Diplomate ACVIM  
(*Small Animal Internal  
Medicine*)

**HOSPITAL NAME**

Trinity Island

**REFERRING VET**

Dr. Oldham

**INVOICE**

13627

**DATE**

3/24/26

**PRESENTING CLINICAL SIGNS**

Pt has a history of chronic persistent diarrhea for a month. The diarrhea is orange in color. No recent vomiting, still eating well. Owner does not think there has been any weight loss. CBC chem unremarkable. Resting cortisol 1.5. Being treated with Metronidazole as needed.

**ULTRASONOGRAPHIC EXAMINATION OF THE ABDOMEN**

**Urinary System**

The urinary bladder wall is normal in thickness and the mucosal surface is smooth. The bladder is moderately distended. Luminal contents are anechoic. No cystic calculi are observed. The region of the trigone and the proximal urethra, visible to a depth of 2 cm, are normal.

The prostate is normal in size (0.84 cm in width) and shape. Parenchyma is homogenous. The prostatic urethra appears normal without evidence of dilation or obstruction.

The left kidney is normal in size (3.79 cm in length) with a normal shape, architecture and smooth peripheral margins. There is a normal 1:3 cortex to medulla ratio with normal corticomedullary distinction. There is no evidence of pyelectasia, nephroliths, infarcts or hydroureter. Renal vasculature is normal.

The right kidney is normal in size (4.33 cm in length) with a normal shape, architecture and smooth peripheral margins. There is a normal 1:3 cortex to medulla ratio with normal corticomedullary distinction. There is no evidence of pyelectasia, nephroliths, infarcts or hydroureter. Renal vasculature is normal.

**Adrenal Glands**

The left adrenal gland is normal in size (0.38 cm at cranial pole) (0.32 cm at caudal pole) with a normal shape and homogenous parenchyma. The glandular echogenicity and detail are unremarkable. Capsule, cortex, and medullary definition are normal. The phrenicoabdominal vein and surrounding vasculature are normal.

The right adrenal gland is normal in size (0.63 cm at cranial pole) (0.48 cm at caudal pole) with a normal shape and homogenous parenchyma. The glandular echogenicity and detail are unremarkable. Capsule, cortex, and medullary definition are normal. The phrenicoabdominal vein and surrounding vasculature are normal.

**Spleen**

The spleen is normal in size (1.00 cm in width at the level of the hilus) with a normal capsular contour. There is appropriate echogenicity and echotexture. No focal lesions are observed. Splenic vasculature is normal.

**Liver**

The liver is subjectively normal in size with normal contours and structure. There is appropriate echogenicity and echotexture. No overt structural evidence of inflammatory, infiltrative, or regenerative pathology is evident. Vascular and biliary tracts are of normal volume with no evidence of congestion. The portal vein to caudal vena cava ratio is approximately 1:1.

The gallbladder is of normal contours and contains some dependent echogenic debris. The wall is normal in thickness. No choleliths are observed. The cystic and common bile ducts are normal.

**Gastrointestinal**



**PATIENT**

Burney Tittle

**SPECIES**

Canine

**BREED**

Cavalier King Charles  
spaniel

**SEX**

Male, neutered

**AGE**

4 Yrs. 7 months

**WEIGHT**

**INTERPRETED BY**

Andrea Nicastro, DVM,  
Diplomate ACVIM  
(*Small Animal Internal  
Medicine*)

**IMAGING  
PERFORMED BY**

Andrea Nicastro, DVM,  
Diplomate ACVIM  
(*Small Animal Internal  
Medicine*)

**HOSPITAL NAME**

Trinity Island

**REFERRING VET**

Dr. Oldham

**INVOICE**

13627

**DATE**

3/24/26

The gastric lumen is not distended. The gastric wall and pylorus are normal in thickness with a normal layering pattern. The pyloric outflow tract is patent. The small intestinal lumen is not dilated. The small intestinal wall is normal in thickness with a normal layering pattern and appropriate mural detail. Discreet masses are not identified. The ileocecolic junction and colonic wall are normal. There is no evidence of an obstructive pattern.

***Pancreas***

The region of the pancreas is isoechoic relative to surrounding omental fat. No obvious parenchymal abnormalities are observed. There is no evidence of regional inflammation or effusion.

***Lymph nodes***

1-2 prominent mesenteric lymph nodes are visualized, one of the nodes measuring 2.57 x 0.33 cm.

***Free Abdomen***

The peritoneal cavity is normal. There is no evidence of inflammation or effusion.

***Other***

A brief echocardiogram reveals no evidence of pericardial effusion or obvious right atrial/auricular mass.

**ULTRASONOGRAPHIC FINDINGS**

- The lymph node changes are most consistent with reactive lymphadenitis or lymphoid hyperplasia.
- The abdomen is otherwise structurally unremarkable.

\*\*An obvious cause for the patient's clinical signs is not definitively identified in this study. Considerations include a microscopic enteropathy (i.e., food allergy/intolerance, inflammatory bowel disease, infectious/parasitic disease), underlying metabolic issue, other.

**INTERPRETATION OF THE FINDINGS & FURTHER RECOMMENDATIONS**

Given the patient's clinical history, consider the following:

1. Despite the negative fecal evaluation, consider prophylactic deworming with fenbendazole.
2. A probiotic as well as a fiber supplement may prove beneficial.
3. A GI panel including serum cobalamin, folate, TLI and PLI is also recommended.
4. Given the borderline resting cortisol level, a full ACTH stimulation test is recommended to assess for hypoadrenocorticism.
5. Depending on the results of the above diagnostics, a limited antigen or hydrolyzed protein diet trial +/- endoscopic or surgical GI biopsies may be indicated.



**PATIENT**

Burney Tittle

**SPECIES**

Canine

**BREED**

Cavalier King Charles spaniel

**SEX**

Male, neutered

**AGE**

4 Yrs. 7 months

**WEIGHT**

**INTERPRETED BY**

Andrea Nicastro, DVM,  
 Diplomate ACVIM  
 (Small Animal Internal  
 Medicine)

**IMAGING PERFORMED BY**

Andrea Nicastro, DVM,  
 Diplomate ACVIM  
 (Small Animal Internal  
 Medicine)

**HOSPITAL NAME**

Trinity Island

**REFERRING VET**

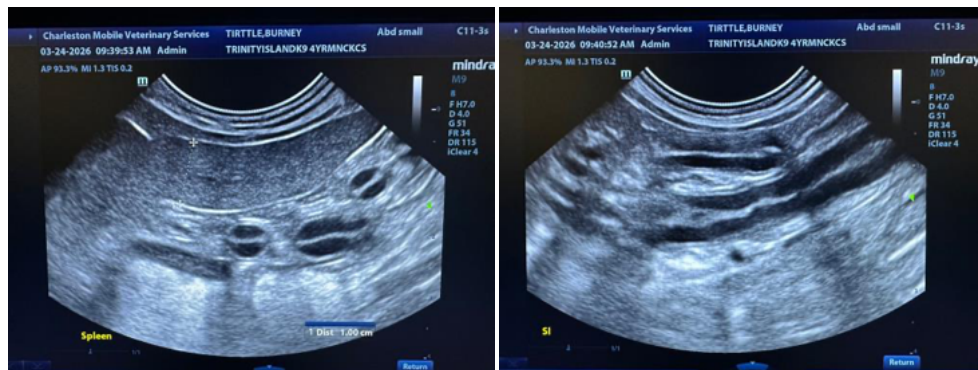
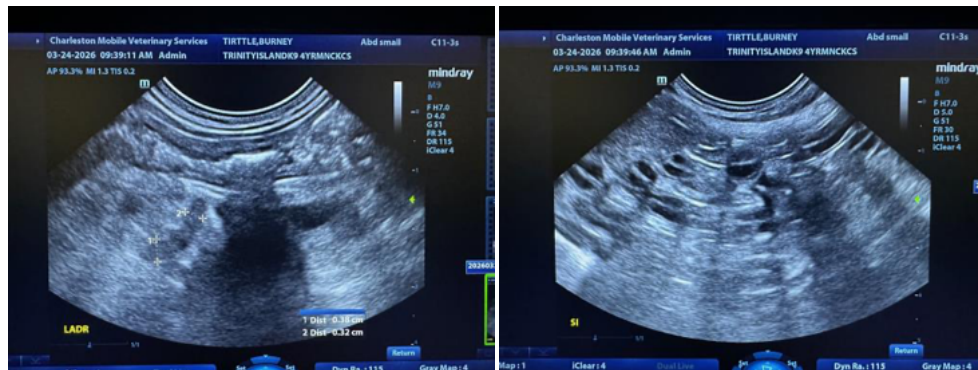
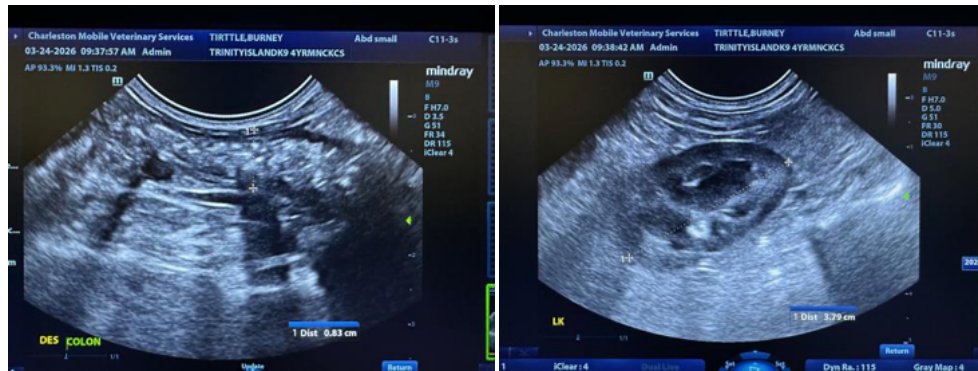
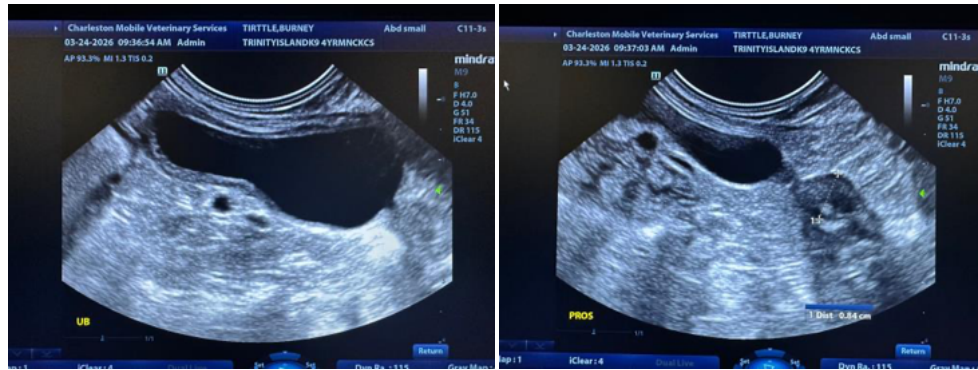
Dr. Oldham

**INVOICE**

13627

**DATE**

3/24/26





**PATIENT**

Burney Tittle

**SPECIES**

Canine

**BREED**

Cavalier King Charles spaniel

**SEX**

Male, neutered

**AGE**

4 Yrs. 7 months

**WEIGHT**

**INTERPRETED BY**

Andrea Nicastro, DVM,  
 Diplomate ACVIM  
 (Small Animal Internal  
 Medicine)

**IMAGING PERFORMED BY**

Andrea Nicastro, DVM,  
 Diplomate ACVIM  
 (Small Animal Internal  
 Medicine)

**HOSPITAL NAME**

Trinity Island

**REFERRING VET**

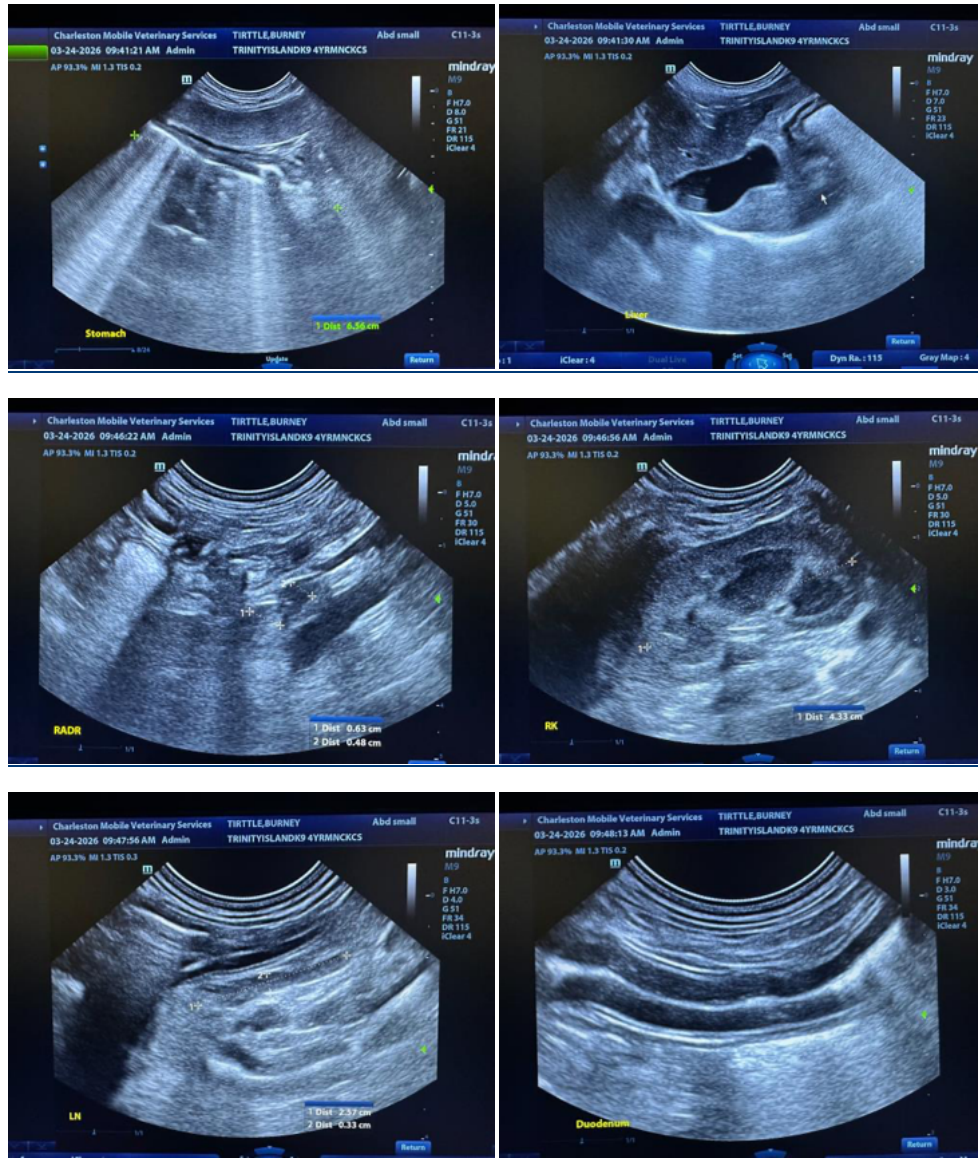
Dr. Oldham

**INVOICE**

13627

**DATE**

3/24/26



The information and recommendations provided are based on the images presented by the referring veterinarian/sonographer. No evaluation can be communicated regarding pathology that was not visible in the image/video clips provided.

Thank you for this referral. If the clinical or image interpretation does not parallel your findings or if I can be of any further assistance please contact me.

Andrea Nicastro, MPH, DVM, Diplomate DACVIM (Small Animal Internal Medicine)  
[info@SonoPath.com](mailto:info@SonoPath.com)