



**PATIENT PRESENTING CLINICAL SIGNS**

Harley Cann Recent history of hematuria and concern for possible nephroliths on abdominal radiographs.

**SPECIES**

Canine

**ULTRASONOGRAPHIC EXAMINATION OF THE ABDOMEN**

*Urinary System*

**BREED**

Labrador

The urinary bladder wall is normal in thickness and the mucosal surface is smooth. The bladder is moderately distended. Luminal contents are anechoic. No cystic calculi are observed. The region of the trigone and the proximal urethra, visible to a depth of 4-5 cm, are normal.

**SEX**

Female, spayed

The left kidney is normal size (6.49 cm in length); normal shape and architecture with smooth peripheral margins. There is a normal 1:3 cortex to medulla ratio with normal corticomedullary distinction. A few small foci of mineralization are observed. There is no evidence of pyelectasia infarcts or hydroureter. Renal vasculature is normal.

**AGE**

4 Yrs.

The right kidney is normal size (6.76 cm in length); normal shape and architecture with smooth peripheral margins. There is a normal 1:3 cortex to medulla ratio with normal corticomedullary distinction. There is no evidence of pyelectasia, nephroliths, infarcts or hydroureter. Renal vasculature is normal.

**WEIGHT**

76 lbs.

*Adrenal Glands*

The left adrenal gland is normal size (0.64 cm at cranial pole) (0.61 cm at caudal pole); normal shape; homogenous parenchyma. The glandular echogenicity and detail are unremarkable. Capsule, cortex, and medullary definition are normal. The phrenicoabdominal vein and surrounding vasculature are normal.

**INTERPRETED BY**

Andrea Nicastro, DVM,  
Diplomate ACVIM  
(Small Animal Internal  
Medicine)

The right adrenal gland is normal size (0.98 cm at cranial pole) (0.54 cm at caudal pole); normal shape; homogenous parenchyma. The glandular echogenicity and detail are unremarkable. Capsule, cortex, and medullary definition are normal. The phrenicoabdominal vein and surrounding vasculature are normal.

**IMAGING PERFORMED BY**

Andrea Nicastro, DVM,  
Diplomate ACVIM  
(Small Animal Internal  
Medicine)

*Spleen*

The spleen is normal in size (1.53 cm in width at the level of the hilus) with a normal capsular contour. There is appropriate echogenicity and echotexture. No focal lesions are observed. Splenic vasculature is normal.

**HOSPITAL NAME**

Long Point AH

*Liver*

The liver is subjectively normal in size with normal contours and structure. There is appropriate echogenicity and echotexture. No overt structural evidence of inflammatory, infiltrative or regenerative pathology is evident. Vascular and biliary tracts are of normal volume with no evidence of congestion. No pathological hepatic lymphadenopathy observed. The portal vein to caudal vena cava ratio is approximately 1:1. The gall bladder lumen is moderately distended. The wall is thin and smooth. Luminal contents are anechoic. The cystic and common bile ducts are normal/not seen.

**REFERRING VET**

Dr. Erin Burton

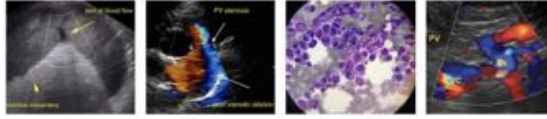
**INVOICE**

14778

*Gastrointestinal*

**DATE**  
3/22/23

The stomach and intestine are free of stasis and exhibit normal peristaltic activity. The gastric lumen is mildly distended with ingesta. The gastric wall and pylorus are normal in thickness with a normal



**PATIENT**

Harley Cann

**SPECIES**

Canine

**BREED**

Labrador

**SEX**

Female, spayed

**AGE**

4 Yrs.

**WEIGHT**

76 lbs.

**INTERPRETED BY**

Andrea Nicastro, DVM,  
Diplomate ACVIM  
(Small Animal Internal  
Medicine)

**IMAGING PERFORMED BY**

Andrea Nicastro, DVM,  
Diplomate ACVIM  
(Small Animal Internal  
Medicine)

**HOSPITAL NAME**

Long Point AH

**REFERRING VET**

Dr. Erin Burton

**INVOICE**

14778

**DATE**

3/22/23

layering pattern. The pyloric outflow tract is patent. The small intestinal lumen is segmentally dilated with chyme (mild). The small intestinal wall thickness is normal with a normal layering pattern and appropriate mural detail. Discreet masses are not identified. The colonic wall is normal. No obstructive disease is noted.

**Pancreas**

The region of the pancreas is isoechoic relative to surrounding omental fat. No obvious parenchymal abnormalities are observed. There is no evidence of regional inflammation or effusion.

**Free Abdomen**

The peritoneal cavity is normal. There is no evidence of inflammation or effusion. A 1.25 cm medial iliac lymph node is visualized. The node is normal in shape and echogenicity.

**Other**

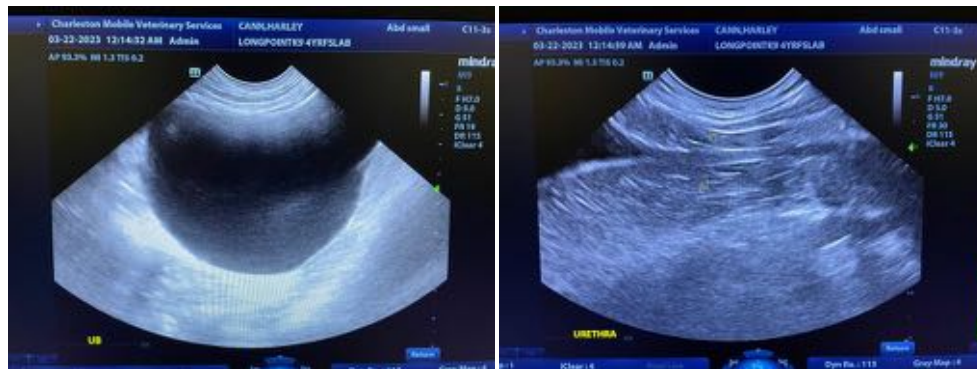
A brief echocardiogram reveals no evidence of pericardial effusion or obvious right atrial/auricular mass.

**ULTRASONOGRAPHIC FINDINGS**

- Minor left non-obstructive nephrolithiasis.
- The prominent medial iliac lymph node is likely reactive.

**INTERPRETATION OF THE FINDINGS & FURTHER RECOMMENDATIONS**

A urinalysis with culture and sensitivity is recommended to further evaluate for urinary tract infection.





**PATIENT**

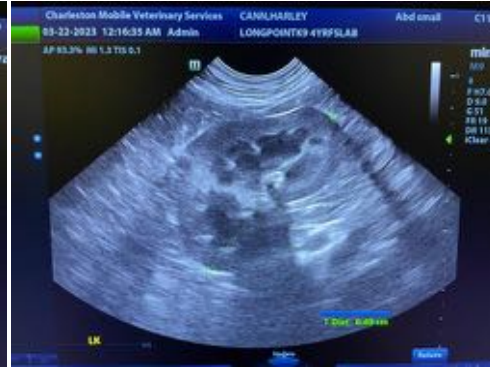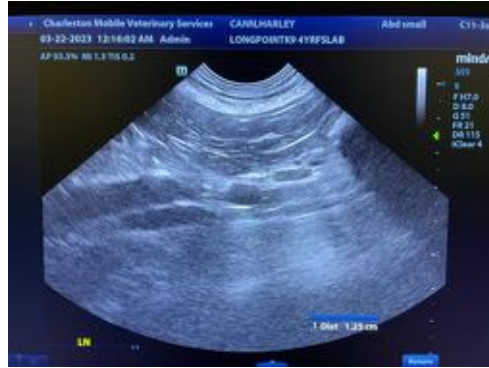Harley Cann

**SPECIES**

Canine

**BREED**

Labrador



**SEX**

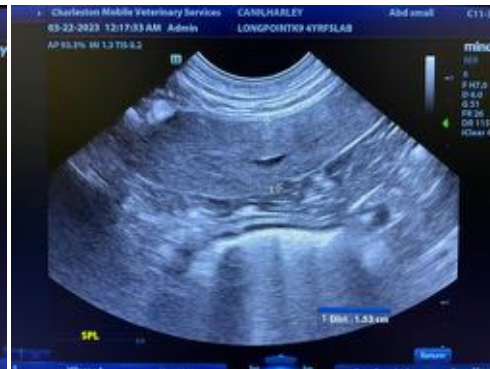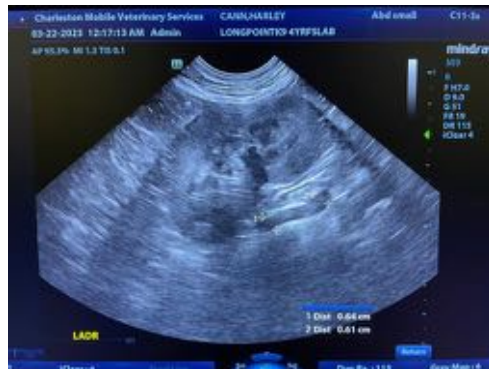Female, spayed

**AGE**

4 Yrs.

**WEIGHT**

76 lbs.

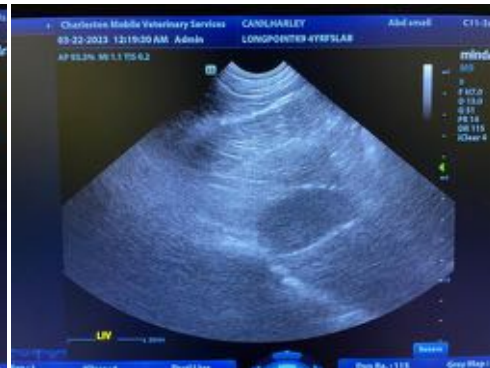
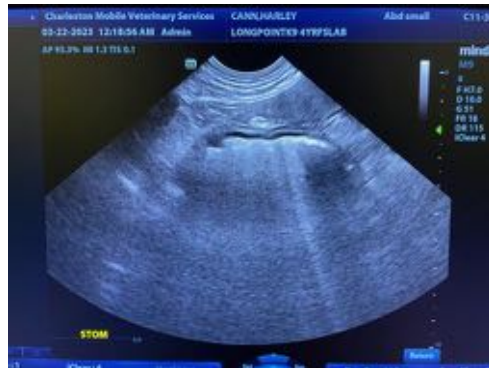

**INTERPRETED BY**

Andrea Nicastro, DVM,  
Diplomate ACVIM  
(Small Animal Internal  
Medicine)

**IMAGING PERFORMED BY**

Andrea Nicastro, DVM,  
Diplomate ACVIM  
(Small Animal Internal  
Medicine)



**HOSPITAL NAME**

Long Point AH

**REFERRING VET**

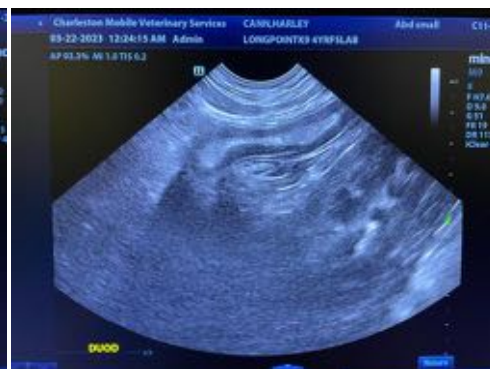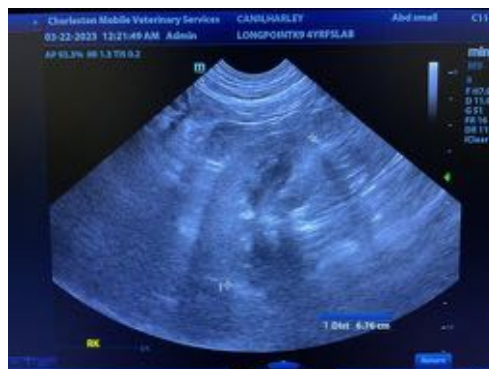Dr. Erin Burton

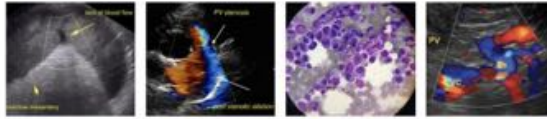
**INVOICE**

14778

**DATE**

3/22/23





**PATIENT**

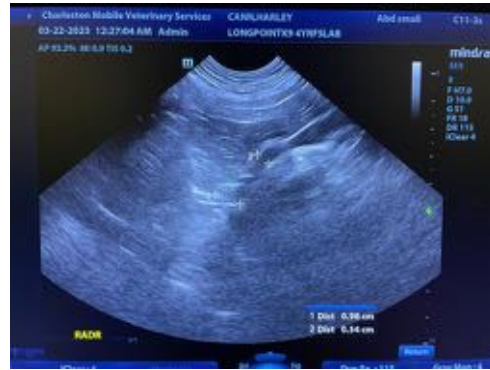Harley Cann

**SPECIES**

Canine

**BREED**

Labrador



**SEX**

Female, spayed

**AGE**

4 Yrs.

**WEIGHT**

76 lbs.

The information and recommendations provided are based on the images presented by the referring veterinarian/sonographer. No evaluation can be communicated regarding pathology that was not visible in the image/video clips provided.

Thank you for this referral. If the clinical or image interpretation does not parallel your findings or if I can be of any further assistance please contact me.

Andrea Nicastro, MPH, DVM, Diplomate DACVIM (Small Animal Internal Medicine)  
[info@SonoPath.com](mailto:info@SonoPath.com)

**INTERPRETED BY**

Andrea Nicastro, DVM,  
Diplomate ACVIM  
(*Small Animal Internal  
Medicine*)

**IMAGING  
PERFORMED BY**

Andrea Nicastro, DVM,  
Diplomate ACVIM  
(*Small Animal Internal  
Medicine*)

**HOSPITAL NAME**

Long Point AH

**REFERRING VET**

Dr. Erin Burton

**INVOICE**

14778

**DATE**

3/22/23