

**PATIENT**

Maggie Agresti

**SPECIES**

Canine

**BREED**

Bichon Frise

**SEX**

Female, spayed

**AGE**

6/12/19

**WEIGHT**

13.4 lbs.

**INTERPRETED BY**

Andrea Nicastro, DVM,  
 Diplomate ACVIM  
 (Small Animal Internal  
 Medicine)

**IMAGING PERFORMED BY**

Andrea Nicastro, DVM,  
 Diplomate ACVIM  
 (Small Animal Internal  
 Medicine)

**HOSPITAL NAME**

Waterway

**REFERRING VET**

Dr. McCalla

**INVOICE**

13617

**DATE**

3/18/26

**PRESENTING CLINICAL SIGNS**

Concerns: due for Cytopoint, has been doing well though for several months. Pt is asymptomatic. T4 3.7. The patient is not on any medications. TSH normal at 0.11, CBC reveals thrombocytosis. Chem panel phosphorus 2.3. Free T4 upper end of normal at 40.

**ULTRASONOGRAPHIC EXAMINATION OF THE THORACIC CAVITY**

The left thyroid lobe is subjectively normal in size (1.54 x 0.27 cm). A 0.26 x 0.08 cm parathyroid gland is observed approximately mid-lobe. The remaining parenchyma is homogeneous. No masses are seen.

The right thyroid lobe is subjectively normal in size (1.55 x 0.48 cm). The parenchyma is homogeneous. No masses are seen.

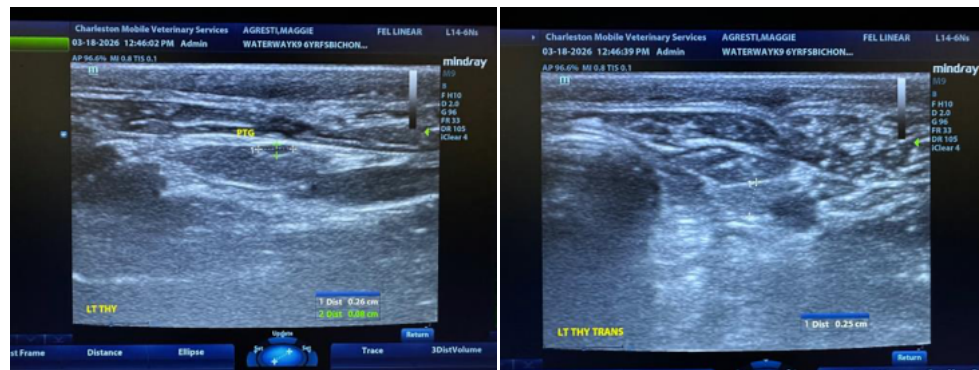The left and right salivary glands are subjectively normal in size (left 2.00 x 0.80 cm; right 2.80 x 0.97 cm). The parenchyma is homogenous in both glands. No obvious pathology is seen. A submandibular lymph node is seen on both the left and right side. They appear relatively symmetrical and homogeneous in appearance.

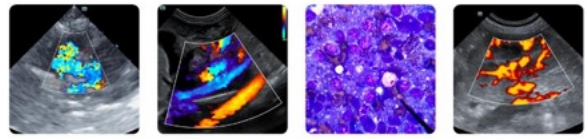
**ULTRASONOGRAPHIC FINDINGS**

Unremarkable cervical region. There is no obvious evidence of a thyroid mass.

**INTERPRETATION OF THE FINDINGS & FURTHER RECOMMENDATIONS**

Consider rechecking a T4/free T4 by equilibrium dialysis in 1-2 months.





**PATIENT**

Maggie Agresti

**SPECIES**

Canine

**BREED**

Bichon Frise

**SEX**

Female, spayed

**AGE**

6/12/19

**WEIGHT**

13.4 lbs.

**INTERPRETED BY**

Andrea Nicastro, DVM,  
 Diplomate ACVIM  
 (Small Animal Internal  
 Medicine)

**IMAGING PERFORMED BY**

Andrea Nicastro, DVM,  
 Diplomate ACVIM  
 (Small Animal Internal  
 Medicine)

**HOSPITAL NAME**

Waterway

**REFERRING VET**

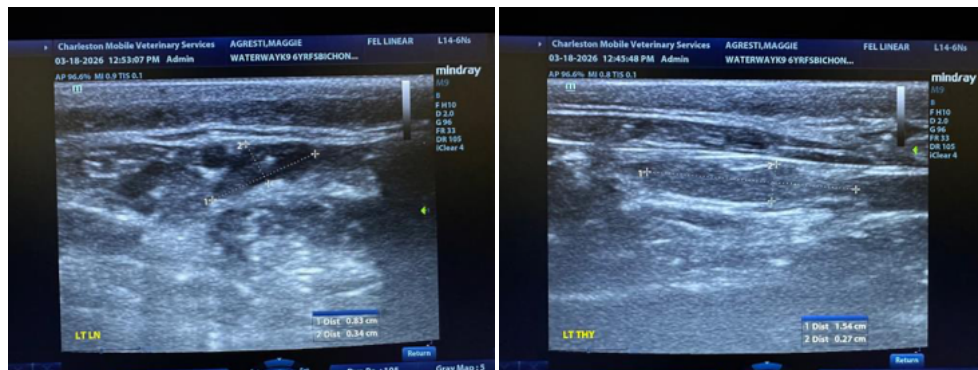
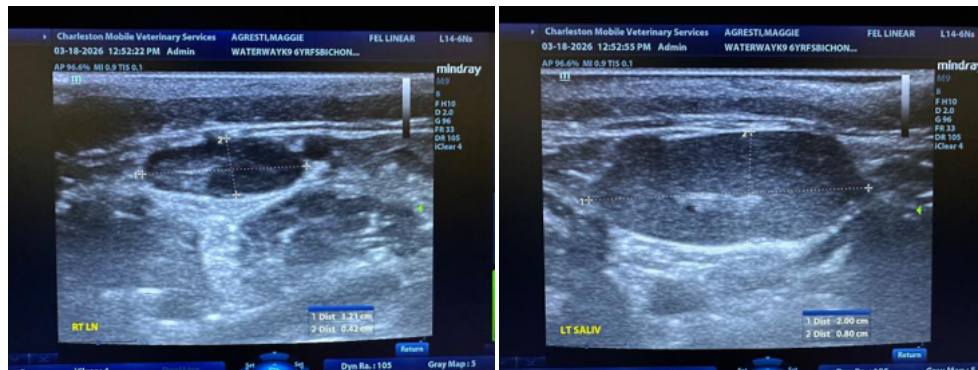
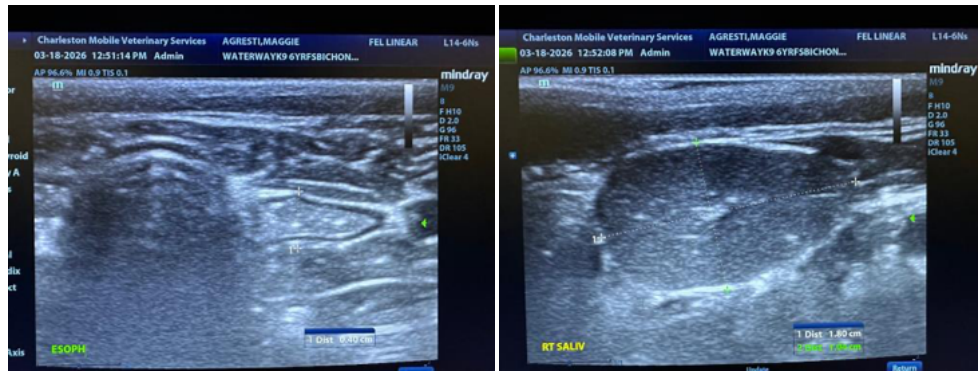
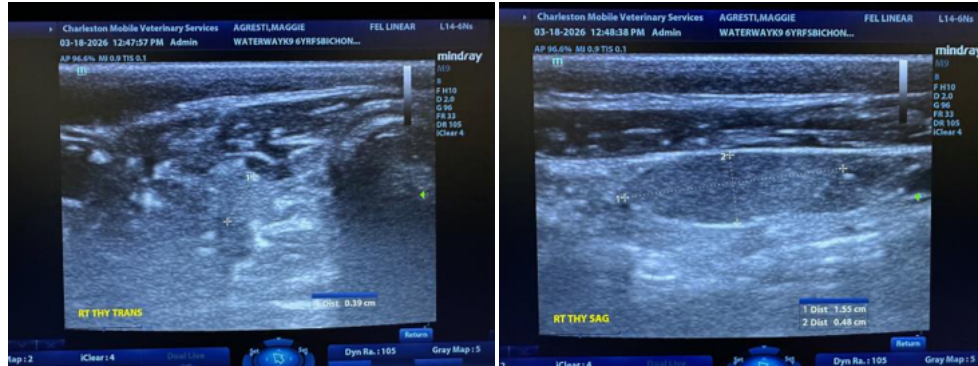
Dr. McCalla

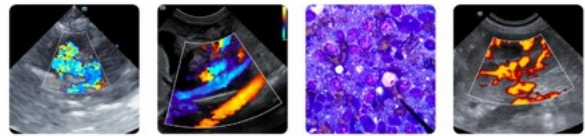
**INVOICE**

13617

**DATE**

3/18/26





**PATIENT**

Maggie Agresti

**SPECIES**

Canine

**BREED**

Bichon Frise

**SEX**

Female, spayed

**AGE**

6/12/19

**WEIGHT**

13.4 lbs.

**INTERPRETED BY**

Andrea Nicastro, DVM,  
Diplomate ACVIM  
*(Small Animal Internal  
Medicine)*

**IMAGING  
PERFORMED BY**

Andrea Nicastro, DVM,  
Diplomate ACVIM  
*(Small Animal Internal  
Medicine)*

**HOSPITAL NAME**

Waterway

**REFERRING VET**

Dr. McCalla

**INVOICE**

13617

**DATE**

3/18/26

The information and recommendations provided are based on the images presented by the referring veterinarian/sonographer. No evaluation can be communicated regarding pathology that was not visible in the image/video clips provided.

Thank you for this referral. If the clinical or image interpretation does not parallel your findings or if I can be of any further assistance please contact me.

Andrea Nicastro, MPH, DVM, Diplomate DACVIM (Small Animal Internal Medicine)  
[info@SonoPath.com](mailto:info@SonoPath.com)