



PATIENT

Max Smith

SPECIES

Canine

BREED

German Shepherd

SEX

Male, intact

AGE

7/10/2017

WEIGHT

87 lbs.

INTERPRETED BY

Andrea Nicastro, DVM,
Diplomate ACVIM
(Small Animal Internal
Medicine)

**IMAGING
PERFORMED BY**

Andrea Nicastro, DVM,
Diplomate ACVIM
(Small Animal Internal
Medicine)

HOSPITAL NAME

Flowertown AH

REFERRING VET

Dr. Guffey

INVOICE

14753

DATE

3/15/23

PRESENTING CLINICAL SIGNS

Owner noticed p drinking from muddy water puddle last week, o filled hole Saturday. There is a large chunk of Jolly ball missing since last week, o has not found chunk, assuming p may have ingested it. P has had change in breathing, diarrhea and inappetence since last week. P will not eat his reg diet, but is eating chicken and rice. No v/c.

Thoracic radiographs reveal a severe globoid shaped heart, mild hepatomegaly, retroperitoneal mass effect, peritoneal effusion, changes consistent with impending colitis, mild diffuse bronchial pulmonary pattern.

ULTRASONOGRAPHIC EXAMINATION OF THE ABDOMEN

Urinary System

The urinary bladder wall is normal in thickness and the mucosal surface is smooth. The bladder lumen is moderately distended. A small amount of suspended echogenic debris is observed within the lumen. No masses, inflammatory changes or calculi are observed. Ureteral papillae and visualized portion of the proximal urethra, visible to a depth of 2 cm, are normal.

The prostate is enlarged (4.46 in width) with smooth curvilinear peripheral contours. The parenchyma is hyperechoic relative to surrounding omental fat and slightly heterogeneous in appearance. No distinct focal lesions are observed. The prostatic urethra is not overtly dilated.

The left kidney is normal size (8.61 cm in length); normal shape and architecture with smooth peripheral margins. There is a normal 1:3 cortex to medulla ratio with normal corticomedullary distinction. There is no evidence of pyelectasia, nephroliths, infarcts or hydronephrosis. Renal vasculature is normal.

The right kidney is normal size (8.52 cm in length); normal shape and architecture with smooth peripheral margins. There is a normal 1:3 cortex to medulla ratio with normal corticomedullary distinction. There is no evidence of pyelectasia, nephroliths, infarcts or hydronephrosis. Renal vasculature is normal.

Adrenal Glands

The left adrenal gland is normal size (0.60 cm at cranial pole) (0.66 cm at caudal pole); normal shape; homogenous parenchyma. The glandular echogenicity and detail are unremarkable. Capsule, cortex, and medullary definition are normal. The phrenicoabdominal vein and surrounding vasculature are normal.

The right adrenal gland is normal size (1.14 cm at cranial pole) (0.59 cm at caudal pole) (xxx cm in length); normal shape; homogenous parenchyma. The glandular echogenicity and detail are unremarkable. Capsule, cortex, and medullary definition are normal. The phrenicoabdominal vein and surrounding vasculature are normal.

Spleen

The spleen is prominent in size with slightly swollen peripheral contours. The parenchyma is subtly mottled in appearance. No distinct focal lesions are observed. Splenic vasculature appears normal with no evidence of thrombosis.

Liver



PATIENT

Max Smith

SPECIES

Canine

BREED

German Shepherd

SEX

Male, intact

AGE

7/10/2017

WEIGHT

87 lbs.

INTERPRETED BY

Andrea Nicastro, DVM,
Diplomate ACVIM
(Small Animal Internal
Medicine)

**IMAGING
PERFORMED BY**

Andrea Nicastro, DVM,
Diplomate ACVIM
(Small Animal Internal
Medicine)

HOSPITAL NAME

Flowertown AH

REFERRING VET

Dr. Guffey

INVOICE

14753

DATE

3/15/23

The liver is subjectively prominent in size with slightly swollen peripheral contours. The parenchyma is hypoechoic relative to the spleen and homogeneous in appearance. No distinct focal lesions are observed. Intrahepatic biliary tracts are normal. Hepatic veins appear mildly dilated. The gall bladder lumen is moderately distended. The wall is thin and smooth. Luminal contents are anechoic. The cystic and common bile ducts are normal/not seen.

Gastrointestinal

The stomach and intestine are free of stasis and exhibit normal peristaltic activity. The gastric lumen is not distended. The gastric wall and pylorus are normal in thickness with a normal layering pattern. The pyloric outflow tract is patent. The small intestinal lumen is not dilated. The small intestinal wall thickness is normal with a normal layering pattern and appropriate mural detail. Discreet masses are not identified. The colonic wall is normal. The colonic lumen contains granular appearing fecal material. No obstructive disease is noted.

Pancreas

The region of the pancreas is isoechoic relative to surrounding omental fat. No obvious parenchymal abnormalities are observed. There is no evidence of regional inflammation or effusion.

Free Abdomen

A large amount of mildly echogenic free fluid is observed. The abdominal lymph nodes are normal/not visible.

Other

The testicles are subjectively normal in size (left 3.92 x 2.45 cm; right 3.50 x 2.83 cm), symmetrical and homogenous. No obvious pathology is seen.

The abdominal caudal vena cava is subjectively dilated.

A brief visualization of the heart reveals severe pericardial effusion with suspected cardiac tamponade.

ULTRASONOGRAPHIC FINDINGS

Primary Findings:

- Severe pericardial effusion with suspected cardiac tamponade. Given the patient's clinical history of dilated cardiomyopathy, right sided congestive heart failure is suspected. However, a right atrial/auricular mass or other causes of pericardial effusion cannot be excluded.
- The ascites is suspected to be secondary to right sided congestive heart failure.
- The mild hepatomegaly is likely due to congestion secondary to right sided congestive heart failure with a lower possibility of other benign hepatopathies (i.e., vacuolar, other). Correlation with the patient's liver values is recommended.
- The splenic parenchymal changes could be consistent with extramedullary hematopoiesis, lymphoid hyperplasia, antigenic stimulation, splenitis, passive congestion or less likely, infiltrative neoplasia.



PATIENT

Max Smith

SPECIES

Canine

BREED

German Shepherd

SEX

Male, intact

AGE

7/10/2017

WEIGHT

87 lbs.

INTERPRETED BY

Andrea Nicastro, DVM,
Diplomate ACVIM
(Small Animal Internal
Medicine)

IMAGING PERFORMED BY

Andrea Nicastro, DVM,
Diplomate ACVIM
(Small Animal Internal
Medicine)

HOSPITAL NAME

Flowertown AH

REFERRING VET

Dr. Guffey

INVOICE

14753

DATE

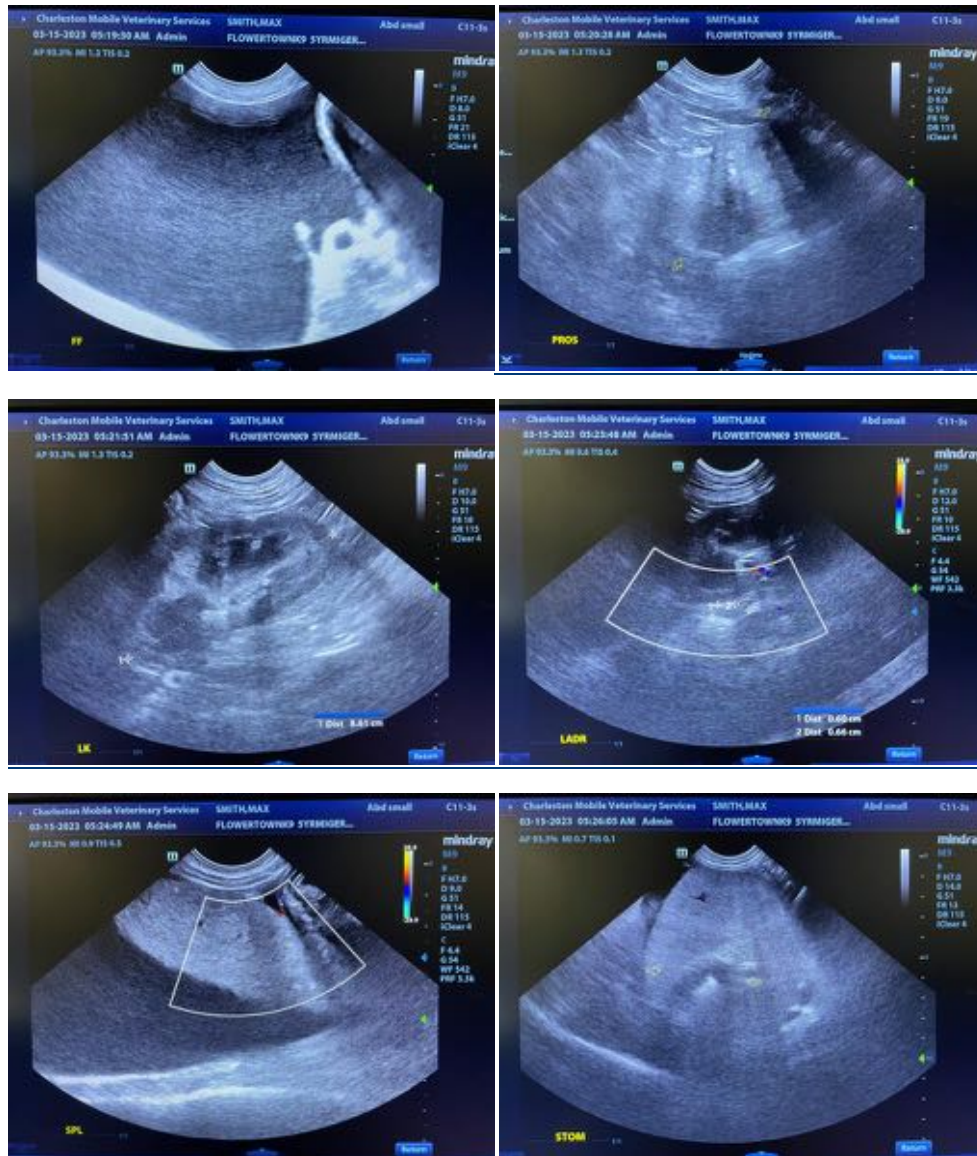
3/15/23

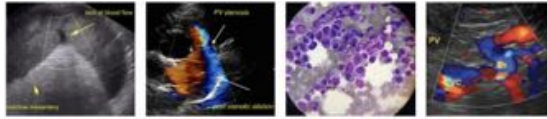
Secondary Findings:

- The prostate changes are most consistent with benign prostatic hyperplasia. Bacterial prostatitis is also a differential but considered unlikely in the absence of lower urinary tract signs.

INTERPRETATION OF THE FINDINGS & FURTHER RECOMMENDATIONS

A full echocardiogram with pericardiocentesis, ECG and baseline blood pressure measurement are recommended.





PATIENT

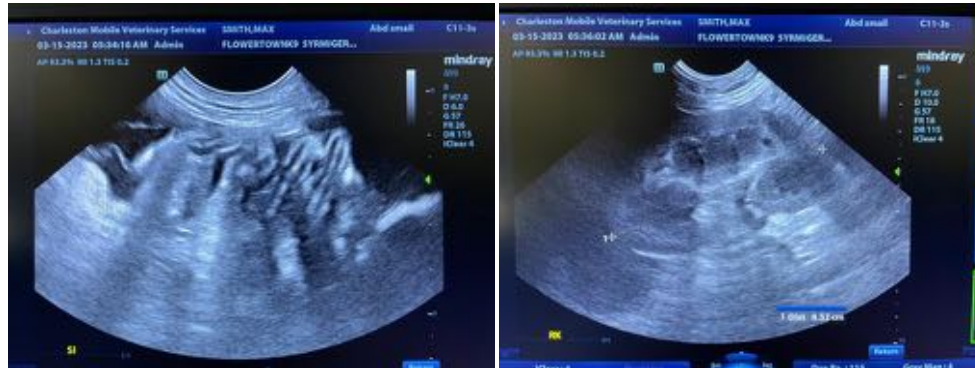
Max Smith

SPECIES

Canine

BREED

German Shepherd



SEX

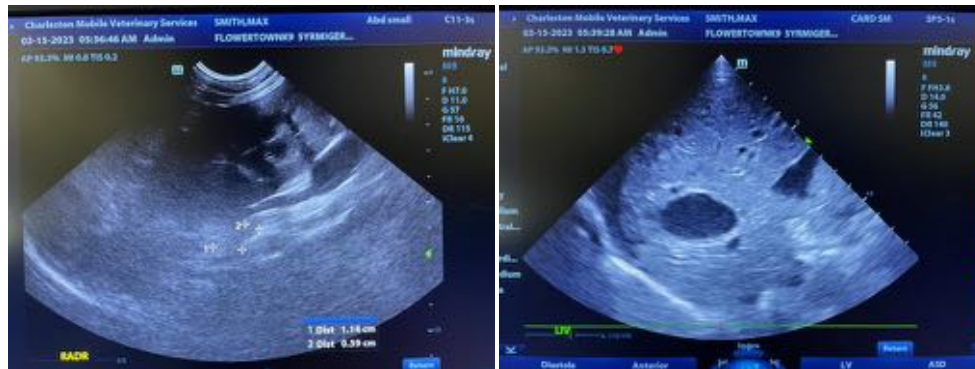
Male, intact

AGE

7/10/2017

WEIGHT

87 lbs.

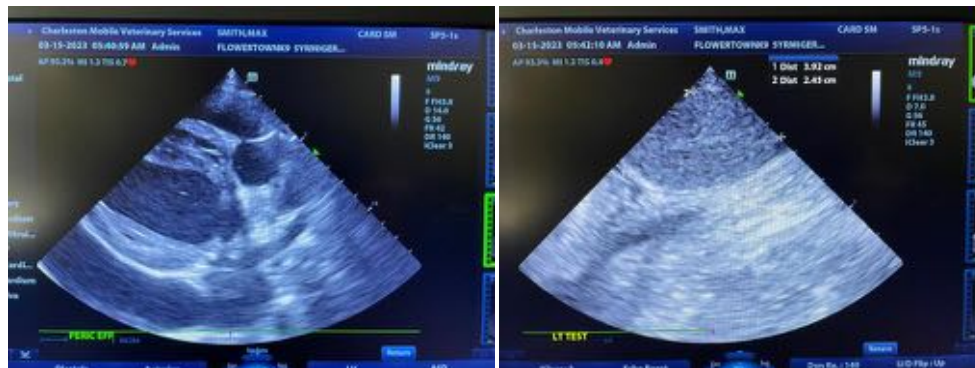


INTERPRETED BY

Andrea Nicastro, DVM,
Diplomate ACVIM
(Small Animal Internal
Medicine)

IMAGING PERFORMED BY

Andrea Nicastro, DVM,
Diplomate ACVIM
(Small Animal Internal
Medicine)



HOSPITAL NAME

Flowertown AH

REFERRING VET

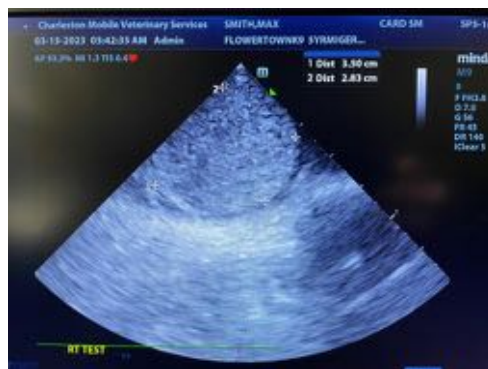
Dr. Guffey

INVOICE

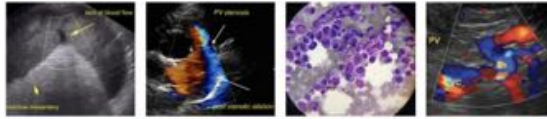
14753

DATE

3/15/23



The information and recommendations provided are based on the images presented by the referring veterinarian/sonographer. No evaluation can be communicated regarding pathology that was not visible



PATIENT in the image/video clips provided.

Max Smith Thank you for this referral. If the clinical or image interpretation does not parallel your findings or if I can be of any further assistance please contact me.

SPECIES

Canine Andrea Nicastro, MPH, DVM, Diplomate DACVIM (Small Animal Internal Medicine)
info@SonoPath.com

BREED

German Shepherd

SEX

Male, intact

AGE

7/10/2017

WEIGHT

87 lbs.

INTERPRETED BY

Andrea Nicastro, DVM,
Diplomate ACVIM
(*Small Animal Internal
Medicine*)

**IMAGING
PERFORMED BY**

Andrea Nicastro, DVM,
Diplomate ACVIM
(*Small Animal Internal
Medicine*)

HOSPITAL NAME

Flowertown AH

REFERRING VET

Dr. Guffey

INVOICE

14753

DATE

3/15/23