

PATIENT

Nala Sandefur

SPECIES

Feline

BREED

Domesitic shorthair

SEX

Female, spayed

AGE

6/22/2012

WEIGHT

9.65 lbs.

INTERPRETED BY

Andrea Nicastro, DVM,
Diplomate ACVIM
(Small Animal Internal
Medicine)

**IMAGING
PERFORMED BY**

Andrea Nicastro, DVM,
Diplomate ACVIM
(Small Animal Internal
Medicine)

HOSPITAL NAME

Southside AH

REFERRING VET

Dr. Carroll

INVOICE

12968

DATE

2/18/22

PRESENTING CLINICAL SIGNS

The patient presented with rapid weight loss. Lab work in December was normal. No vomiting or diarrhea.

ULTRASONOGRAPHIC EXAMINATION OF THE ABDOMEN

Urinary System

The urinary bladder, trigone, and pelvic urethra are normal in thickness and the mucosal surface is smooth. The bladder lumen is moderately distended with anechoic urine. No masses, inflammatory changes or calculi are observed. Ureteral papillae and visualized portion of the proximal urethra, visible to a depth of 2 cm, are normal.

The left kidney is normal size (3.53 cm in length); normal shape and architecture with smooth peripheral margins. There is a normal 1:3 cortex to medulla ratio with minimal loss of corticomedullary distinction. There is no evidence of pyelectasia, nephroliths, infarcts or hydroureter. Renal vasculature is normal.

The right kidney is normal size (3.80 cm in length); normal shape and architecture with smooth peripheral margins. There is a normal 1:3 cortex to medulla ratio with minimal loss of corticomedullary distinction. There is no evidence of pyelectasia, nephroliths, infarcts or hydroureter. Renal vasculature is normal.

Adrenal Glands

The left adrenal gland is normal in size (0.28 cm width). Normal shape and glandular echogenicity. The phrenicoabdominal vein and surrounding vasculature are normal.

The right adrenal gland is normal in size (0.38 cm width). Normal shape and glandular echogenicity. The phrenicoabdominal vein and surrounding vasculature are normal.

Spleen

The spleen is normal in size (0.69 cm in width at the level of the hilus) with a normal capsular contour. There is appropriate echogenicity and echotexture. No focal lesions are observed. Splenic vasculature is normal.

Liver

The liver is subjectively normal in size with normal contours and structure. There is appropriate echogenicity and echotexture. No overt structural evidence of inflammatory, infiltrative or regenerative pathology is evident. Vascular and biliary tracts are of normal volume with no evidence of congestion. No pathological hepatic lymphadenopathy observed. The gallbladder is of normal contours and contains some dependent echogenic debris. The wall is normal in thickness. No choleliths are observed. The cystic and common bile ducts are normal.

Gastrointestinal



PATIENT

Nala Sandefur

SPECIES

Feline

BREED

Domesitic shorthair

SEX

Female, spayed

AGE

6/22/2012

WEIGHT

9.65 lbs.

INTERPRETED BY

Andrea Nicastro, DVM,
Diplomate ACVIM
(Small Animal Internal
Medicine)

**IMAGING
PERFORMED BY**

Andrea Nicastro, DVM,
Diplomate ACVIM
(Small Animal Internal
Medicine)

HOSPITAL NAME

Southside AH

REFERRING VET

Dr. Carroll

INVOICE

12968

DATE

7/8/12

The stomach and intestine are free of stasis and exhibit normal peristaltic activity. The gastric lumen is not distended. The gastric wall and pylorus are normal in thickness with a normal layering pattern. The pyloric outflow tract is patent. The small intestinal lumen is not dilated. The small intestinal wall thickness is normal with a normal layering pattern and appropriate mural detail. There is disruption in the normal 1:3 muscularis: mucosal ratio in most segments. Discreet masses are not identified. The ileocecal colic junction and colonic wall are normal. No obstructive disease is noted.

Pancreas

The region of the pancreas is isoechoic relative to surrounding omental fat. No obvious parenchymal abnormalities are observed. There is no evidence of regional inflammation or effusion.

Free Abdomen

The peritoneal cavity is normal. There is no evidence of inflammation or effusion. The abdominal lymph nodes are normal/not visible.

ULTRASONOGRAPHIC FINDINGS

- Bowel pattern consistent with inflammatory bowel disease with some potential for emerging lymphoma.
- Minor degenerative renal changes.

INTERPRETATION OF THE FINDINGS & FURTHER RECOMMENDATIONS

The following diagnostic/treatment recommendations can be considered:

1. Serum cobalamin, folate, PLI and TLI
2. A fecal evaluation for ova/Giardia
3. A 6-week limited antigen diet trial to assess for food allergies
4. Three-view thoracic radiographs are recommended to assess for occult neoplasia in the chest, if not already performed.
5. A thorough neurologic examination is recommended as weight loss can be the sole clinical sign for primary brain tumors.
6. If the above diagnostics/therapeutics are inconclusive, endoscopic or surgical gastrointestinal biopsies may be necessary to get a definitive diagnosis.



PATIENT

Nala Sandefur

SPECIES

Feline

BREED

Domesitc shorthair

SEX

Female, spayed

AGE

6/22/2012

WEIGHT

9.65 lbs.

INTERPRETED BY

Andrea Nicastro, DVM,
Diplomate ACVIM
(Small Animal Internal
Medicine)

IMAGING PERFORMED BY

Andrea Nicastro, DVM,
Diplomate ACVIM
(Small Animal Internal
Medicine)

HOSPITAL NAME

Southside AH

REFERRING VET

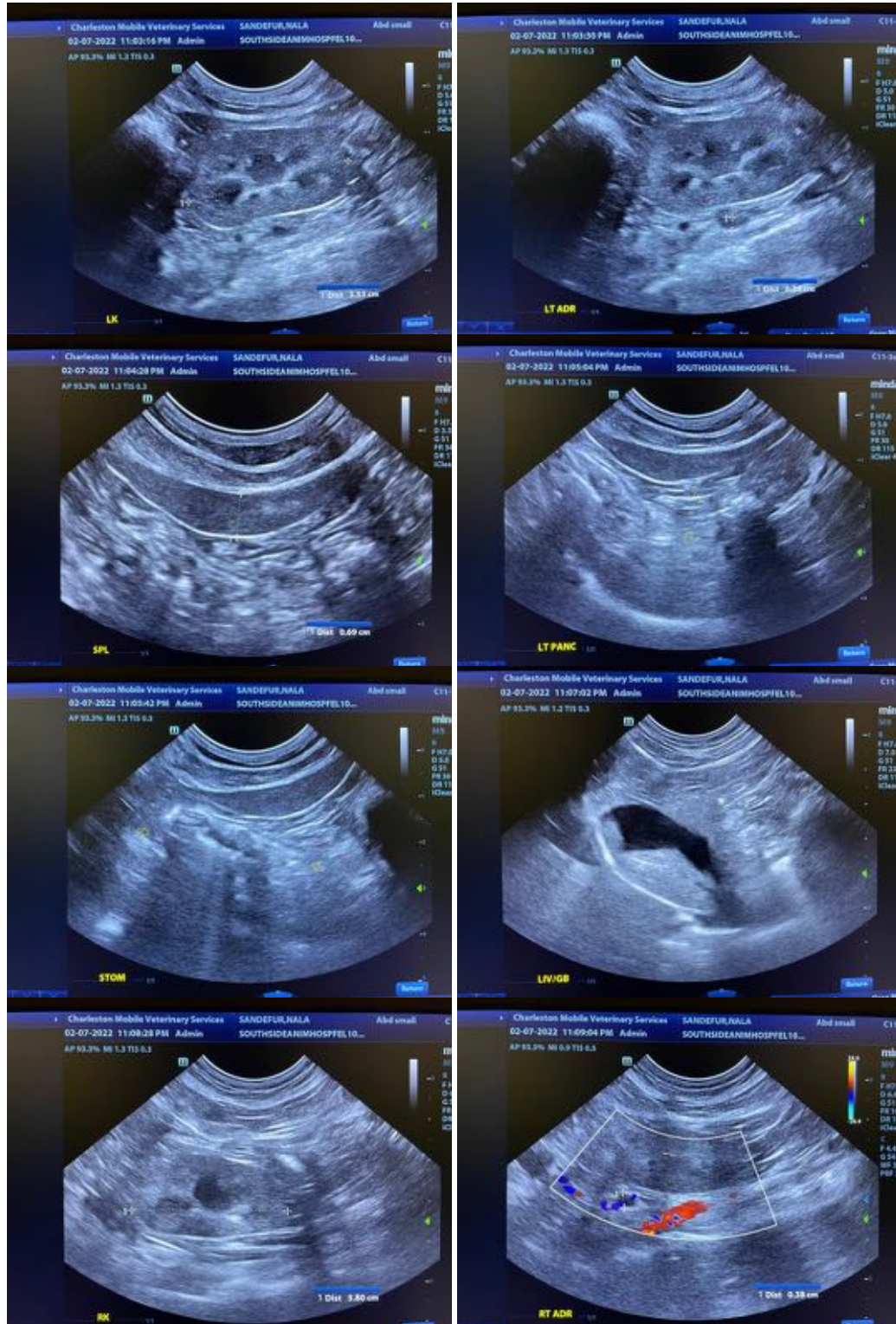
Dr. Carroll

INVOICE

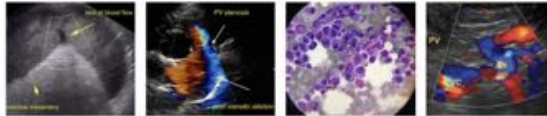
12968

DATE

2/18/22



The information and recommendations provided are based on the images presented by the referring veterinarian/sonographer. No evaluation can be communicated regarding pathology that was not visible in the image/video clips provided.



PATIENT

Nala Sandefur

Thank you for this referral. If the clinical or image interpretation does not parallel your findings or if I can be of any further assistance please contact me.

SPECIES

Feline

Andrea Nicastro, DVM, Diplomate ACVIM (*Small Animal Internal Medicine*)

Andrea.Nicastro@CharlestonMobile.net

BREED

Domesitc shorthair

SEX

Female, spayed

AGE

6/22/2012

WEIGHT

9.65 lbs.

INTERPRETED BY

Andrea Nicastro, DVM,
Diplomate ACVIM
(*Small Animal Internal
Medicine*)

**IMAGING
PERFORMED BY**

Andrea Nicastro, DVM,
Diplomate ACVIM
(*Small Animal Internal*)

HOSPITAL NAME

Southside AH

REFERRING VET

Dr. Carroll

INVOICE

12968

DATE

7/8/22