

PATIENT

Lucy Odom

SPECIES

Canine

BREED

Mixed breed

SEX

Female, spayed

AGE

11 Yrs.

WEIGHT

45 lbs.

INTERPRETED BY

Andrea Nicastro, DVM,
 Diplomate ACVIM
 (Small Animal Internal
 Medicine)

IMAGING PERFORMED BY

Andrea Nicastro, DVM,
 Diplomate ACVIM
 (Small Animal Internal
 Medicine)

HOSPITAL NAME

Veterinary Dental Care

REFERRING VET

Dr. Shannon

INVOICE

13445

DATE

2/3/26

PRESENTING CLINICAL SIGNS

Lucy presents for an abdominal ultrasound for a suspected splenic mass. She was lethargic, but that has resolved.

ULTRASONOGRAPHIC EXAMINATION OF THE ABDOMEN

Urinary System

The urinary bladder is mildly to moderately distended with mostly anechoic urine. The wall in the region of the apex is mildly thickened (up to 0.51 cm) with a slightly irregular mucosal surface. The wall tapers to a normal thickness as it extends toward the cystourethral junction. No cystic calculi are observed. The region of the trigone and the proximal urethra, visible to a depth of 2 cm, are normal.

The left kidney is normal in size (5.51 cm in length) with a normal shape, architecture and smooth peripheral margins. There is a normal 1:3 cortex to medulla ratio with minimal to mild loss of corticomedullary distinction. There is no evidence of pyelectasia, nephroliths, infarcts or hydronephrosis. Renal vasculature is normal.

The right kidney is normal in size (5.08 cm in length) with a normal shape, architecture and smooth peripheral margins. There is a normal 1:3 cortex to medulla ratio with minimal to mild loss of corticomedullary distinction. There is no evidence of pyelectasia, nephroliths, infarcts or hydronephrosis. Renal vasculature is normal.

Adrenal Glands

The left adrenal gland is normal in size (0.58 cm at cranial pole) (0.62 cm at caudal pole) with a normal shape and homogenous parenchyma. The glandular echogenicity and detail are unremarkable. Capsule, cortex, and medullary definition are normal. The phrenicoabdominal vein and surrounding vasculature are normal.

The right adrenal gland is normal in size (1.41 cm at cranial pole) (0.60 cm at caudal pole) with a normal shape and homogenous parenchyma. The glandular echogenicity and detail are unremarkable. Capsule, cortex, and medullary definition are normal. The phrenicoabdominal vein and surrounding vasculature are normal.

Spleen

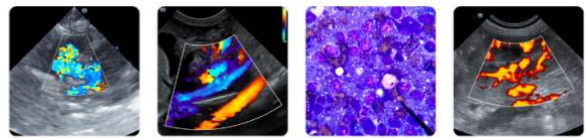
A 7.6 cm heterogeneous cavitated mass is arising from the cranial pole. The mesentery surrounding the mass is mildly hyperechoic. In the remainder of the spleen, the margins are curvilinear and the parenchyma is relatively homogeneous. Splenic vasculature is normal with no evidence of thrombosis.

Liver

The liver is subjectively normal in size with normal peripheral contours. The parenchyma is hypoechoic relative to the spleen and subtly mottled in appearance. 2-3 ill-defined hypoechoic nodules are observed throughout the organ, one of the nodules measuring 1.02 cm in its longest dimension. Vascular and biliary tracts are of normal volume with no evidence of congestion. The portal vein to caudal vena cava ratio is approximately 1:1.

The gall bladder lumen is moderately distended. The wall is thin and smooth. A small amount of mobile echogenic debris is observed within the lumen. The cystic and common bile ducts are normal/not seen.

Gastrointestinal



PATIENT

Lucy Odom

SPECIES

Canine

BREED

Mixed breed

SEX

Female, spayed

AGE

11 Yrs.

WEIGHT

45 lbs.

INTERPRETED BY

Andrea Nicastro, DVM,
Diplomate ACVIM
(Small Animal Internal
Medicine)

**IMAGING
PERFORMED BY**

Andrea Nicastro, DVM,
Diplomate ACVIM
(Small Animal Internal
Medicine)

HOSPITAL NAME

Veterinary Dental Care

REFERRING VET

Dr. Shannon

INVOICE

13445

DATE

2/3/26

The gastric lumen is not distended. The gastric wall and pylorus are normal in thickness with a normal layering pattern. The pyloric outflow tract is patent. The small intestinal lumen is not dilated. The small intestinal wall is normal in thickness with a normal layering pattern and appropriate mural detail. Discreet masses are not identified. The ileoceocolic junction and colonic wall are normal. There is no evidence of an obstructive pattern.

Pancreas

The region of the pancreas is isoechoic relative to surrounding omental fat. No obvious parenchymal abnormalities are observed. There is no evidence of regional inflammation or effusion.

Lymph nodes

The abdominal lymph nodes are normal/not visible.

Free Abdomen

There is no obvious evidence of free fluid.

Other

A brief echocardiogram reveals no evidence of pericardial effusion or obvious right atrial/auricular mass.

ULTRASONOGRAPHIC FINDINGS

Primary Findings:

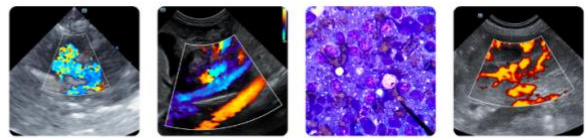
- Large cavitated splenic mass. Neoplasia (i.e., hemangiosarcoma, hemangioma) is suspected with a low possibility of a non-neoplastic process. Mild adjacent peritonitis is present.
- The small hypoechoic hepatic nodules trend toward the benign (i.e., regenerative nodules). However, metastatic disease cannot be completely excluded.

Secondary Findings:

- Minor bilateral age-related renal changes
- The urinary bladder wall changes in the region of the apex could be consistent with cystitis or may be artifactual due to lack of full repletion. Correlation with the patient's clinical history and urinalysis findings is recommended.

INTERPRETATION OF THE FINDINGS & FURTHER RECOMMENDATIONS

1. Three-view thoracic radiographs are recommended to assess for pulmonary metastases.
2. If there is no evidence of pulmonary metastatic disease and an aggressive approach is desired, consider a splenectomy with submission of the spleen for histopathology. Liver biopsies should also be obtained at the time of surgery with particular attention to any visible nodules.
3. Yunnan Baiyao is also recommended as palliative care.



PATIENT

Lucy Odom

SPECIES

Canine

BREED

Mixed breed

SEX

Female, spayed

AGE

11 Yrs.

WEIGHT

45 lbs.

INTERPRETED BY

Andrea Nicastro, DVM,
 Diplomate ACVIM
 (Small Animal Internal
 Medicine)

IMAGING PERFORMED BY

Andrea Nicastro, DVM,
 Diplomate ACVIM
 (Small Animal Internal
 Medicine)

HOSPITAL NAME

Veterinary Dental Care

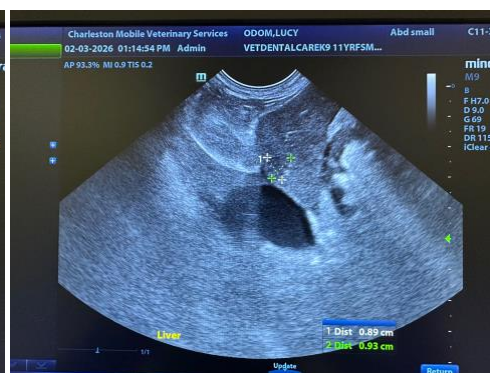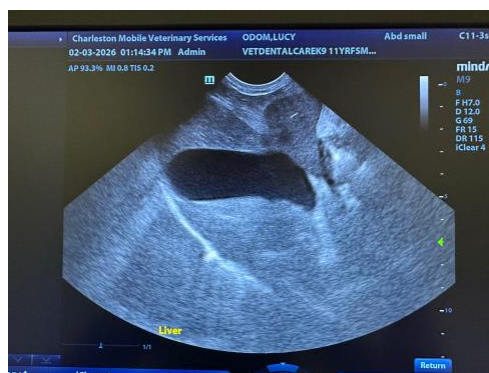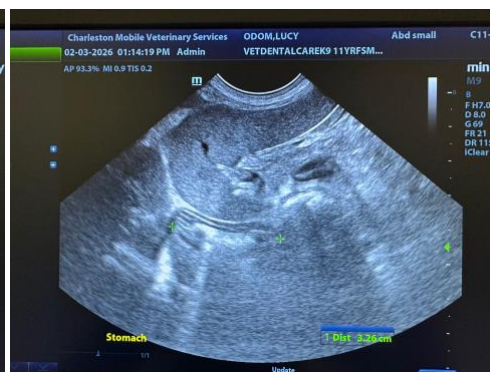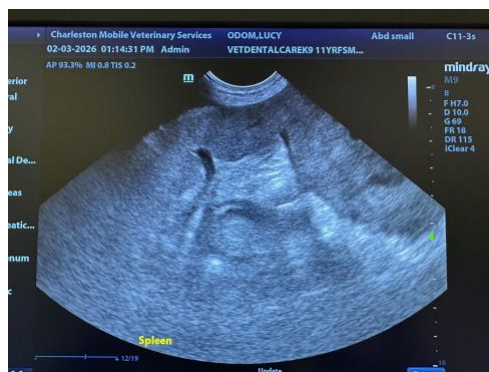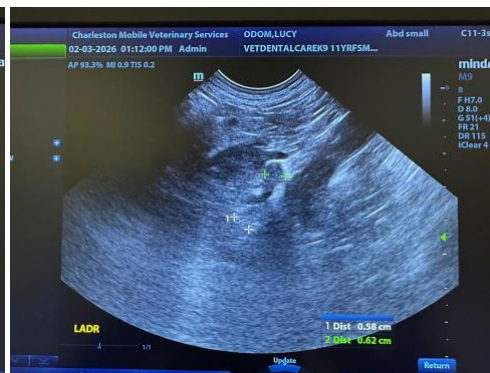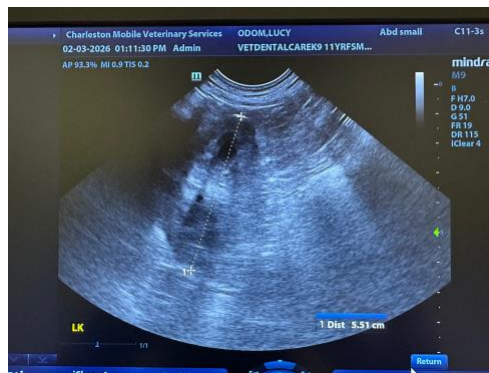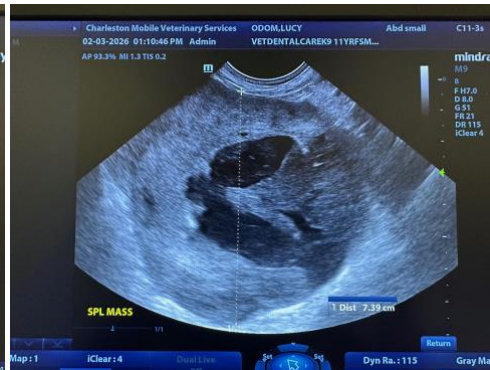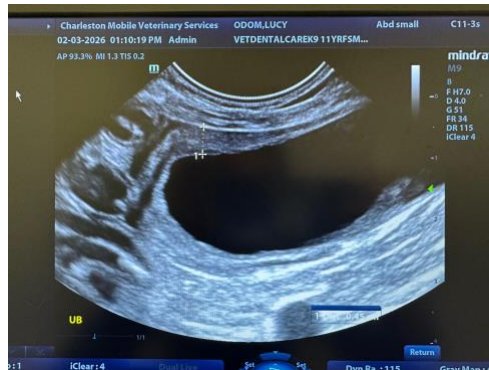REFERRING VET

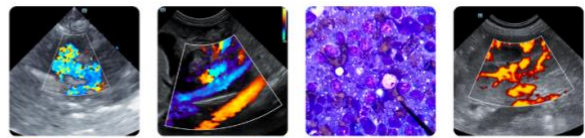
Dr. Shannon

INVOICE

13445

DATE
 2/3/26





PATIENT

Lucy Odom

SPECIES

Canine

BREED

Mixed breed

SEX

Female, spayed

AGE

11 Yrs.

WEIGHT

45 lbs.

INTERPRETED BY

Andrea Nicastro, DVM,
 Diplomate ACVIM
 (Small Animal Internal
 Medicine)

**IMAGING
 PERFORMED BY**

Andrea Nicastro, DVM,
 Diplomate ACVIM
 (Small Animal Internal
 Medicine)

HOSPITAL NAME

Veterinary Dental Care

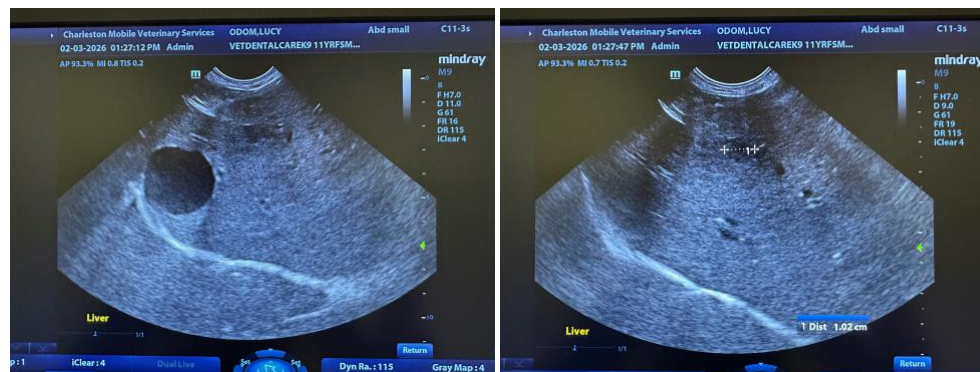
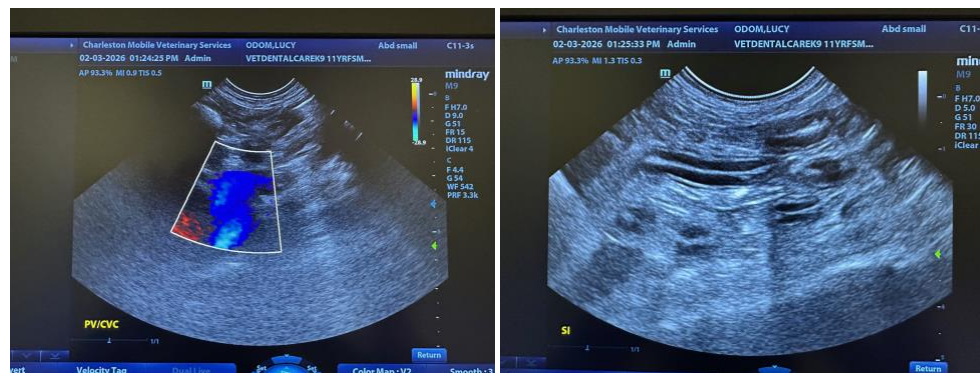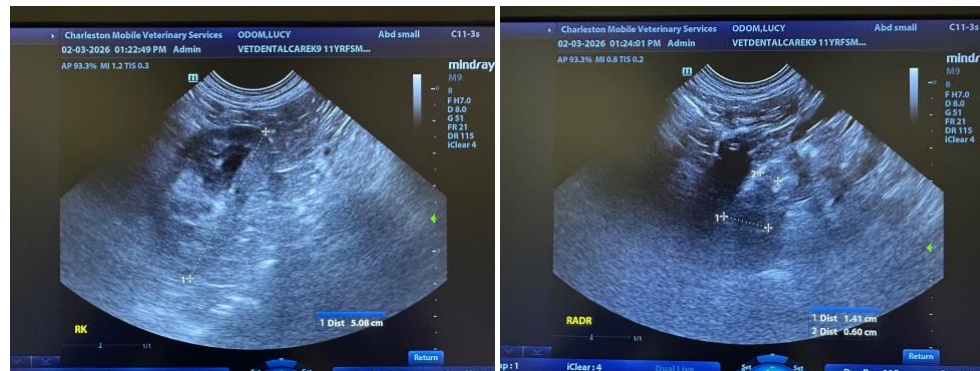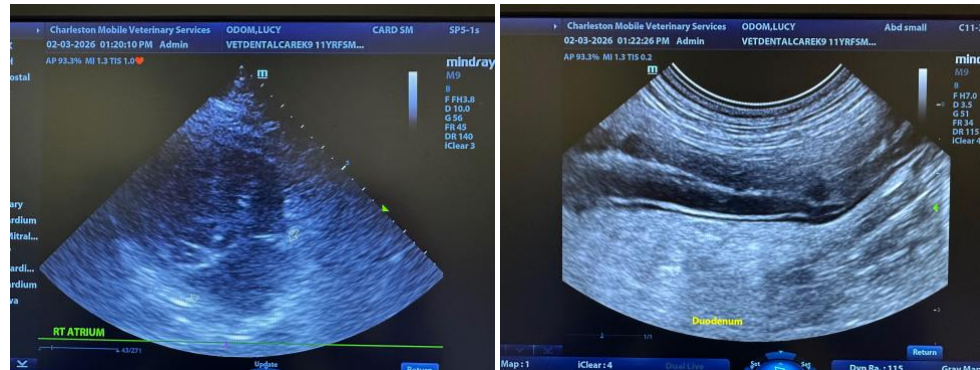
REFERRING VET

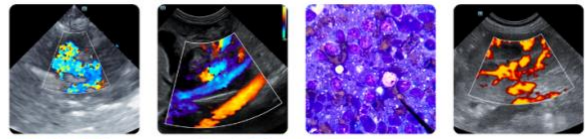
Dr. Shannon

INVOICE

13445

DATE
 2/3/26





PATIENT

Lucy Odom

SPECIES

Canine

BREED

Mixed breed

SEX

Female, spayed

AGE

11 Yrs.

WEIGHT

45 lbs.

INTERPRETED BY

Andrea Nicastro, DVM,
Diplomate ACVIM
(Small Animal Internal
Medicine)

IMAGING PERFORMED BY

Andrea Nicastro, DVM,
Diplomate ACVIM
(Small Animal Internal
Medicine)

HOSPITAL NAME

Veterinary Dental Care

REFERRING VET

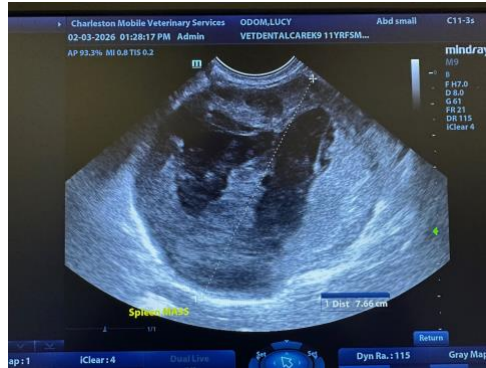Dr. Shannon

INVOICE

13445

DATE

2/3/26



The information and recommendations provided are based on the images presented by the referring veterinarian/sonographer. No evaluation can be communicated regarding pathology that was not visible in the image/video clips provided.

Thank you for this referral. If the clinical or image interpretation does not parallel your findings or if I can be of any further assistance please contact me.

Andrea Nicastro, MPH, DVM, Diplomate DACVIM (Small Animal Internal Medicine)
info@SonoPath.com