



**PATIENT**

Sugar Villano

**SPECIES**

Feline

**BREED**

Domestic shorthair

**SEX**

Male, neutered

**AGE**

2/17/2015

**WEIGHT**

7 kg.

**INTERPRETED BY**

Andrea Nicastro, DVM,  
Diplomate ACVIM  
(*Small Animal Internal  
Medicine*)

**IMAGING  
PERFORMED BY**

Andrea Nicastro, DVM,  
Diplomate ACVIM  
(*Small Animal Internal  
Medicine*)

**HOSPITAL NAME**

Blue Pearl Mt Pleasant

**REFERRING VET**

Dr. Starr

**INVOICE**

13486

**DATE**

2/17/26

**PRESENTING CLINICAL SIGNS**

The patient is a new diabetic. The O stated that last Tuesday Sugar went into the primary vet for a wellness visit, the O continued stating that at the visit Sugar was given an antibiotic injection, steroid injection (depomedrol), and vaccines up to date but no diagnostics were performed at the primary during this time. The O stated that Wednesday Sugar was fine but it was on Thursday Sugar started to become lethargic and not acting normal. The O waited until Saturday to bring Sugar to the ER in surfside and stated that Sugar had bloodwork and x-rays completed there and while Sugar was hospitalized Saturday overnight and Sunday overnight. Sugar wasn't showing any interest in food and has had to be syringe fed. While at the ER is when the O found out Sugar is diabetic. No past medical concerns with Sugar has been overall pretty healthy.

**ULTRASONOGRAPHIC EXAMINATION OF THE ABDOMEN**

**Urinary System**

The urinary bladder wall is normal in thickness and the mucosal surface is smooth. The bladder is moderately distended. Luminal contents are mostly anechoic. No cystic calculi are observed. The region of the trigone and the visible portion of the proximal urethra are normal.

The left kidney is enlarged (5.03 cm in length) with smooth peripheral contours. There is a normal 1:3 cortex to medulla ratio with mild loss of corticomedullary distinction. Trace pyelectasia is present (0.19 cm in the transverse plane). There is no evidence of nephroliths, infarcts or hydroureter. Renal vasculature is normal. There is equivocal subcapsular fluid. Surrounding mesentery is hyperechoic.

The right kidney is enlarged (5.05 cm in length) with smooth peripheral contours. There is a normal 1:3 cortex to medulla ratio with mild loss of corticomedullary distinction. Mild pyelectasia is present (0.28 cm in the longitudinal plane). There is no evidence of nephroliths, infarcts or hydroureter. Renal vasculature is normal. Surrounding mesentery is hyperechoic.

**Adrenal Glands**

The left adrenal gland is normal size (0.37 cm width). Normal shape and glandular echogenicity. The phrenicoabdominal vein and surrounding vasculature are normal.

The right adrenal gland is normal size (0.49 cm width). Normal shape and glandular echogenicity. The phrenicoabdominal vein and surrounding vasculature are normal.

**Spleen**

The spleen is normal in size (0.57 cm in width at the level of the hilus) with a normal capsular contour. There is appropriate echogenicity and echotexture. No focal lesions are observed. Splenic vasculature is normal.

**Liver**

The liver is subjectively enlarged with swollen peripheral contours. The parenchyma is hyperechoic relative to the spleen and slightly attenuating. No focal lesions are observed. Vascular and biliary tracts are of normal volume with no evidence of congestion. The portal vein to caudal vena cava ratio is approximately 1:1.

The gall bladder lumen is moderately distended. The wall is thin and smooth. A small amount of suspended echogenic debris is observed within the lumen. The cystic and common bile ducts are normal. The duodenal papilla is normal in size at 0.19 cm in width.

**Gastrointestinal**



**PATIENT**

Sugar Villano

**SPECIES**

Feline

**BREED**

Domestic shorthair

**SEX**

Male, neutered

**AGE**

2/17/2015

**WEIGHT**

7 kg.

**INTERPRETED BY**

Andrea Nicastro, DVM,  
Diplomate ACVIM  
(Small Animal Internal  
Medicine)

**IMAGING  
PERFORMED BY**

Andrea Nicastro, DVM,  
Diplomate ACVIM  
(Small Animal Internal  
Medicine)

**HOSPITAL NAME**

Blue Pearl Mt Pleasant

**REFERRING VET**

Dr. Starr

**INVOICE**

13486

**DATE**

2/17/26

The stomach and intestine are free of stasis and exhibit normal peristaltic activity. The gastric lumen is minimally to mildly fluid distended. The gastric wall and pylorus are normal in thickness with a normal layering pattern. The pyloric outflow tract is patent. The small intestinal lumen is not dilated. The small intestinal wall thickness is normal. There is disruption in the normal 1:3 muscularis: mucosal ratio in most segments. Discreet masses are not identified. The ileocecal colic junction and colonic wall are normal. The colonic lumen contains shadowing fecal material. No obvious obstructive disease is noted.

**Pancreas**

The region of the pancreas is isoechoic relative to surrounding omental fat. No obvious parenchymal abnormalities are observed. There is no evidence of regional inflammation or effusion.

**Lymph nodes**

The abdominal lymph nodes are normal/not visible.

**Free Abdomen**

There is no obvious evidence of free fluid.

**Other**

A brief echocardiogram reveals no obvious evidence of pericardial or pleural effusion in the visible window.

**ULTRASONOGRAPHIC FINDINGS**

**Primary Findings:**

- The diffuse hepatic parenchymal changes could be consistent with hepatic lipidosis, an inflammatory hepatopathy (i.e., bacterial cholangiohepatitis, lymphoplasmacytic hepatitis, feline infectious peritonitis), infiltrative neoplasia (i.e., lymphoma) and/or other hepatopathy.
- Bilateral renomegaly and cranial retroperitonitis. These changes are suggestive of an inflammatory process (i.e., interstitial nephritis, pyelonephritis) with a lower possibility of emerging neoplasia. The bilateral pyelectasia may be secondary to pyelonephritis, parenchymal remodeling, PU/PD (if applicable), fluid therapy (if applicable) or some combination thereof.

**Secondary Findings:**

- The small intestinal wall changes could be consistent with inflammatory bowel disease or may be a normal variant for this older feline patient. Correlation with the patient's clinical history is recommended.

**INTERPRETATION OF THE FINDINGS & FURTHER RECOMMENDATIONS**

1. Regarding the hepatic changes and elevated liver values, consider hepatic tissue sampling (i.e., aspirates or biopsies) assuming normal clotting status. Aerobic and anaerobic bile cultures would also be beneficial. If hepatic tissue sampling is not pursued, empirical treatment for bacterial cholangiohepatitis/hepatic lipidosis is recommended along with supportive care for diabetic ketoacidosis. Nutritional support should also be initiated as needed.
2. Given the renal changes, a urinalysis with a culture and sensitivity are recommended to assess for pyelonephritis.



**PATIENT**

Sugar Villano

**SPECIES**

Feline

**BREED**

Domestic shorthair

**SEX**

Male, neutered

**AGE**

2/17/2015

**WEIGHT**

7 kg.

**INTERPRETED BY**

Andrea Nicastro, DVM,  
 Diplomate ACVIM  
 (Small Animal Internal  
 Medicine)

**IMAGING PERFORMED BY**

Andrea Nicastro, DVM,  
 Diplomate ACVIM  
 (Small Animal Internal  
 Medicine)

**HOSPITAL NAME**

Blue Pearl Mt Pleasant

**REFERRING VET**

Dr. Starr

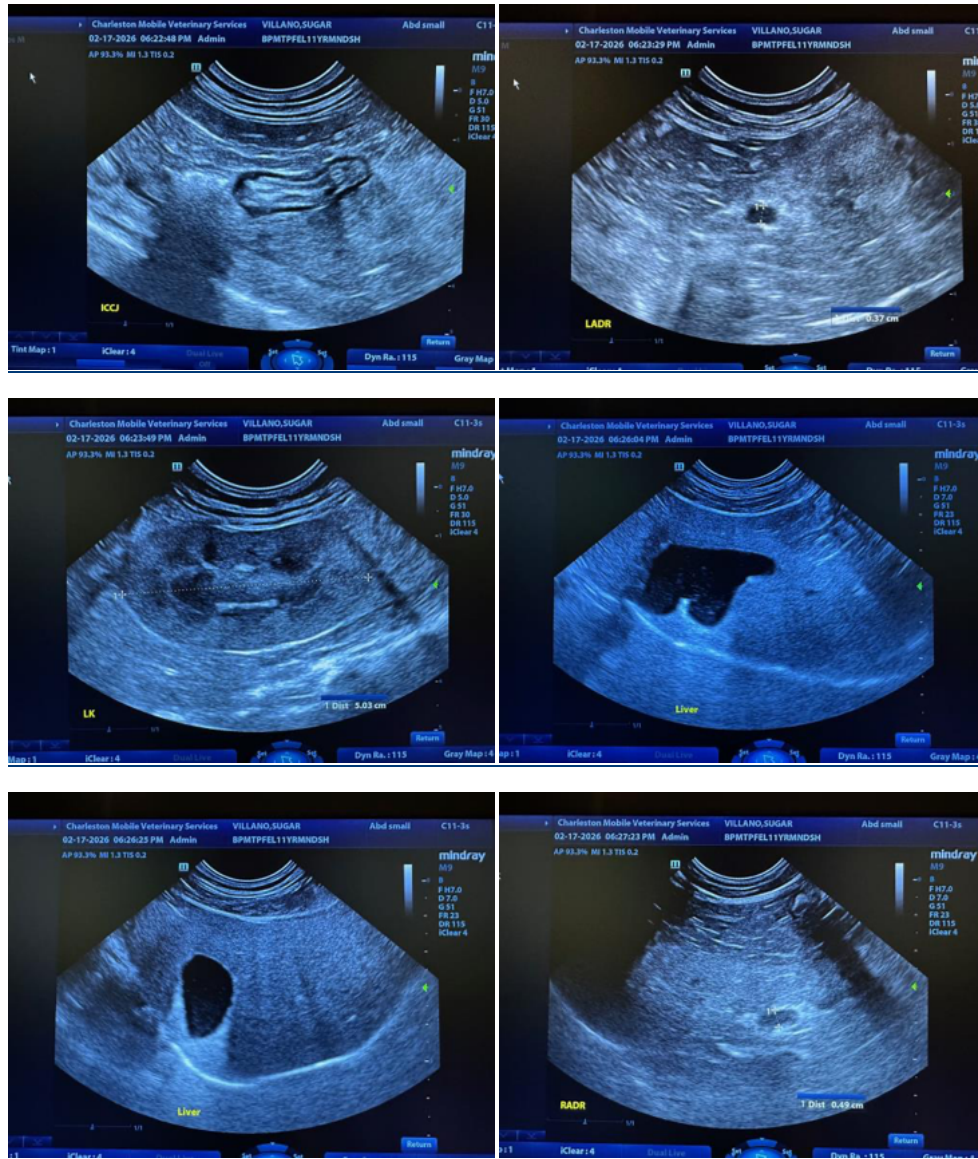
**INVOICE**

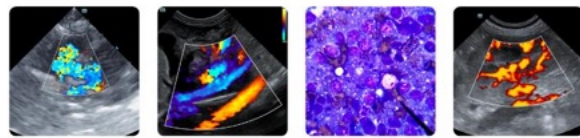
13486

**DATE**

2/17/26

- Given the patient's age, three-view thoracic radiographs are recommended to assess cardiopulmonary status.





**PATIENT**

Sugar Villano

**SPECIES**

Feline

**BREED**

Domestic shorthair

**SEX**

Male, neutered

**AGE**

2/17/2015

**WEIGHT**

7 kg.

**INTERPRETED BY**

Andrea Nicastro, DVM,  
 Diplomate ACVIM  
 (Small Animal Internal  
 Medicine)

**IMAGING  
 PERFORMED BY**

Andrea Nicastro, DVM,  
 Diplomate ACVIM  
 (Small Animal Internal  
 Medicine)

**HOSPITAL NAME**

Blue Pearl Mt Pleasant

**REFERRING VET**

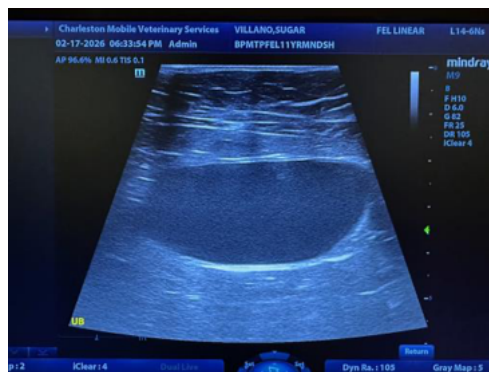
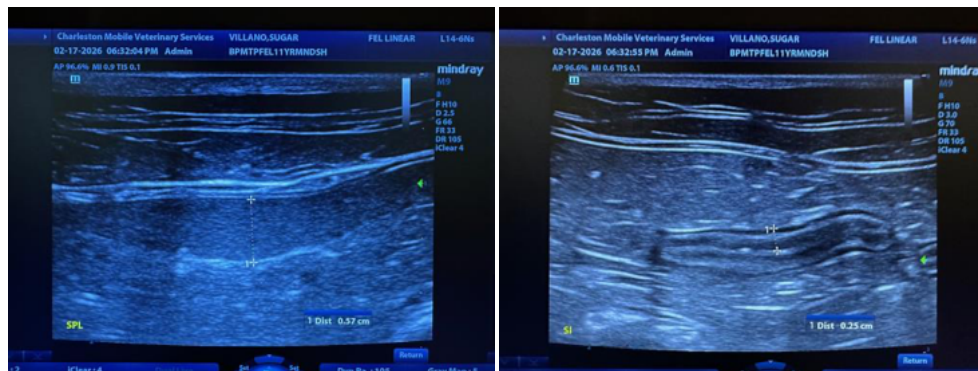
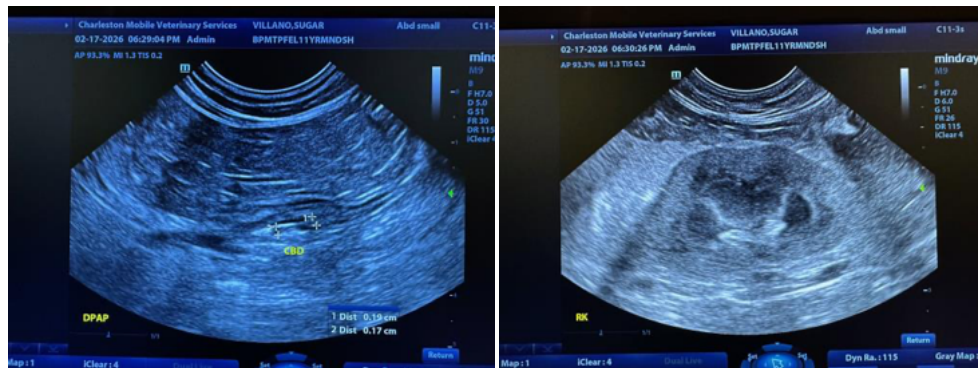
Dr. Starr

**INVOICE**

13486

**DATE**

2/17/26



The information and recommendations provided are based on the images presented by the referring veterinarian/sonographer. No evaluation can be communicated regarding pathology that was not visible in the image/video clips provided.

Thank you for this referral. If the clinical or image interpretation does not parallel your findings or if I can be of any further assistance please contact me.

Andrea Nicastro, MPH, DVM, Diplomate DACVIM (Small Animal Internal Medicine)  
[info@SonoPath.com](mailto:info@SonoPath.com)