



PATIENT **PRESENTING CLINICAL SIGNS**

Spencer Grant Acute on chronic vomiting, hyporexia, and diarrhea/hematochezia.

SPECIES **ULTRASONOGRAPHIC EXAMINATION OF THE ABDOMEN**

Canine *Urinary System*

BREED

Yorkie Mix

The urinary bladder, trigone, and pelvic urethra are normal in thickness and the mucosal surface is smooth. The bladder lumen is moderately distended with anechoic urine. No masses, inflammatory changes or calculi are observed. Ureteral papillae and visualized portion of the proximal urethra, visible to a depth of 2 cm, are normal.

SEX

Male, neutered

The prostate is normal in size (0.71 cm in width) and shape. Parenchyma is homogenous. The prostatic urethra appears normal without evidence of dilation or obstruction.

AGE

7/10/19

The left kidney is normal size (3.22 cm in length); normal shape and architecture with smooth peripheral margins. There is a normal 1:3 cortex to medulla ratio with normal corticomedullary distinction. There is no evidence of pyelectasia, nephroliths, infarcts or hydroureter. Renal vasculature is normal.

WEIGHT

8.68 lbs.

The right kidney is normal size (3.75 cm in length); normal shape and architecture with smooth peripheral margins. There is a normal 1:3 cortex to medulla ratio with normal corticomedullary distinction. There is no evidence of pyelectasia, nephroliths, infarcts or hydroureter. Renal vasculature is normal.

INTERPRETED BY

Andrea Nicastro, DVM,
Diplomate ACVIM
(*Small Animal Internal
Medicine*)

Adrenal Glands

The left adrenal gland is normal size (0.34 cm at cranial pole) (0.40 cm at caudal pole) (1.76 cm in length); normal shape; homogenous parenchyma. The glandular echogenicity and detail are unremarkable. Capsule, cortex, and medullary definition are normal. The phrenicoabdominal vein and surrounding vasculature are normal.

IMAGING PERFORMED BY

Andrea Nicastro, DVM,
Diplomate ACVIM
(*Small Animal Internal
Medicine*)

The right adrenal gland is normal size (0.63 cm at cranial pole) (0.45 cm at caudal pole) (1.81 cm in length); normal shape; homogenous parenchyma. The glandular echogenicity and detail are unremarkable. Capsule, cortex, and medullary definition are normal. The phrenicoabdominal vein and surrounding vasculature are normal.

HOSPITAL NAME

Flowerton AH

Spleen

The spleen is normal in size (1.03 cm in width at the level of the hilus) with a normal capsular contour. There is appropriate echogenicity and echotexture. No focal lesions are observed. Splenic vasculature is normal.

REFERRING VET

Dr. Pignatello

Liver

The liver is subjectively normal in size with normal contours and structure. There is appropriate echogenicity and echotexture. No overt structural evidence of inflammatory, infiltrative or regenerative pathology is evident. Vascular and biliary tracts are of normal volume with no evidence of congestion. No pathological hepatic lymphadenopathy observed. The portal vein: caudal vena cava ratio is approximately 1:1. The gallbladder is of normal contours and contains some dependent echogenic debris. The wall is normal in thickness. No choleliths are observed. The cystic and common bile ducts are normal.

INVOICE

12942

DATE

2/1/22



PATIENT

Gastrointestinal

Spencer Grant

SPECIES

Canine

BREED

Yorkie Mix

SEX

Male, neutered

AGE

7/10/19

WEIGHT

8.68 lbs.

INTERPRETED BY

Andrea Nicastro, DVM,
Diplomate ACVIM
(Small Animal Internal
Medicine)

IMAGING PERFORMED BY

Andrea Nicastro, DVM,
Diplomate ACVIM
(Small Animal Internal
Medicine)

HOSPITAL NAME

Flowerton AH

REFERRING VET

Dr. Pignatello

INVOICE

12942

DATE
2/1/22

Pancreas

The region of the pancreas is isoechoic relative to surrounding omental fat. No obvious parenchymal abnormalities are observed. There is no evidence of regional inflammation or effusion.

Free Abdomen

The peritoneal cavity is normal. There is no evidence of inflammation or effusion. A few prominent mesenteric lymph nodes are visualized, the largest measuring 2.44 cm in length.

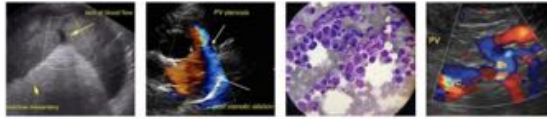
ULTRASONOGRAPHIC FINDINGS

- Bowel pattern suggestive of inflammatory bowel disease. There is some potential for emerging lymphoma. This possibility is considered unlikely at this time.
- The lymph node changes are most consistent with reactive lymphadenitis or lymphoid hyperplasia.

INTERPRETATION OF THE FINDINGS & FURTHER RECOMMENDATIONS

The following diagnostics/treatment recommendations can be considered:

1. Serum cobalamin, folate, PLI and TLI
2. A fecal evaluation for ova/Giardia
3. Prophylactic deworming with Fenbendazole at 50 mg/kg once a day for 5 days is recommended. Repeat above protocol in 3 weeks.
4. A 6-week limited antigen diet trial to assess for food allergies.
5. Consider a 4-week course of Tylosin at 15-20 mg/kg by mouth every 12 hours as empirical treatment for small intestinal bacterial overgrowth.
6. A resting cortisol level to screen for hypoadrenocorticism. If resting cortisol level is < 2.0 mcg/dL, an ACTH stimulation test is recommended.
7. Depending on the results of the above diagnostics/therapeutics, endoscopic or surgical gastrointestinal biopsies may be warranted.



PATIENT

Spencer Grant

SPECIES

Canine

BREED

Yorkie Mix

SEX

Male, neutered

AGE

7/10/19

WEIGHT

8.68 lbs.

INTERPRETED BY

Andrea Nicastro, DVM,
Diplomate ACVIM
(Small Animal Internal
Medicine)

IMAGING PERFORMED BY

Andrea Nicastro, DVM,
Diplomate ACVIM
(Small Animal Internal
Medicine)

HOSPITAL NAME

Flowerton AH

REFERRING VET

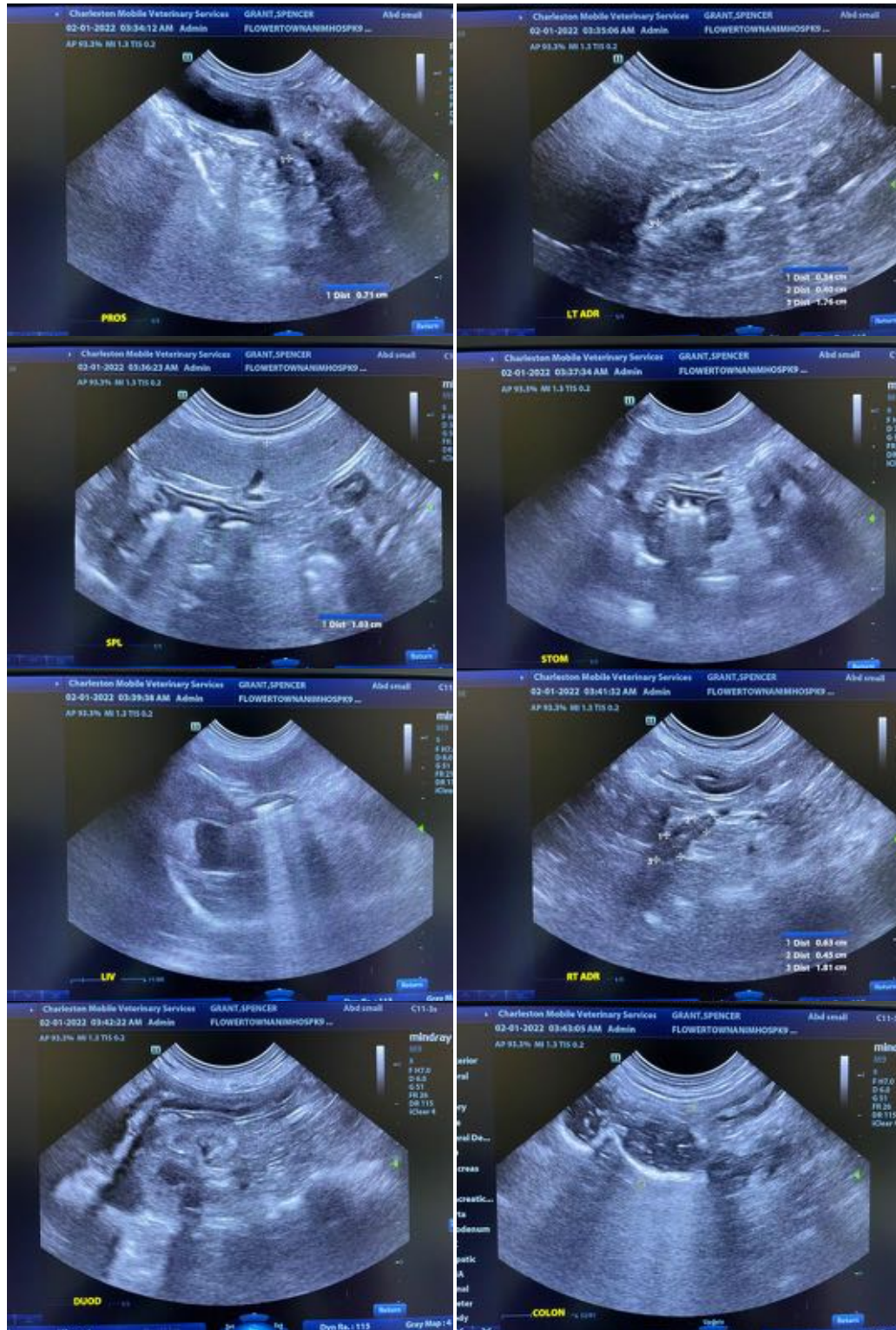
Dr. Pignatello

INVOICE

12942

DATE
2/1/22

8. Three-view thoracic radiographs should be performed prior to any anesthetic event.





PATIENT

Spencer Grant

SPECIES

Canine

BREED

Yorkie Mix

SEX

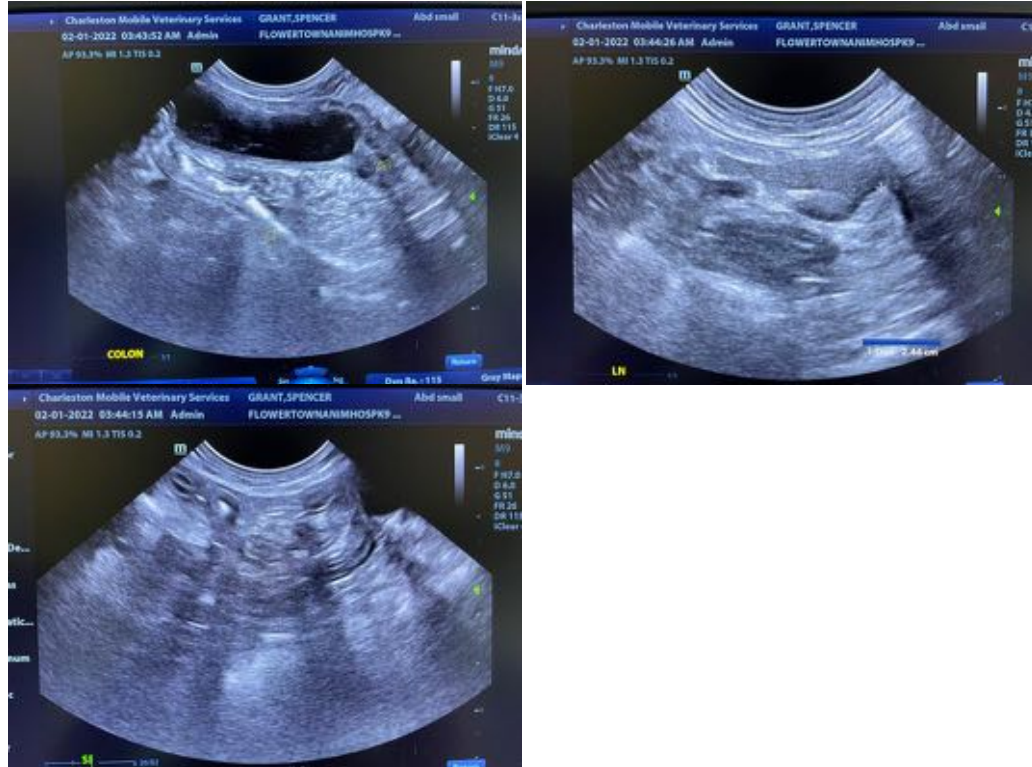
Male, neutered

AGE

7/10/19

WEIGHT

8.68 lbs.



INTERPRETED BY

Andrea Nicastro, DVM,
Diplomate ACVIM
(Small Animal Internal
Medicine)

IMAGING PERFORMED BY

Andrea Nicastro, DVM,
Diplomate ACVIM
(Small Animal Internal
Medicine)

HOSPITAL NAME

Flowerton AH

REFERRING VET

Dr. Pignatello

INVOICE

12942

DATE
2/1/22

The information and recommendations provided are based on the images presented by the referring veterinarian/sonographer. No evaluation can be communicated regarding pathology that was not visible in the image/video clips provided.

Thank you for this referral. If the clinical or image interpretation does not parallel your findings or if I can be of any further assistance please contact me.

Andrea Nicastro, DVM, Diplomate ACVIM (Small Animal Internal Medicine)

Andrea.Nicastro@CharlestonMobile.net