

PATIENT

Nemo Visagie

SPECIES

Canine

BREED

Boston Terrier

SEX

Male, neutered

AGE

10 Yr.

WEIGHT

30.4 lbs.

INTERPRETED BY

Andrea Nicastro, DVM,
Diplomate ACVIM
(*Small Animal Internal
Medicine*)

IMAGING PERFORMED BY

Andrea Nicastro, DVM,
Diplomate ACVIM
(*Small Animal Internal
Medicine*)

HOSPITAL NAME

Trinity Island

REFERRING VET

Dr. Oldham

INVOICE

13421

DATE

12/9/25

PRESENTING CLINICAL SIGNS

Pt has a history of recent onset of PU/PD, lethargy and skin crusting over the past month. Seems to have aged dramatically. ALP 2515, ALT 379, hematocrit 37% with a very strong regenerative response. Thrombocytosis.

ULTRASONOGRAPHIC EXAMINATION OF THE ABDOMEN

Urinary System

The urinary bladder wall is normal in thickness and the mucosal surface is smooth. The bladder is moderately distended. Luminal contents are anechoic. No cystic calculi are observed. The region of the trigone and the proximal urethra, visible to a depth of 2-3 cm, are normal.

The prostate is normal in size (0.90 cm in width) and shape. Parenchyma is homogenous. The prostatic urethra appears normal without evidence of dilation or obstruction.

The left kidney is normal in size (6.46 cm in length) with a normal shape, architecture and smooth peripheral margins. There is a normal 1:3 cortex to medulla ratio with mild to moderate loss of corticomedullary distinction. At least 1-2 small cortical cysts are seen. There is no evidence of pyelectasia, nephroliths, infarcts or hydroureter. Renal vasculature is normal.

The right kidney is normal in size (6.63 cm in length) with a normal shape, architecture and smooth peripheral margins. There is a normal 1:3 cortex to medulla ratio with mild to moderate loss of corticomedullary distinction. A few hyperechoic shadowing diverticular foci are visualized. There is no evidence of pyelectasia, infarcts or hydroureter. Renal vasculature is normal.

Adrenal Glands

The left adrenal gland is enlarged (0.88 cm at cranial pole) (0.98 cm at caudal pole) with swollen peripheral contours. The parenchyma is hypoechoic with some loss of glandular detail. The phrenicoabdominal vein and surrounding vasculature are normal.

The right adrenal gland is enlarged with a mass effect (1.73 cm at cranial pole) (1.47 cm at caudal pole)(3.36 cm in length). The parenchyma is hypoechoic with loss of glandular detail. There is no obvious evidence of vascular invasion.

Spleen

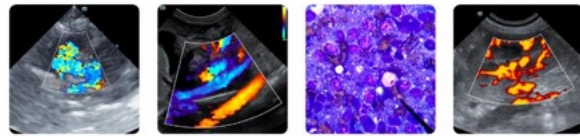
The spleen is normal in size (1.18 cm in width at the level of the hilus) with a normal capsular contour. There is appropriate echogenicity and echotexture. Several irregular hyperechoic nodules are observed throughout the organ, one of the nodules measuring 1.05 cm in its longest dimension. Splenic vasculature is normal.

Liver

The liver is subjectively prominent in size with swollen curvilinear peripheral contours. The parenchyma is isoechoic relative to the spleen and exhibits mild heterogeneity. No distinct focal lesions are observed. Hepatic vasculature and biliary tracts are of normal volume with no evidence of congestion. The portal vein to caudal vena cava ratio is approximately 1:1.

The gall bladder lumen is distended. The wall is normal in thickness. A 4.2 x 2.9 cm irregular hypoechoic to heterogeneous vascular mass with mineralized foci is observed within the lumen. Some echogenic debris is also observed. The common bile duct is mildly dilated (0.45 cm in diameter). The duodenal papilla is normal in size (0.41 cm in width).

Gastrointestinal



PATIENT

Nemo Visagie

SPECIES

Canine

BREED

Boston Terrier

SEX

Male, neutered

AGE

10 Yr.

WEIGHT

30.4 lbs.

INTERPRETED BY

Andrea Nicastro, DVM,
 Diplomate ACVIM
 (Small Animal Internal
 Medicine)

IMAGING PERFORMED BY

Andrea Nicastro, DVM,
 Diplomate ACVIM
 (Small Animal Internal
 Medicine)

HOSPITAL NAME

Trinity Island

REFERRING VET

Dr. Oldham

INVOICE

13421

DATE

12/9/25

The gastric lumen is moderately distended with ingesta. The gastric wall and pylorus are normal in thickness with a normal layering pattern. The pyloric outflow tract is patent. The small intestinal lumen is not dilated. The small intestinal wall is normal in thickness with retention of the normal layering pattern. There is evidence of mucosal speckling +/- linear striations in some segments. Discreet masses are not identified. The ileoceocolic junction and colonic wall are normal. There is no obvious evidence of an obstructive pattern.

Pancreas

The pancreas is diffusely prominent in size with slightly irregular peripheral contours. The parenchyma is hyperechoic to heterogeneous in appearance. The pancreatic duct is not overtly dilated.

Lymph nodes

The abdominal lymph nodes are normal/not visible.

Free Abdomen

Trace free fluid is observed.

Other

A brief echocardiogram reveals no evidence of pericardial effusion or obvious right atrial/auricular mass.

ULTRASONOGRAPHIC FINDINGS

Primary Findings:

- Vascular gallbladder mass. Neoplasia (i.e., carcinoma) is suspected with a lower possibility of a benign process.
- The hepatic changes are nonspecific and could be secondary to inflammatory disease (i.e., cholangiohepatitis, chronic hepatitis), hepatotoxicosis, infiltrative neoplasia (i.e., lymphoma), vacuolar hepatopathy, regenerative nodular hyperplasia, other hepatopathy, or some combination thereof.
- Bilateral adrenomegaly with a mass effect in the right adrenal gland.

Secondary Findings:

- The pancreatic changes are most consistent with age-related parenchymal remodeling, potentially secondary to a prior inflammatory episode, early fibrosis or chronic pancreatitis.
- Bilateral nonspecific, age-related renal changes with left cortical cysts and minor right dystrophic mineralization.
- Small intestinal wall changes could be consistent with inflammatory bowel disease, lymphangiectasia or other enteropathy. Correlation with the patient's long term clinical history is recommended.
- Hyperechoic splenic nodules likely represent benign meylolipomas with a lower possibility of more insidious splenic pathology.



PATIENT

Nemo Visagie

SPECIES

Canine

BREED

Boston Terrier

SEX

Male, neutered

AGE

10 Yr.

WEIGHT

30.4 lbs.

INTERPRETED BY

Andrea Nicastro, DVM,
 Diplomate ACVIM
 (Small Animal Internal
 Medicine)

IMAGING PERFORMED BY

Andrea Nicastro, DVM,
 Diplomate ACVIM
 (Small Animal Internal
 Medicine)

HOSPITAL NAME

Trinity Island

REFERRING VET

Dr. Oldham

INVOICE

13421

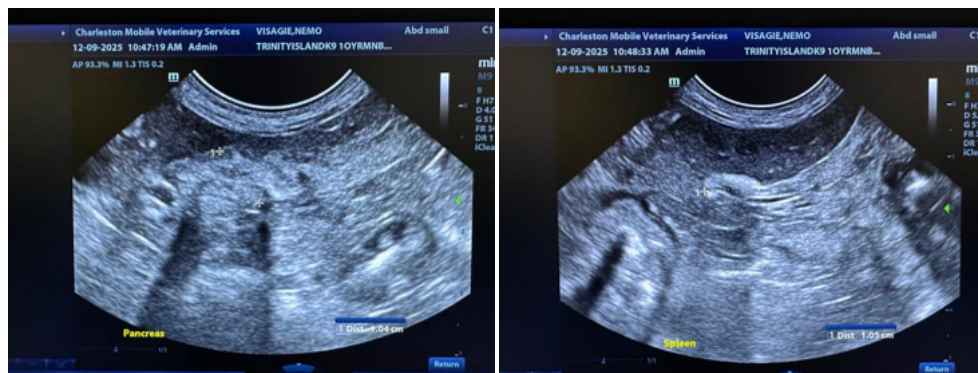
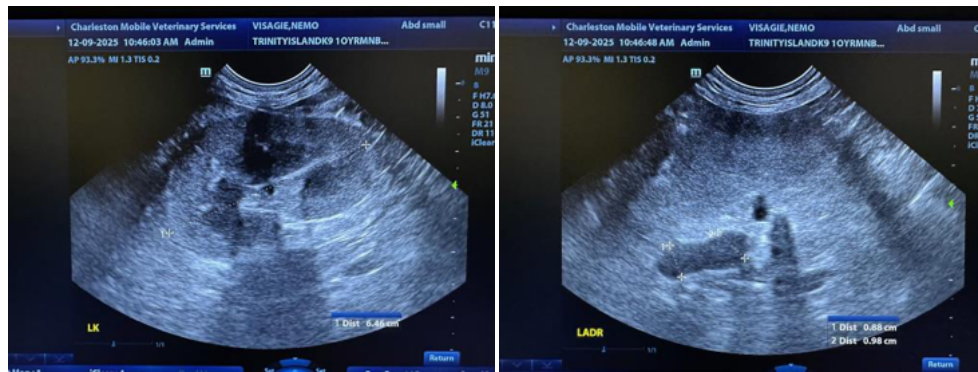
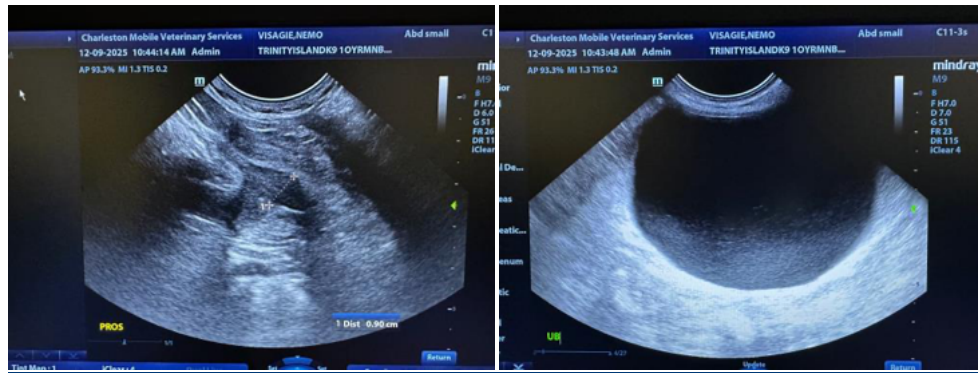
DATE

12/9/25

INTERPRETATION OF THE FINDINGS & FURTHER RECOMMENDATIONS

Given the gallbladder changes, consider the following:

1. Three-view thoracic radiographs are recommended to assess for pulmonary metastases.
2. Consultation with a board-certified surgeon to discuss cholecystectomy with submission of the gallbladder for histopathology. Liver biopsies should also be obtained at the time of surgery. An abdominal CT scan would be useful in pre-surgical planning.
3. If surgery is not pursued, palliative care is recommended including symptomatic treatment for Cushing's disease.
4. Baseline blood pressure measurement is also recommended to evaluate for systemic hypertension.





PATIENT

Nemo Visagie

SPECIES

Canine

BREED

Boston Terrier

SEX

Male, neutered

AGE

10 Yr.

WEIGHT

30.4 lbs.

INTERPRETED BY

Andrea Nicastro, DVM,
 Diplomate ACVIM
 (Small Animal Internal
 Medicine)

**IMAGING
 PERFORMED BY**

Andrea Nicastro, DVM,
 Diplomate ACVIM
 (Small Animal Internal
 Medicine)

HOSPITAL NAME

Trinity Island

REFERRING VET

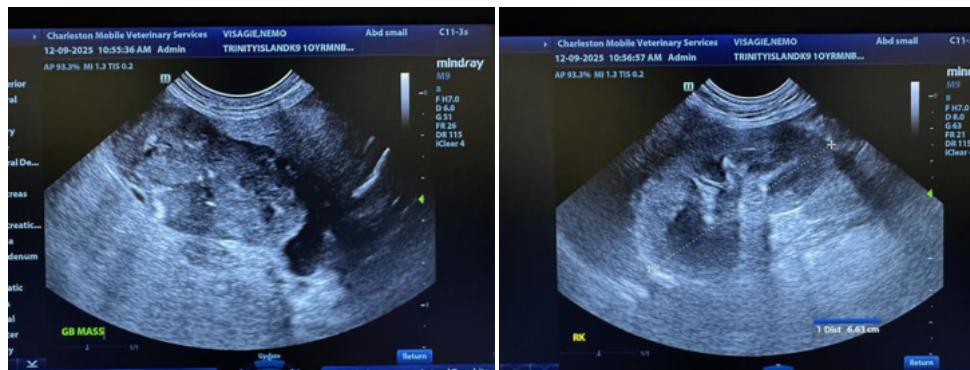
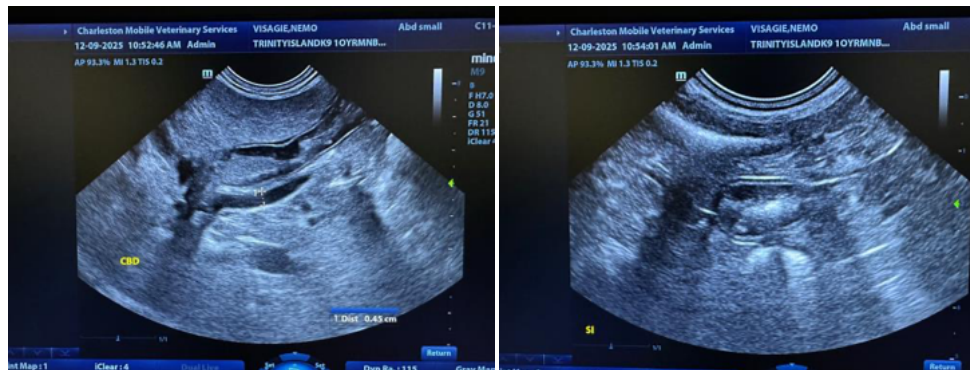
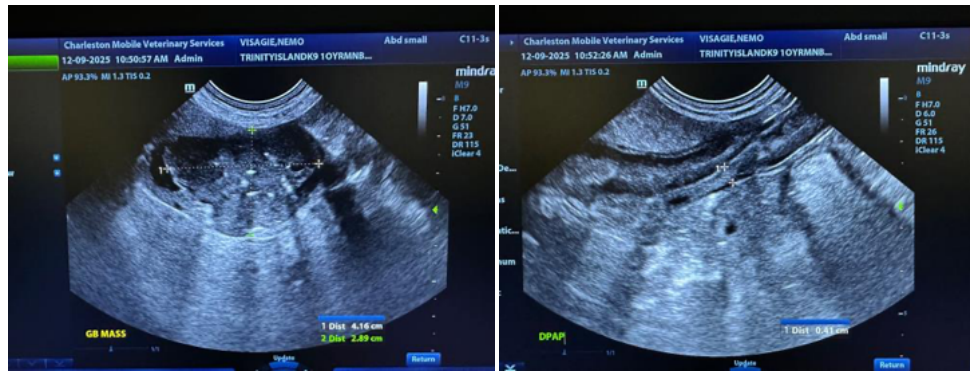
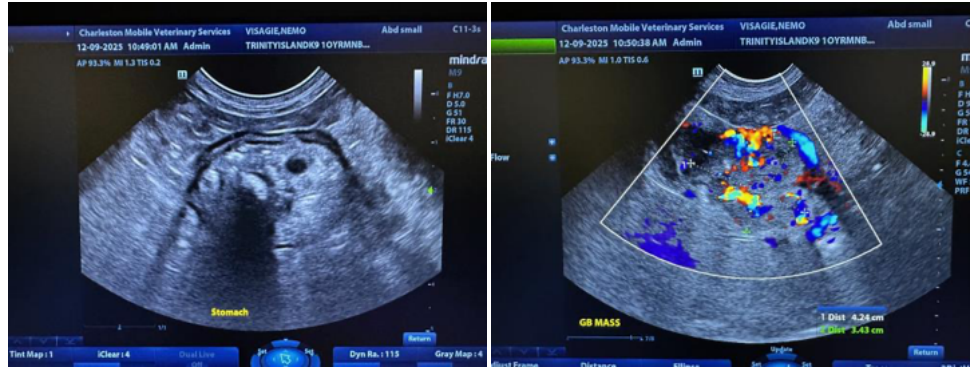
Dr. Oldham

INVOICE

13421

DATE

12/9/25





PATIENT

Nemo Visagie

SPECIES

Canine

BREED

Boston Terrier

SEX

Male, neutered

AGE

10 Yr.

WEIGHT

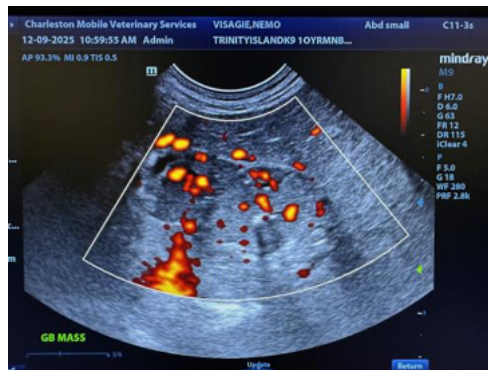
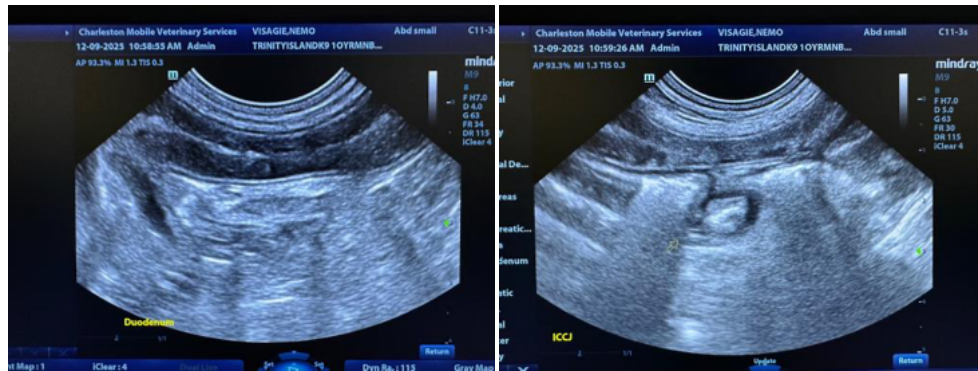
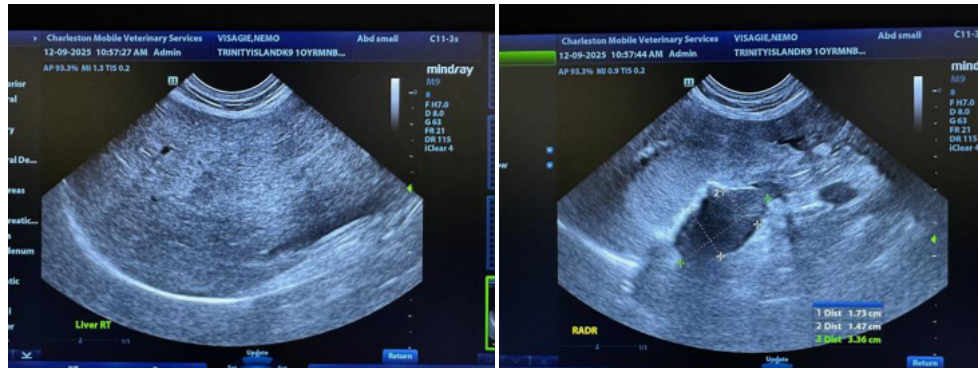
30.4 lbs.

INTERPRETED BY

Andrea Nicastro, DVM,
 Diplomate ACVIM
 (Small Animal Internal
 Medicine)

IMAGING PERFORMED BY

Andrea Nicastro, DVM,
 Diplomate ACVIM
 (Small Animal Internal
 Medicine)



HOSPITAL NAME

Trinity Island

REFERRING VET

Dr. Oldham

INVOICE

13421

DATE

12/9/25

The information and recommendations provided are based on the images presented by the referring veterinarian/sonographer. No evaluation can be communicated regarding pathology that was not visible in the image/video clips provided.

Thank you for this referral. If the clinical or image interpretation does not parallel your findings or if I can be of any further assistance please contact me.

Andrea Nicastro, MPH, DVM, Diplomate DACVIM (Small Animal Internal Medicine)
info@SonoPath.com