



**PATIENT**

Bentley Edwards

**SPECIES**

Canine

**BREED**

Labrador Retriever

**SEX**

Male, neutered

**AGE**

6/19/2017

**WEIGHT**

**INTERPRETED BY**

Andrea Nicastro, DVM,  
Diplomate ACVIM  
(*Small Animal Internal  
Medicine*)

**IMAGING  
PERFORMED BY**

Andrea Nicastro, DVM,  
Diplomate ACVIM  
(*Small Animal Internal  
Medicine*)

**HOSPITAL NAME**

Central VH

**REFERRING VET**

Dr. Reynolds

**INVOICE**

13424

**DATE**

12/9/25

**PRESENTING CLINICAL SIGNS**

Pt presented for lethargy, not acting right. Bloodwork revealed a hematocrit of 16%. WBC count normal and platelets low at 43,000. T-bili 1.0. Albumin 1.7, globulins 1.3. BW in August unremarkable. Prednisone started yesterday.

**ULTRASONOGRAPHIC EXAMINATION OF THE ABDOMEN**

**Urinary System**

The urinary bladder wall is normal in thickness and the mucosal surface is smooth. The bladder is distended. A scant amount of echogenic debris is suspended within the lumen. No cystic calculi are observed. The region of the trigone and the proximal urethra, visible to a depth of 2 cm, are normal.

The prostate is normal in size (1.10 cm in width) and shape. Parenchyma is homogenous. The prostatic urethra appears normal without evidence of dilation or obstruction.

The left kidney is normal in size (8.14 cm in length) with a normal shape, architecture and smooth peripheral margins. There is a normal 1:3 cortex to medulla ratio with minimal loss of corticomedullary distinction. There is no evidence of pyelectasia, nephroliths, infarcts or hydroureter. Renal vasculature is normal.

The right kidney is normal in size (7.70 cm in length) with a normal shape, architecture and smooth peripheral margins. There is a normal 1:3 cortex to medulla ratio with minimal loss of corticomedullary distinction. There is no evidence of pyelectasia, nephroliths, infarcts or hydroureter. Renal vasculature is normal.

**Adrenal Glands**

The left adrenal gland is normal in size (0.69 cm at cranial pole) (0.68 cm at caudal pole) with a normal shape and homogenous parenchyma. The glandular echogenicity and detail are unremarkable. Capsule, cortex, and medullary definition are normal. The phrenicoabdominal vein and surrounding vasculature are normal.

The right adrenal gland is subjectively normal in length (0.68 cm at cranial pole) (0.49 cm at caudal pole) with a slightly flattened contour. The glandular echogenicity and detail are unremarkable. The phrenicoabdominal vein and surrounding vasculature are normal.

**Spleen**

The spleen is overall normal in size (1.49 cm in width at the level of the hilus). The parenchyma is subjectively mildly hypoechoic. A 2.3 cm swelling is observed at the medial aspect just caudal to the hilus. The parenchyma is homogeneous. Splenic vasculature is normal with no evidence of thrombosis.

**Liver**

The liver is subjectively enlarged with swollen peripheral contours. The parenchyma is hyperechoic relative to the spleen and subtly heterogeneous in appearance. Several varying sized hypoechoic to heterogeneous nodule/masses are observed throughout the organ. One of the larger lesions measures 2.6 cm its longest dimension. Vascular and biliary tracts are of normal volume with no evidence of congestion.

The gall bladder lumen is moderately distended. The wall is thin and smooth. Luminal contents are mostly anechoic. The cystic and common bile ducts are normal/not seen.



**PATIENT**

Bentley Edwards

**SPECIES**

Canine

**BREED**

Labrador Retriever

**SEX**

Male, neutered

**AGE**

6/19/2017

**WEIGHT**

**INTERPRETED BY**

Andrea Nicastro, DVM,  
Diplomate ACVIM  
(Small Animal Internal  
Medicine)

**IMAGING  
PERFORMED BY**

Andrea Nicastro, DVM,  
Diplomate ACVIM  
(Small Animal Internal  
Medicine)

**HOSPITAL NAME**

Central VH

**REFERRING VET**

Dr. Reynolds

**INVOICE**

13424

**DATE**

12/9/25

**Gastrointestinal**

The gastric lumen is mildly distended with ingesta. The gastric wall and pylorus are normal in thickness with a normal layering pattern. The pyloric outflow tract is patent. The small intestinal lumen is not dilated. The small intestinal wall is normal to borderline thickened (up to 0.45 cm) with retention of the normal layering pattern. Discreet masses are not identified. The ileocecolic junction and colonic wall are normal. There is no obvious evidence of an obstructive pattern.

**Pancreas**

The region of the pancreas is isoechoic relative to surrounding omental fat. No obvious parenchymal abnormalities are observed. There is no evidence of regional inflammation or effusion.

**Lymph nodes**

A cluster of enlarged irregular hypoechoic to heterogeneous mesenteric lymph nodes are observed adjacent to the ileocecolic junction, one of the largest measuring 7.3 x 2.9 cm. Surrounding mesentery is hyperechoic.

**Free Abdomen**

The mesentery throughout the abdomen is hyperechoic and irregular bordering on nodular in appearance. A moderate amount of free fluid is present.

**Other**

A brief echocardiogram reveals no evidence of pericardial effusion or obvious right atrial/auricular mass.

**ULTRASONOGRAPHIC FINDINGS**

**Primary Findings:**

- The mesenteric lymphadenopathy is concerning for infiltrative neoplasia (i.e., round cell tumor) with a lower possibility of severe lymphadenitis.
- The hepatic nodules/masses are also concerning for neoplasia (i.e., round cell tumor, carcinoma, sarcoma) with a lower possibility of benign lesions (i.e., regenerative nodules, inflammatory lesions, other). The diffuse hepatic parenchymal changes are non-specific and could be secondary to vacuolar hepatopathy, regenerative nodular hyperplasia, inflammatory disease, infiltrative neoplasia, hepatotoxicosis (i.e., copper), fibrosis, and/or other hepatopathy.
- Ascites with mesenteric changes most consistent with reactive change, however infiltrative neoplasia within the mesentery cannot be excluded.

**Secondary Findings:**

- The splenic swelling at the medial aspect may represent normal parenchyma. Other considerations include lymphoid hyperplasia, extramedullary hematopoiesis, splenitis, antigenic stimulation or emerging neoplasia.
- The flattened right adrenal gland may be a normal variant for this patient or may be secondary to atrophy.
- The small intestinal wall thickening may be secondary to inflammation, emerging neoplasia (less likely) or may be a normal variant for this patient.

\*A recheck CBC was performed at the end of the study. Platelet count still low at approximately 40,000-50,000 on a blood smear. Therefore, aspiration of the enlarged lymph nodes is not recommended. Hematocrit at 12% today.



**PATIENT**

Bentley Edwards

**SPECIES**

Canine

**BREED**

Labrador Retriever

**SEX**

Male, neutered

**AGE**

6/19/2017

**WEIGHT**

**INTERPRETATION OF THE FINDINGS & FURTHER RECOMMENDATIONS**

Consider referral for blood transfusion, supportive care and oncology consultation vs palliative care.

**INTERPRETED BY**

Andrea Nicastro, DVM,  
 Diplomate ACVIM  
 (Small Animal Internal  
 Medicine)

**IMAGING PERFORMED BY**

Andrea Nicastro, DVM,  
 Diplomate ACVIM  
 (Small Animal Internal  
 Medicine)

**HOSPITAL NAME**

Central VH

**REFERRING VET**

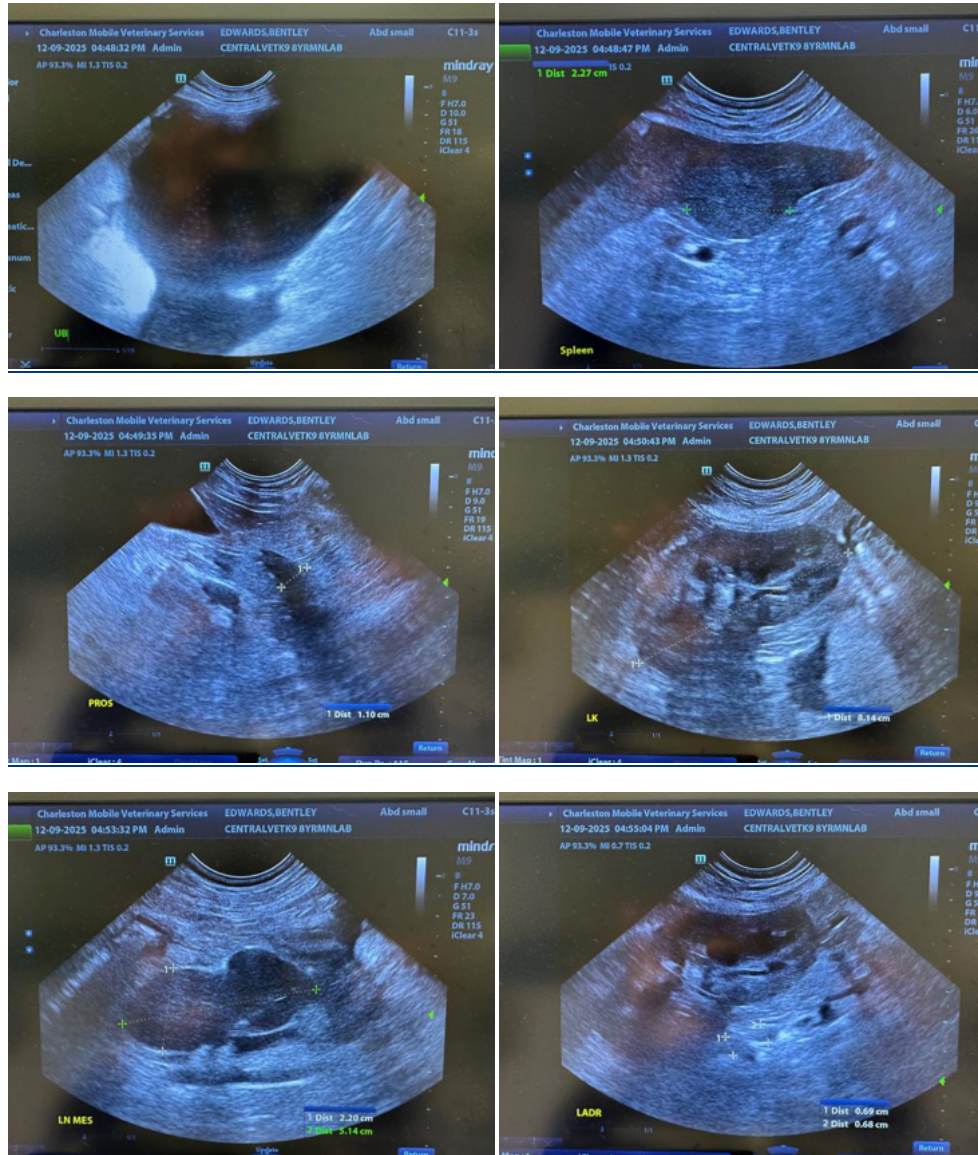
Dr. Reynolds

**INVOICE**

13424

**DATE**

12/9/25





**PATIENT**

Bentley Edwards

**SPECIES**

Canine

**BREED**

Labrador Retriever

**SEX**

Male, neutered

**AGE**

6/19/2017

**WEIGHT**

**INTERPRETED BY**

Andrea Nicastro, DVM,  
 Diplomate ACVIM  
 (Small Animal Internal  
 Medicine)

**IMAGING PERFORMED BY**

Andrea Nicastro, DVM,  
 Diplomate ACVIM  
 (Small Animal Internal  
 Medicine)

**HOSPITAL NAME**

Central VH

**REFERRING VET**

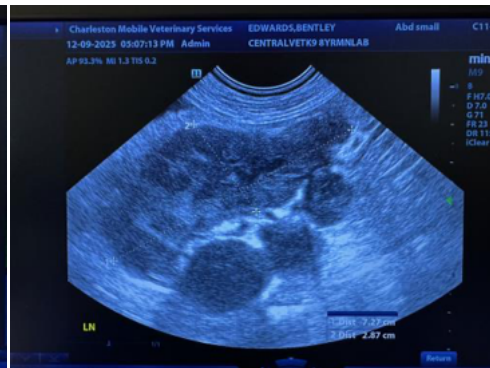
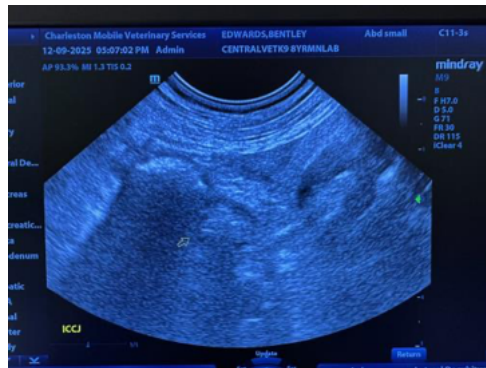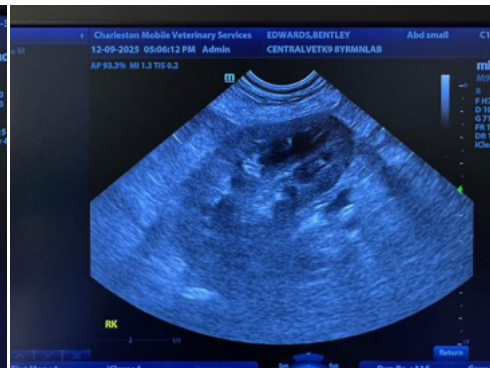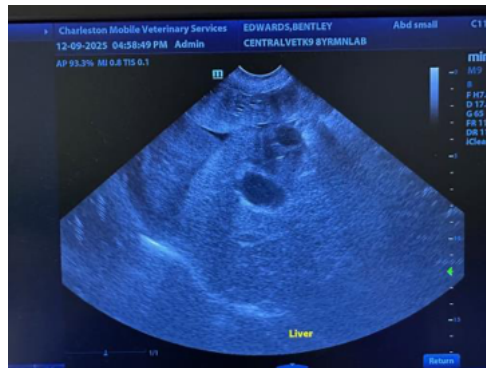
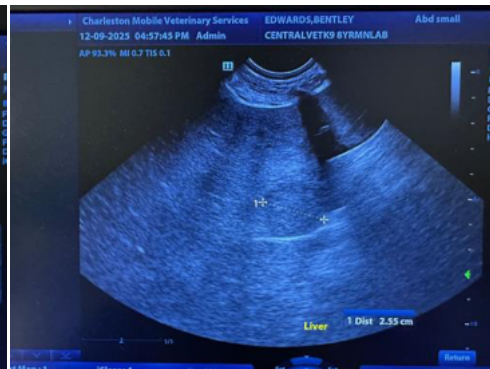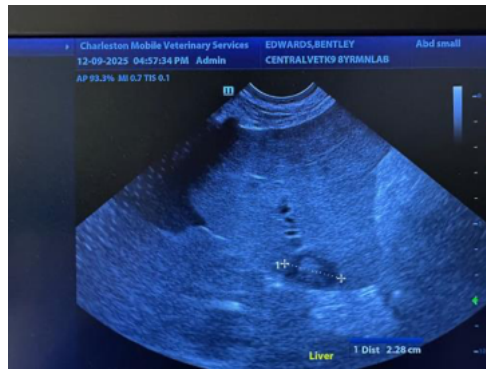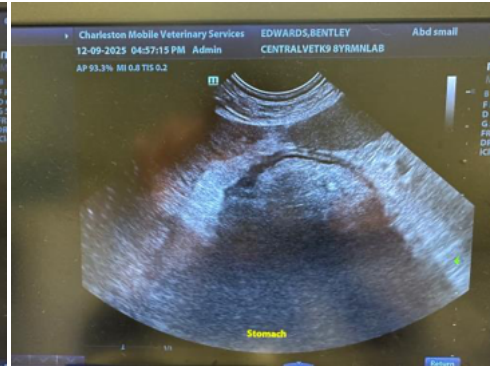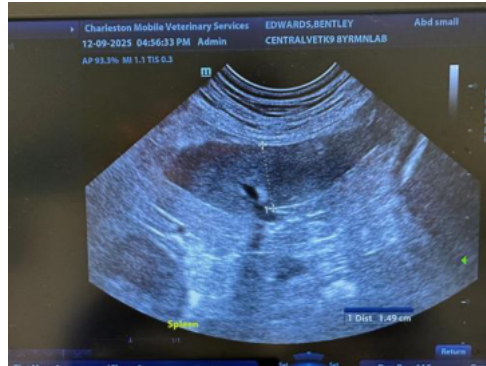
Dr. Reynolds

**INVOICE**

13424

**DATE**

12/9/25





**PATIENT**

Bentley Edwards

**SPECIES**

Canine

**BREED**

Labrador Retriever

**SEX**

Male, neutered

**AGE**

6/19/2017

**WEIGHT**

**INTERPRETED BY**

Andrea Nicastro, DVM,  
 Diplomate ACVIM  
 (Small Animal Internal  
 Medicine)

**IMAGING PERFORMED BY**

Andrea Nicastro, DVM,  
 Diplomate ACVIM  
 (Small Animal Internal  
 Medicine)

**HOSPITAL NAME**

Central VH

**REFERRING VET**

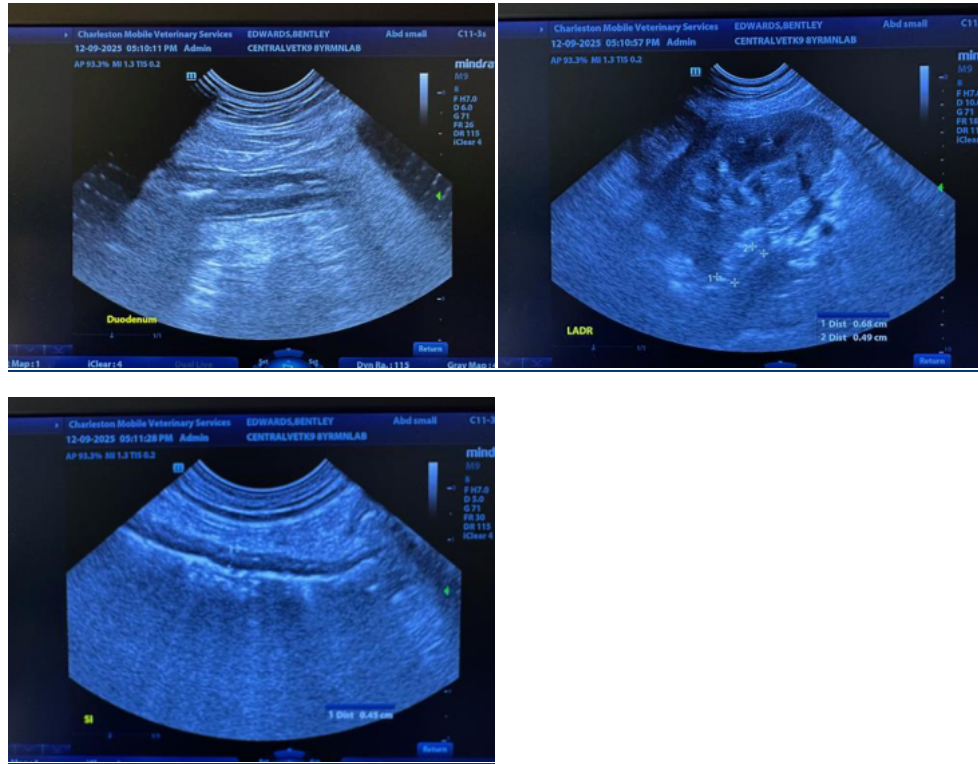
Dr. Reynolds

**INVOICE**

13424

**DATE**

12/9/25



The information and recommendations provided are based on the images presented by the referring veterinarian/sonographer. No evaluation can be communicated regarding pathology that was not visible in the image/video clips provided.

Thank you for this referral. If the clinical or image interpretation does not parallel your findings or if I can be of any further assistance please contact me.

Andrea Nicastro, MPH, DVM, Diplomate DACVIM (Small Animal Internal Medicine)  
[info@SonoPath.com](mailto:info@SonoPath.com)