



PATIENT PRESENTING CLINICAL SIGNS

Bindi Lofgren Inappropriate urination - r/o urinary incontinence vs secondary to cause of PU/PD. Chest x-rays- no obvious evidence of metastatic disease.

SPECIES ULTRASONOGRAPHIC EXAMINATION OF THE ABDOMEN

Canine *Urinary System*

BREED The urinary bladder wall is normal in thickness and the mucosal surface is smooth. The bladder lumen is moderately distended with anechoic urine. No masses, inflammatory changes or calculi are observed. Ureteral papillae and visualized portion of the proximal urethra, visible to a depth of 3-4 cm, are normal.

Australian CattleDog

SEX The left kidney is normal size (6.65 cm in length); normal shape and architecture with smooth peripheral margins. There is a normal 1:3 cortex to medulla ratio with minimal loss of corticomedullary distinction. There is no evidence of pyelectasia, nephroliths, infarcts or hydroureter. Renal vasculature is normal.

Female, spayed

AGE The right kidney is normal size (7.33 cm in length); normal shape and architecture with smooth peripheral margins. There is a normal 1:3 cortex to medulla ratio with minimal loss of corticomedullary distinction. There is no evidence of pyelectasia, nephroliths, infarcts or hydroureter. Renal vasculature is normal.

9/9/2013

WEIGHT *Adrenal Glands*

49.9 lbs. The left adrenal gland is normal size (0.59 cm at cranial pole) (0.69 cm at caudal pole); normal shape; homogenous parenchyma. The glandular echogenicity and detail are unremarkable. Capsule, cortex, and medullary definition are normal. The phrenicoabdominal vein and surrounding vasculature are normal.

INTERPRETED BY

Andrea Nicastro, DVM,
Diplomate ACVIM
(*Small Animal Internal
Medicine*)

The right adrenal gland is normal size (1.14 cm at cranial pole) (0.63 cm at caudal pole); normal shape; homogenous parenchyma. The glandular echogenicity and detail are unremarkable. Capsule, cortex, and medullary definition are normal. The phrenicoabdominal vein and surrounding vasculature are normal.

IMAGING PERFORMED BY

Andrea Nicastro, DVM,
Diplomate ACVIM
(*Small Animal Internal
Medicine*)

Spleen

The spleen is normal in size (1.56 cm in width at the level of the hilus) with a normal capsular contour. There is appropriate echogenicity and echotexture. No focal lesions are observed. Splenic vasculature is normal.

HOSPITAL NAME

Southside AH

Liver

The liver is subjectively prominent in size with slightly swollen peripheral contours. The parenchyma is hypochoic relative to the spleen. 2-3 heterogeneous cavitated nodules/masses are observed. One is deep on the right side, adjacent to the diaphragm. Another is causing compression of the gallbladder. A third possible mass is observed on the left side. The remaining parenchyma is mottled in appearance. Deep on the right side, a multi-septated cystic area is also seen. Vascular and biliary tracts are of normal volume with no evidence of congestion. The gall bladder lumen is moderately distended. The wall is thin and smooth. A small to moderate amount of gravity-dependent echogenic to mineralized debris is observed within the lumen. The cystic and common bile ducts are normal/not seen.

REFERRING VET

Dr. Kevin Moser

INVOICE

14301

DATE

12/6/22

Gastrointestinal



PATIENT

Bindi Lofgren

The stomach and intestine are free of stasis and exhibit normal peristaltic activity. The gastric lumen is not distended. The gastric wall and pylorus are normal in thickness with a normal layering pattern. The pyloric outflow tract is patent. The small intestinal lumen is not dilated. The small intestinal wall thickness is normal with a normal layering pattern and appropriate mural detail. Discreet masses are not identified. The colonic wall is normal. No obstructive disease is noted.

SPECIES

Canine

Pancreas

BREED

Australian CattleDog

The left limb is visible/prominent. The parenchyma is largely isoechoic relative to surrounding omental fat and mottled in appearance. The pancreatic duct is not overtly dilated. See also *Other*.

Free Abdomen

SEX

Female, spayed

The peritoneal cavity is normal. There is no evidence of inflammation or effusion.

Lymph Nodes

See *Other*.

AGE

9/9/2013

Other

In the left cranial quadrant, an approximately 5 cm irregular, echogenic, cavitated mass is visualized.

WEIGHT

49.9 lbs.

A brief echocardiogram reveals no evidence of pericardial effusion or obvious right atrial/auricular mass.

INTERPRETED BY

Andrea Nicastro, DVM,
Diplomate ACVIM
(*Small Animal Internal
Medicine*)

ULTRASONOGRAPHIC FINDINGS

Primary Findings:

- The origin of the mass in the left cranial quadrant is unclear. A pancreatic origin is suspected. Other possible origins include mass in the lymph node, mesentery, liver, spleen, other.
- The remaining pancreatic changes in the left limb are suggestive of age-related remodeling.

IMAGING PERFORMED BY

Andrea Nicastro, DVM,
Diplomate ACVIM
(*Small Animal Internal
Medicine*)

Secondary Findings:

- The hepatic nodule/masses are concerning for metastatic lesions. Other possibilities including inflammatory foci or other benign changes (i.e., nodular hyperplasia).
- The diffuse hepatic parenchymal changes are non-specific and could be secondary to inflammatory disease, hepatotoxicosis (i.e., copper), fibrosis +/- concurrent age-related changes (i.e., regenerative nodular hyperplasia).

HOSPITAL NAME

Southside AH

REFERRING VET

Dr. Kevin Moser

*A fine needle aspirate of the mass in the left cranial quadrant was performed at the end of the study. Post-aspiration, a small amount of free fluid was noted adjacent to the mass. The area was monitored sonographically for 10 minutes post-aspiration without changes.

INVOICE

14301

INTERPRETATION OF THE FINDINGS & FURTHER RECOMMENDATIONS

If cytology results are inconclusive and an aggressive approach is desired, an abdominal exploratory with mass removal and biopsies of the hepatic nodules/masses can be considered. An abdominal CT scan

DATE

12/6/22



PATIENT

would be useful in pre-surgical planning. However, given the possibility of metastatic disease, palliative care should also be considered in lieu of invasive procedures.

Bindi Lofgren

SPECIES

Canine

BREED

Australian CattleDog

SEX

Female, spayed

AGE

9/9/2013

WEIGHT

49.9 lbs.

INTERPRETED BY

Andrea Nicastro, DVM,
Diplomate ACVIM
(Small Animal Internal
Medicine)

IMAGING PERFORMED BY

Andrea Nicastro, DVM,
Diplomate ACVIM
(Small Animal Internal
Medicine)

HOSPITAL NAME

Southside AH

REFERRING VET

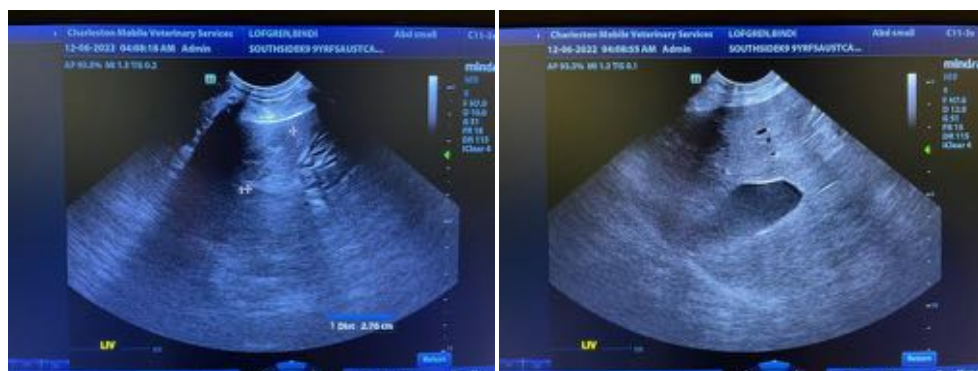
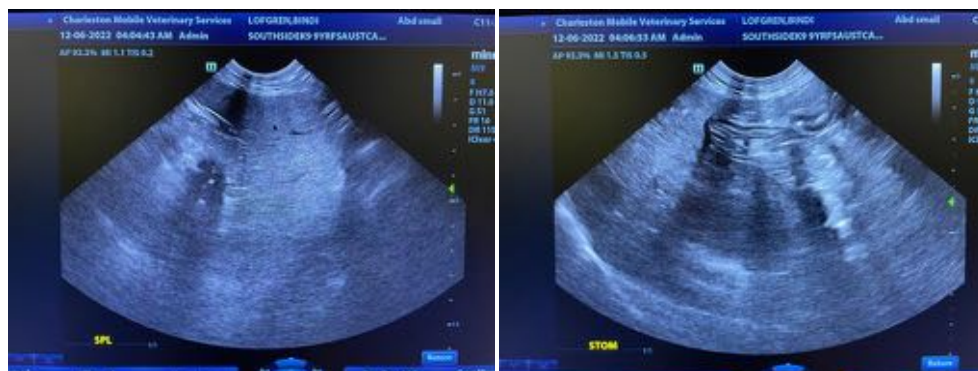
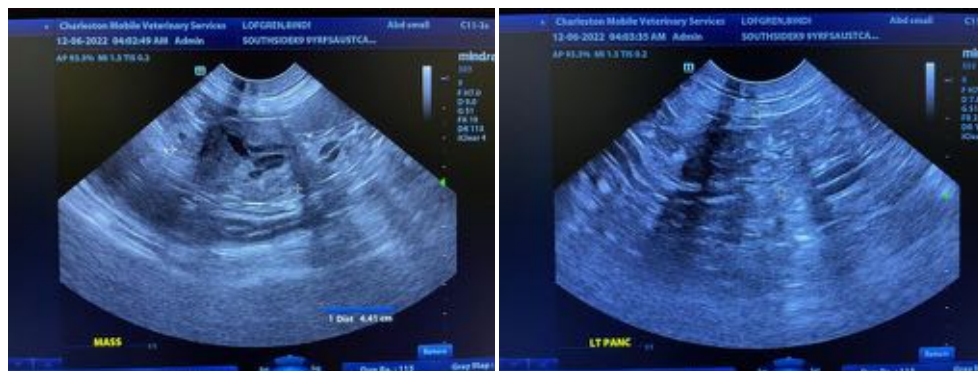
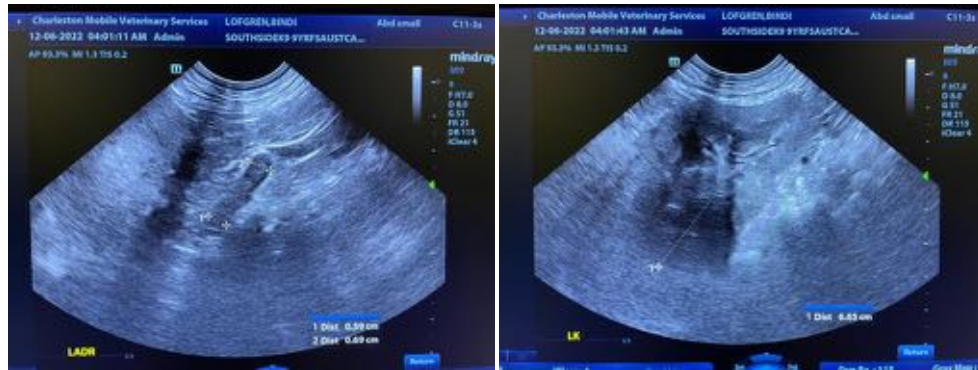
Dr. Kevin Moser

INVOICE

14301

DATE

12/6/22





PATIENT

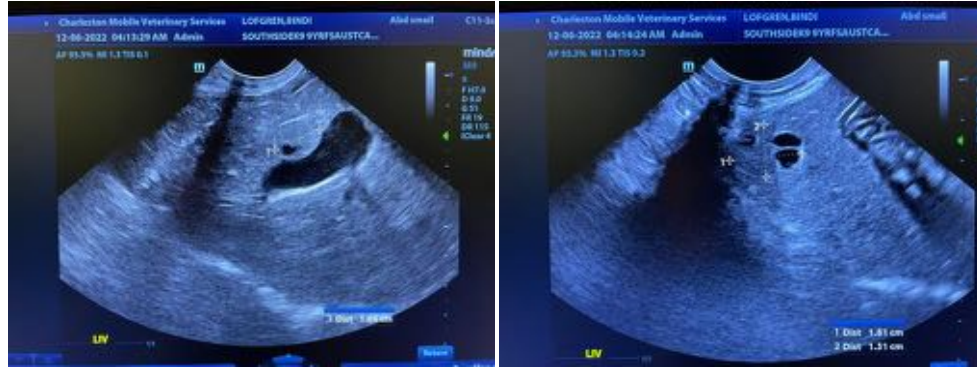
Bindi Lofgren

SPECIES

Canine

BREED

Australian CattleDog



SEX

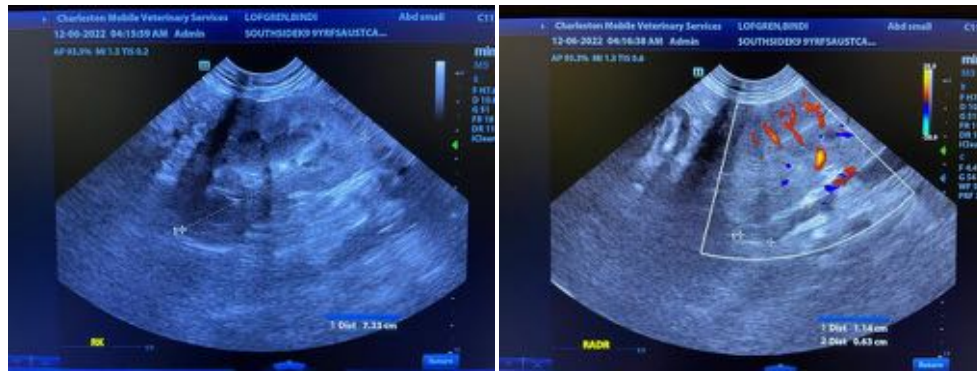
Female, spayed

AGE

9/9/2013

WEIGHT

49.9 lbs.

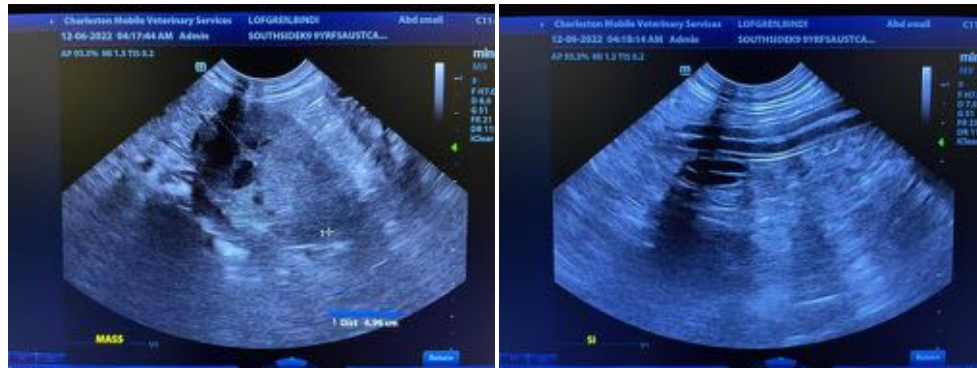


INTERPRETED BY

Andrea Nicastro, DVM,
Diplomate ACVIM
(Small Animal Internal
Medicine)

IMAGING PERFORMED BY

Andrea Nicastro, DVM,
Diplomate ACVIM
(Small Animal Internal
Medicine)



HOSPITAL NAME

Southside AH

REFERRING VET

Dr. Kevin Moser

INVOICE

14301

DATE

12/6/22

The information and recommendations provided are based on the images presented by the referring veterinarian/sonographer. No evaluation can be communicated regarding pathology that was not visible in the image/video clips provided.

Thank you for this referral. If the clinical or image interpretation does not parallel your findings or if I can be of any further assistance please contact me.

Andrea Nicastro, MPH, DVM, Diplomate DACVIM (Small Animal Internal Medicine)
info@SonoPath.com