



PATIENT

Huck Wilson

SPECIES

Feline

BREED

Domestic shorthair

SEX

Male, neutered

AGE

9/1/2013

WEIGHT

10.1 lbs.

INTERPRETED BY

Andrea Nicastro, DVM,
Diplomate ACVIM
(*Small Animal Internal
Medicine*)

**IMAGING
PERFORMED BY**

Andrea Nicastro, DVM,
Diplomate ACVIM
(*Small Animal Internal
Medicine*)

HOSPITAL NAME

Saddleback

REFERRING VET

Dr. Klein

INVOICE

13360

DATE

12/30/25

PRESENTING CLINICAL SIGNS

Pt has a history of weight loss and vomiting. Bloodwork showed a WBC count of 26,000 with a neutrophilia. Chem panel WNL.

ULTRASONOGRAPHIC EXAMINATION OF THE ABDOMEN

Urinary System

The urinary bladder wall is normal in thickness and the mucosal surface is smooth. The bladder is moderately distended. Luminal contents are anechoic. No cystic calculi are observed. The region of the trigone and the proximal urethra, visible to a depth of 2 cm, are normal.

The left kidney is normal in size (3.92 cm in length) with a normal shape, architecture and smooth peripheral margins. There is a normal 1:3 cortex to medulla ratio with mild loss of corticomedullary distinction. There is no evidence of pyelectasia, nephroliths, infarcts or hydronephrosis. Renal vasculature is normal.

The right kidney is normal in size (3.85 cm in length) with a normal shape, architecture and smooth peripheral margins. There is a normal 1:3 cortex to medulla ratio with mild to moderate loss of corticomedullary distinction. There is no evidence of pyelectasia, nephroliths, infarcts or hydronephrosis. Renal vasculature is normal.

Adrenal Glands

The left adrenal gland is normal size (0.47 cm width). Normal shape and glandular echogenicity. The phrenicoabdominal vein and surrounding vasculature are normal.

The right adrenal gland is normal size (0.40 cm width). Normal shape and glandular echogenicity. The phrenicoabdominal vein and surrounding vasculature are normal.

Spleen

The spleen is normal in size (0.84 cm in width at the level of the hilus) with a normal capsular contour. There is appropriate echogenicity and echotexture. No focal lesions are observed. Splenic vasculature is normal.

Liver

The liver is subjectively normal in size with normal curvilinear peripheral contours. The parenchyma is isoechoic relative to the spleen and diffusely homogeneous in appearance. No distinct focal lesions are observed. Vascular and biliary tracts are of normal volume with no evidence of congestion. The portal vein to caudal vena cava ratio is approximately 1:1.

The gallbladder is of normal contours and contains some dependent echogenic debris. The wall is normal in thickness. No choleliths are observed. The cystic and common bile ducts are normal.

Gastrointestinal

The gastric lumen is not distended. The gastric wall and pylorus are normal in thickness with a normal layering pattern. The pyloric outflow tract is patent. The small intestinal lumen is not dilated. The small intestinal wall is normal in thickness with a normal layering pattern and appropriate mural detail. Discreet masses are not identified. The ileocecolic junction and colonic wall are normal. There is no evidence of an obstructive pattern.

Pancreas

The base and limbs of the pancreas are visible with normal curvilinear peripheral contours. The parenchyma is slightly hypoechoic relative to surrounding omental fat and slightly mottled in appearance.



PATIENT

Huck Wilson

SPECIES

Feline

BREED

Domestic shorthair

SEX

Male, neutered

AGE

9/1/2013

WEIGHT

10.1 lbs.

INTERPRETED BY

Andrea Nicastro, DVM,
Diplomate ACVIM
(Small Animal Internal
Medicine)

IMAGING PERFORMED BY

Andrea Nicastro, DVM,
Diplomate ACVIM
(Small Animal Internal
Medicine)

HOSPITAL NAME

Saddleback

REFERRING VET

Dr. Klein

INVOICE

13360

DATE

12/30/25

The pancreatic duct is visible but not overtly dilated. There is no evidence of peripancreatic inflammation or effusion.

Lymph nodes

A few mesenteric lymph nodes adjacent to the ileocecolic junction are visible, one of the nodes measuring 0.44 cm in its longest dimension. Surrounding mesentery is slightly hyperechoic.

Free Abdomen

There is no obvious evidence of free fluid.

Other

A brief echocardiogram reveals no obvious evidence of pericardial or pleural effusion in the visible window.

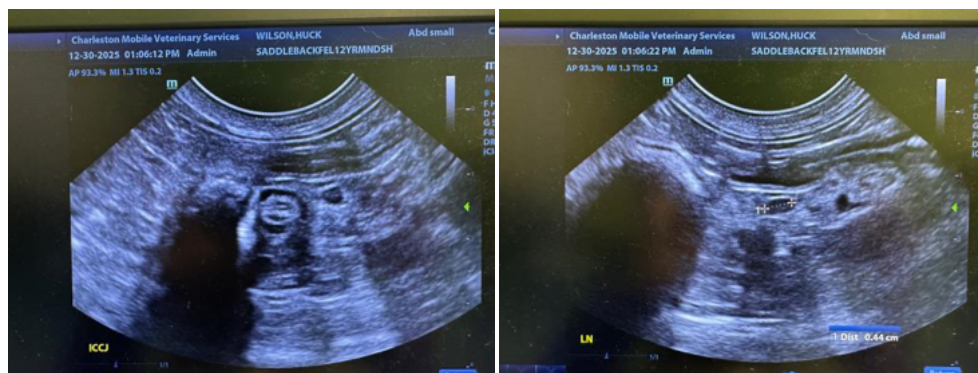
ULTRASONOGRAPHIC FINDINGS

- The pancreatic changes are most consistent with age-related parenchymal remodeling, potentially secondary to a prior inflammatory episode, early fibrosis or chronic pancreatitis.
- Bilateral nonspecific age-related renal changes.

*An obvious cause for the patient's clinical signs is not definitively identified in this study. Considerations include maldigestion/malabsorption, orthopedic or neurologic disease, underlying metabolic issue, occult neoplasia, other.

INTERPRETATION OF THE FINDINGS & FURTHER RECOMMENDATIONS

1. Consider three-view thoracic radiographs to assess for occult pathology in the chest.
2. Also consider a GI panel including serum cobalamin, folate, TLI and PLI.
3. A recheck CBC with clinical pathology review is also recommended.
4. Depending on results of the above diagnostics, further workup may be indicated.





PATIENT

Huck Wilson

SPECIES

Feline

BREED

Domestic shorthair

SEX

Male, neutered

AGE

9/1/2013

WEIGHT

10.1 lbs.

INTERPRETED BY

Andrea Nicastro, DVM,
 Diplomate ACVIM
 (Small Animal Internal
 Medicine)

IMAGING PERFORMED BY

Andrea Nicastro, DVM,
 Diplomate ACVIM
 (Small Animal Internal
 Medicine)

HOSPITAL NAME

Saddleback

REFERRING VET

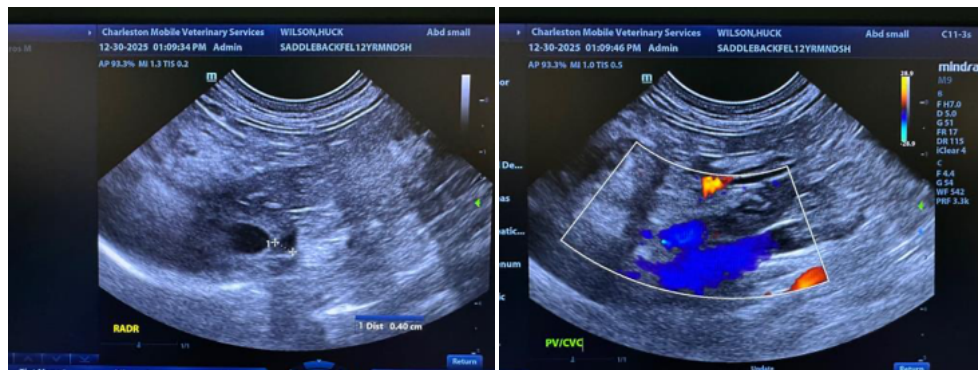
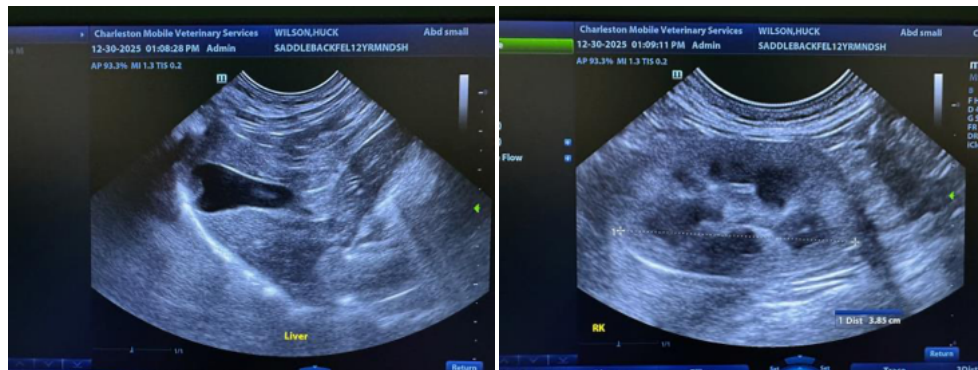
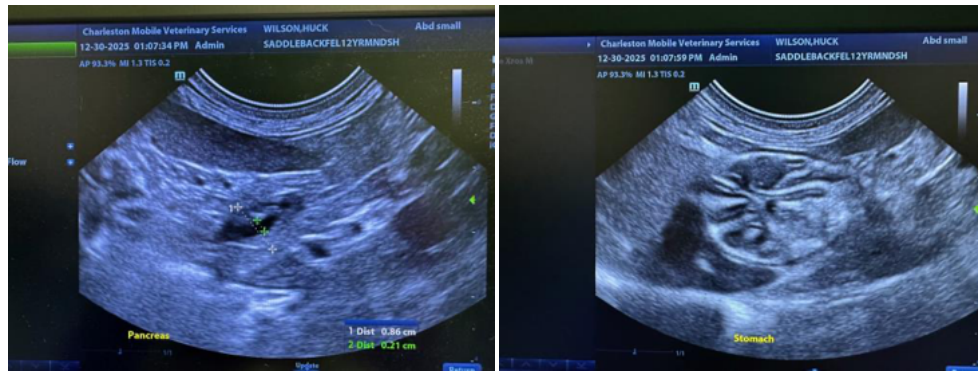
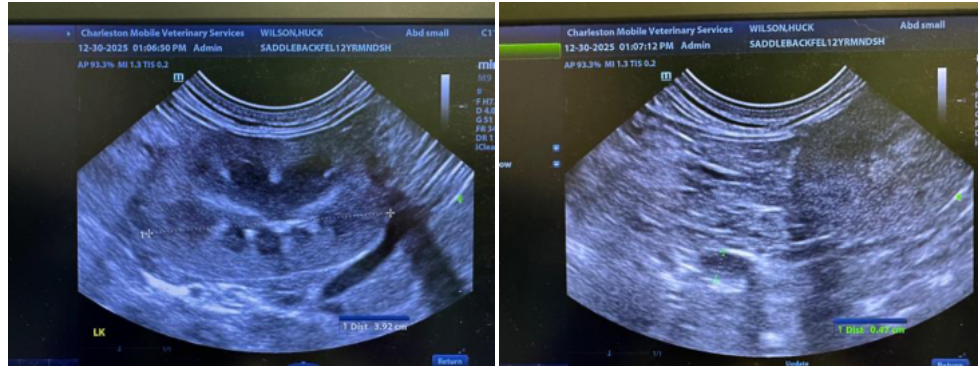
Dr. Klein

INVOICE

13360

DATE

12/30/25





PATIENT

Huck Wilson

SPECIES

Feline

BREED

Domestic shorthair

SEX

Male, neutered

AGE

9/1/2013

WEIGHT

10.1 lbs.

INTERPRETED BY

Andrea Nicastro, DVM,
 Diplomate ACVIM
 (Small Animal Internal
 Medicine)

IMAGING PERFORMED BY

Andrea Nicastro, DVM,
 Diplomate ACVIM
 (Small Animal Internal
 Medicine)

HOSPITAL NAME

Saddleback

REFERRING VET

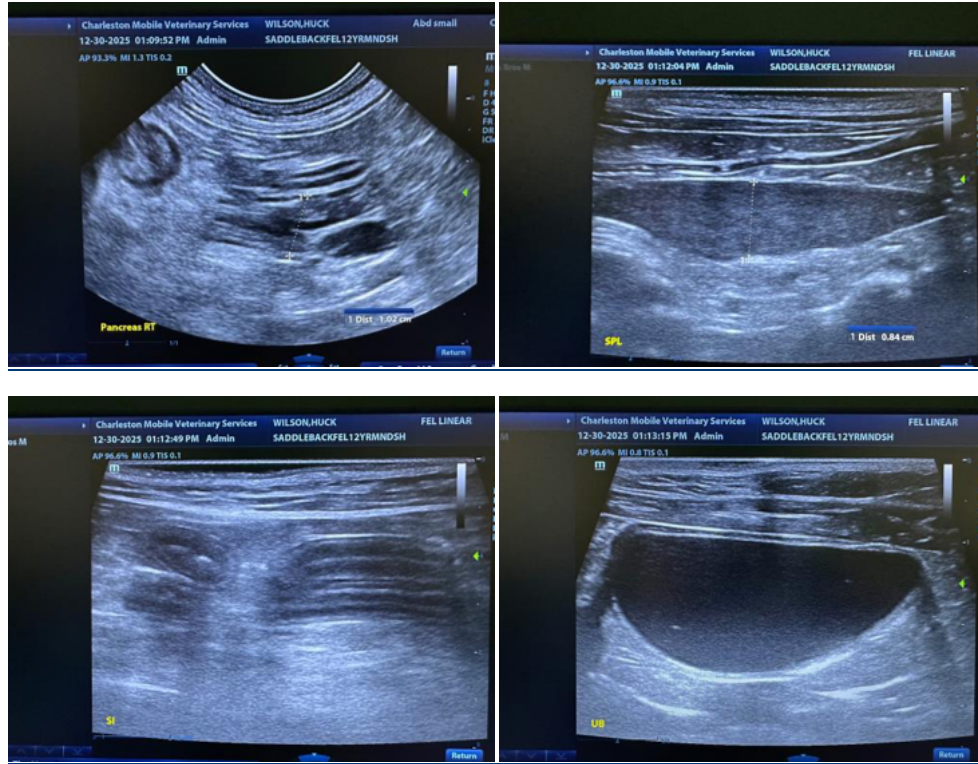
Dr. Klein

INVOICE

13360

DATE

12/30/25



The information and recommendations provided are based on the images presented by the referring veterinarian/sonographer. No evaluation can be communicated regarding pathology that was not visible in the image/video clips provided.

Thank you for this referral. If the clinical or image interpretation does not parallel your findings or if I can be of any further assistance please contact me.

Andrea Nicastro, MPH, DVM, Diplomate DACVIM (Small Animal Internal Medicine)
info@SonoPath.com