



PATIENT

Nini Garcia

SPECIES

Canine

BREED

Yorkshire
terrier/Chihuahua mix

SEX

Female, spayed

AGE

15 Yrs. 4 months

WEIGHT

PRESENTING CLINICAL SIGNS

Pt presented for recheck gallbladder due to developing mucocele.

ULTRASONOGRAPHIC EXAMINATION OF THE ABDOMEN

**This study was limited to the gallbladder and liver. There is a potential for pathology in organs that were not visualized.

Liver

The liver is subjectively prominent in size with smooth peripheral contours. The parenchyma is diffusely heterogeneous in appearance. No distinct focal lesions are observed. Vascular and biliary tracts are of normal volume with no evidence of congestion.

The gall bladder lumen is moderately distended. The wall is normal in thickness. A few polypoid like lesions are arising from the mucosal surface. A moderate amount of aggregated, echogenic, partially dependent to suspended sludge in a partially stellate pattern is observed within the lumen. The cystic and common bile ducts are normal/not seen.

INTERPRETED BY

Andrea Nicastro,
DVM, Diplomate
ACVIM (*Small Animal
Internal Medicine*)

**IMAGING
PERFORMED BY**

Andrea Nicastro,
DVM, Diplomate
ACVIM (*Small Animal
Internal Medicine*)

ULTRASONOGRAPHIC FINDINGS

- The gallbladder changes are consistent with a developing mucocele. Changes are similar to the previous sonogram.
- The hepatic changes are nonspecific and could be secondary to inflammatory disease (i.e., cholangiohepatitis, chronic hepatitis), hepatotoxicosis, infiltrative neoplasia (i.e., lymphoma), vacuolar hepatopathy, regenerative nodular hyperplasia, other hepatopathy, or some combination thereof. Changes are similar to the previous sonogram.

INTERPRETATION OF THE FINDINGS & FURTHER RECOMMENDATIONS

1. Continuation of Ursodiol therapy is recommended as well as a recheck ultrasound in 2-3 months to assess for progression to a fully formed mucocele.
2. Liver values should also be monitored every 3-4 months to assess for changes.

HOSPITAL NAME

Meadowlawn

REFERRING VET

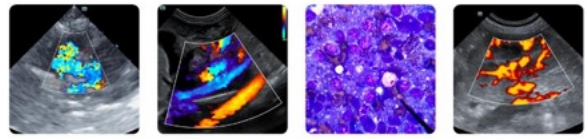
Dr. Clemons

INVOICE

13315

DATE

11/5/25



PATIENT

Nini Garcia

SPECIES

Canine

BREED

Yorkshire terrier/Chihuahua mix

SEX

Female, spayed

AGE

15 Yrs. 4 months

WEIGHT

INTERPRETED BY

Andrea Nicastro,
 DVM, Diplomate
 ACVIM (*Small Animal
 Internal Medicine*)

IMAGING PERFORMED BY

Andrea Nicastro,
 DVM, Diplomate
 ACVIM (*Small Animal
 Internal Medicine*)

HOSPITAL NAME

Meadowlawn

REFERRING VET

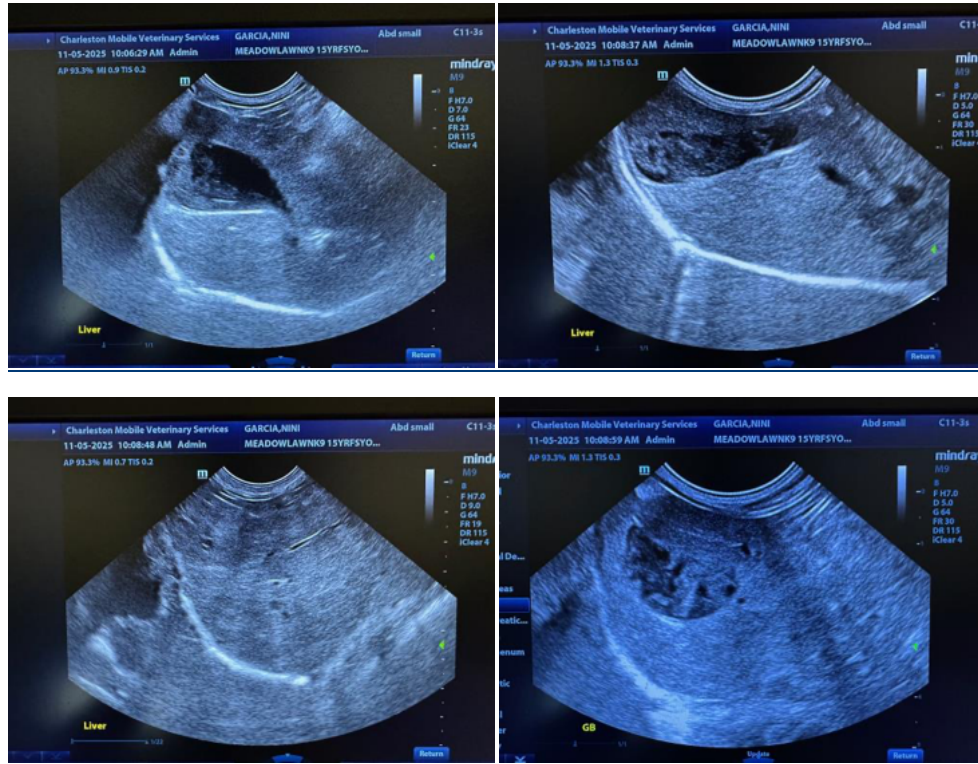
Dr. Clemons

INVOICE

13315

DATE

11/5/25



The information and recommendations provided are based on the images presented by the referring veterinarian/sonographer. No evaluation can be communicated regarding pathology that was not visible in the image/video clips provided.

Thank you for this referral. If the clinical or image interpretation does not parallel your findings or if I can be of any further assistance please contact me.

Andrea Nicastro, MPH, DVM, Diplomate DACVIM (Small Animal Internal Medicine)
info@SonoPath.com