

PATIENT

Ruby Baer

SPECIES

Feline

BREED

Domestic Shorthair

SEX

Male Neutered

AGE

3/14/19

WEIGHT

12 lbs

INTERPRETED BY

Andrea Nicastro, DVM,
Diplomate ACVIM
(Small Animal Internal
Medicine)

IMAGING PERFORMED BY

Andrea Nicastro, DVM,
Diplomate ACVIM
(Small Animal Internal
Medicine)

HOSPITAL NAME

Foxbank Veterinary
Hospital

REFERRING VET

Dr. Shannon

INVOICE

11974kk

DATE

10/8/21

PRESENTING CLINICAL SIGNS

History: Dehydration, QAR, doughy upon abdominal palpation. Had lameness issues as well.

Abnormal Lab Values: elevated BUN, GGT, lipase, decreased NaCl, neutrophilia, elevated Hct

Radiographic Findings: Ileus

ULTRASONOGRAPHIC EXAMINATION OF THE ABDOMEN

Urinary System

The urinary bladder, trigone, and pelvic urethra are normal in thickness and the mucosal surface is smooth. The bladder lumen is moderately distended with anechoic urine. No masses, inflammatory changes or calculi are observed. Ureteral papillae and visualized portion of the proximal urethra, visible to a depth of 2 cm, are normal.

The left kidney is normal size (4.14 cm in length); normal shape and architecture with smooth peripheral margins. There is a normal 1:3 cortex to medulla ratio with normal corticomedullary distinction. There is no evidence of pyelectasia, nephroliths, infarcts or hydronephrosis. Renal vasculature is normal.

The right kidney is normal size (4.39 cm in length) with a slightly irregular shape. A 2.24 cm anechoic cortical cyst is observed at the cranial aspect. The cyst causes distortion of the renal architecture in this region. In the remainder of the kidney, there is a normal 1:3 cortex to medulla ratio with normal corticomedullary distinction. There is no evidence of pyelectasia, nephroliths, infarcts or hydronephrosis. Renal vasculature is normal.

Adrenal Glands

The left adrenal gland is upper limits of normal size (0.54 cm width). Normal shape and glandular echogenicity. The phrenicoabdominal vein and surrounding vasculature are normal.

The right adrenal gland is upper limits of normal size (0.54 cm width). Normal shape and glandular echogenicity. The phrenicoabdominal vein and surrounding vasculature are normal.

Spleen

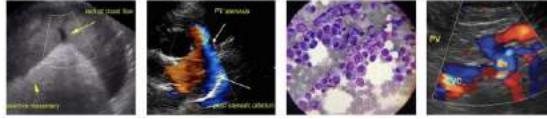
The spleen is normal in size (0.82 cm in width at the level of the hilus) with a normal capsular contour. There is appropriate echogenicity and echotexture. No focal lesions are observed. Splenic vasculature is normal.

Liver

The liver is subjectively enlarged with slightly swollen peripheral contours. The parenchyma is hyperechoic relative to the spleen and diffusely homogeneous in appearance. No distinct focal lesions are observed. Vascular and biliary tracts are of normal volume with no evidence of congestion. The gall bladder lumen is moderately distended. The wall is thin and smooth. Luminal contents are anechoic. The cystic and common bile ducts are normal.

Gastrointestinal

The gastric lumen is fluid-distended and hypomotile. The gastric wall and pylorus are normal in thickness with a normal layering pattern. The pyloric outflow tract is patent. The proximal duodenal lumen is moderately to severely fluid distended and hypomotile. At the level of the caudal duodenal flexure, a 1.61 cm irregular, hyperechoic, hard shadowing structure is visualized within the lumen. The



PATIENT

bowel wall in this region is thickened. The remaining small intestinal lumen is not dilated. The colonic wall is normal.

Ruby Baer

Pancreas

SPECIES

The pancreas is diffusely prominent in size with slightly irregular peripheral contours. The parenchyma is hypoechoic relative to surrounding omental fat. No distinct focal lesions are observed. The pancreatic duct is not overtly dilated. The mesentery effacing the serosal surface is slightly hyperechoic.

Feline

BREED

Free Abdomen

Domestic Shorthair

There is no evidence of free fluid. The abdominal lymph nodes are normal/not visible.

SEX

ULTRASONOGRAPHIC FINDINGS

Male Neutered

Primary Findings:

- Probable duodenal foreign body/obstruction.
- Moderate acute pancreatitis.

AGE

3/14/19

Secondary Findings:

- Right renal cyst - incidental.

WEIGHT

12 lbs

INTERPRETATION OF THE FINDINGS & FURTHER RECOMMENDATIONS

1. An abdominal exploratory is recommended to assess for and remove the duodenal foreign body.

INTERPRETED BY

Andrea Nicastro, DVM,
Diplomate ACVIM
(Small Animal Internal
Medicine)

IMAGING PERFORMED BY

Andrea Nicastro, DVM,
Diplomate ACVIM
(Small Animal Internal
Medicine)

HOSPITAL NAME

Foxbank Veterinary
Hospital

REFERRING VET

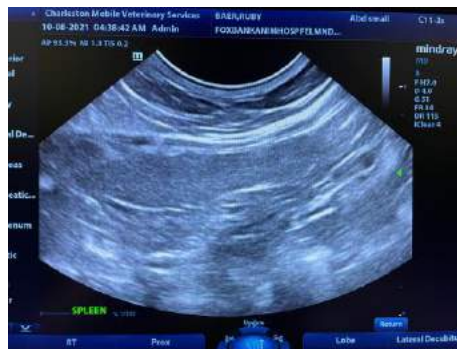
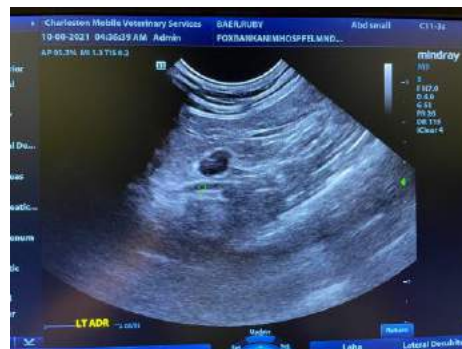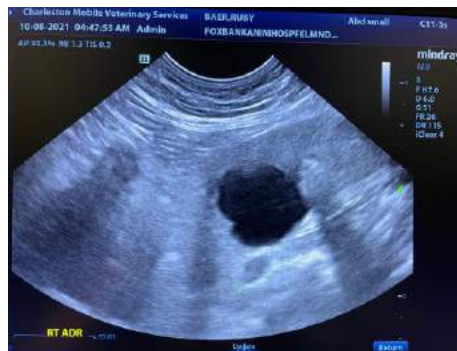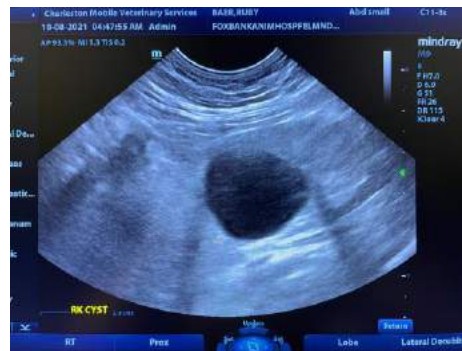Dr. Shannon

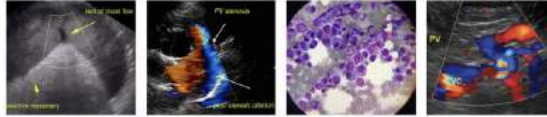
INVOICE

11974kk

DATE

10/8/21





PATIENT

Ruby Baer

SPECIES

Feline

BREED

Domestic Shorthair

SEX

Male Neutered

AGE

3/14/19

WEIGHT

12 lbs

INTERPRETED BY

Andrea Nicastro, DVM,
Diplomate ACVIM
(Small Animal Internal
Medicine)

IMAGING PERFORMED BY

Andrea Nicastro, DVM,
Diplomate ACVIM
(Small Animal Internal
Medicine)

HOSPITAL NAME

Foxbank Veterinary
Hospital

REFERRING VET

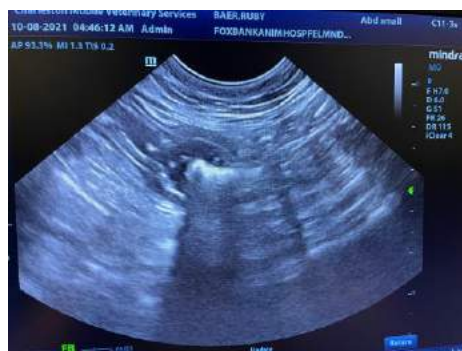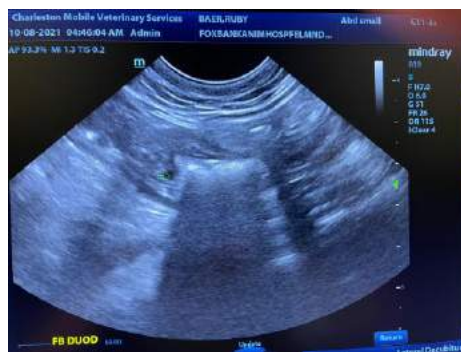
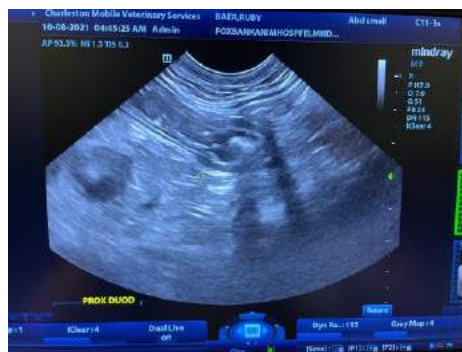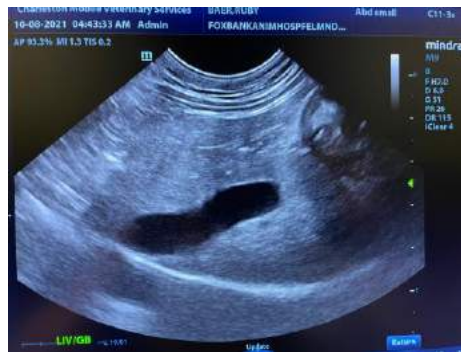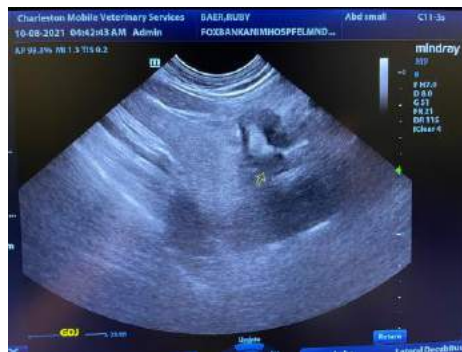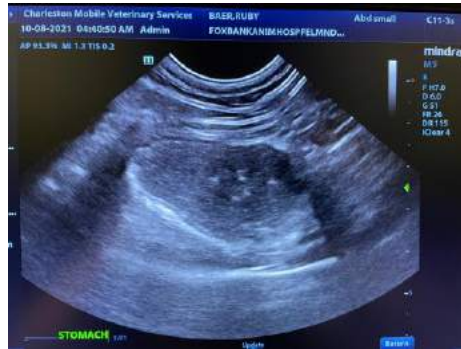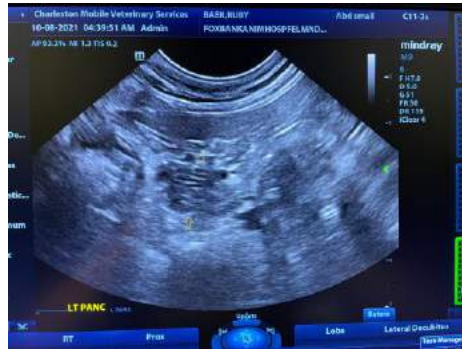Dr. Shannon

INVOICE

11974kk

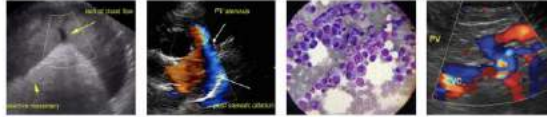
DATE

10/8/21



The information and recommendations provided are based on the images presented by the referring veterinarian. No evaluation can be communicated regarding pathology that was not visible in the image/video clips provided.

Thank you for this referral. If the clinical or image interpretation does not parallel your findings or if I



PATIENT

can be of any further assistance, please contact me.

Ruby Baer

Andrea Nicastro, DVM, Diplomate ACVIM (*Small Animal Internal Medicine*)
Andrea.Nicastro@CharlestonMobile.net

SPECIES

Feline

BREED

Domestic Shorthair

SEX

Male Neutered

AGE

3/14/19

WEIGHT

12 lbs

INTERPRETED BY

Andrea Nicastro, DVM,
Diplomate ACVIM
(*Small Animal Internal
Medicine*)

**IMAGING
PERFORMED BY**

Andrea Nicastro, DVM,
Diplomate ACVIM
(*Small Animal Internal
Medicine*)

HOSPITAL NAME

Foxbank Veterinary
Hospital

REFERRING VET

Dr. Shannon

INVOICE

11974kk

DATE

10/8/21