

PATIENT

Tessa Williams

SPECIES

Canine

BREED

Boykin spaniel

SEX

Female, spayed

AGE

4/14/18

WEIGHT

33 lbs.

INTERPRETED BY

Andrea Nicastro, DVM,
Diplomate ACVIM
(*Small Animal Internal
Medicine*)

**IMAGING
PERFORMED BY**

Andrea Nicastro, DVM,
Diplomate ACVIM
(*Small Animal Internal
Medicine*)

HOSPITAL NAME

Flowertown

REFERRING VET

Dr. Kline

INVOICE

14496

DATE

1/24/23

PRESENTING CLINICAL SIGNS

2-day history of anorexia and lethargy.

ULTRASONOGRAPHIC EXAMINATION OF THE ABDOMEN

Urinary System

The urinary bladder wall is normal in thickness and the mucosal surface is smooth. The bladder lumen is moderately distended with anechoic urine. No masses, inflammatory changes or calculi are observed. Ureteral papillae and visualized portion of the proximal urethra, visible to a depth of 3-4 cm, are normal.

The left kidney is normal size (4.98 cm in length); normal shape and architecture with smooth peripheral margins. There is a normal 1:3 cortex to medulla ratio with normal corticomedullary distinction. There is no evidence of pyelectasia, nephroliths, infarcts or hydronephrosis. Renal vasculature is normal.

The right kidney is normal size (5.36 cm in length); normal shape and architecture with smooth peripheral margins. There is a normal 1:3 cortex to medulla ratio with normal corticomedullary distinction. There is no evidence of pyelectasia, nephroliths, infarcts or hydronephrosis. Renal vasculature is normal.

Adrenal Glands

The left adrenal gland is normal size (0.46 cm at cranial pole) (0.53 cm at caudal pole) (1.99 cm in length); normal shape; homogenous parenchyma. The glandular echogenicity and detail are unremarkable. Capsule, cortex, and medullary definition are normal. The phrenicoabdominal vein and surrounding vasculature are normal.

The right adrenal gland is normal size (0.76 cm at cranial pole) (0.76 cm at caudal pole); normal shape; homogenous parenchyma. The glandular echogenicity and detail are unremarkable. Capsule, cortex, and medullary definition are normal. The phrenicoabdominal vein and surrounding vasculature are normal.

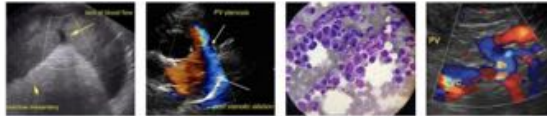
Spleen

The spleen is normal in size (1.69 cm in width at the level of the hilus) with a normal capsular contour. There is appropriate echogenicity and echotexture. No focal lesions are observed. Splenic vasculature is normal.

Liver

The liver is subjectively normal in size with normal contours and structure. There is appropriate echogenicity and echotexture. No overt structural evidence of inflammatory, infiltrative or regenerative pathology is evident. Vascular and biliary tracts are of normal volume with no evidence of congestion. No pathological hepatic lymphadenopathy observed. The portal vein to caudal vena cava ratio is approximately 1:1. The gall bladder lumen is moderately distended. The wall is thin and smooth. A moderate amount of aggregated, echogenic, partially dependent debris/sludge is observed within the lumen. The cystic and common bile ducts are normal/not seen.

Gastrointestinal



PATIENT

Tessa Williams

SPECIES

Canine

BREED

Boykin spaniel

SEX

Female, spayed

AGE

4/14/18

WEIGHT

33 lbs.

INTERPRETED BY

Andrea Nicastro, DVM,
Diplomate ACVIM
(*Small Animal Internal
Medicine*)

**IMAGING
PERFORMED BY**

Andrea Nicastro, DVM,
Diplomate ACVIM
(*Small Animal Internal
Medicine*)

HOSPITAL NAME

Flowertown

REFERRING VET

Dr. Kline

INVOICE

14496

DATE

1/24/23

The stomach and intestine are free of stasis and exhibit normal peristaltic activity. The gastric lumen is mildly distended with ingesta and soft shadowing material. The gastric wall and pylorus are normal in thickness with a normal layering pattern. The pyloric outflow tract is patent. The small intestinal lumen is not dilated. The small intestinal wall thickness is normal with a normal layering pattern and appropriate mural detail. Discreet masses are not identified. The colonic wall is normal. No obstructive disease is noted.

Pancreas

The region of the pancreas is isoechoic relative to surrounding omental fat. No obvious parenchymal abnormalities are observed. There is no evidence of regional inflammation or effusion.

Free Abdomen

The peritoneal cavity is normal. There is no evidence of inflammation or effusion. The abdominal lymph nodes are normal/not visible.

Other

A brief echocardiogram reveals no evidence of pericardial effusion or obvious right atrial/auricular mass.

ULTRASONOGRAPHIC FINDINGS

- The shadowing material within the gastric lumen may represent foreign material (i.e., grass, other) vs normal ingesta. It appears non-obstructive at the time of the study. The remainder of the abdomen is unremarkable.

*Based on the patient's clinical history, immune mediated hemolytic anemia (i.e., primary vs secondary) is the top differential.

INTERPRETATION OF THE FINDINGS & FURTHER RECOMMENDATIONS

Consider the following:

1. Three-view thoracic radiographs to assess for occult neoplasia in the chest.
2. A comprehensive tick panel, including PCR and serology (submission to North Carolina State University's Vector Borne Disease Diagnostic Lab) is recommended. <https://cvm.ncsu.edu/research/labs/clinical-sciences/vector-borne-disease/>.
3. Supportive care for immune mediate hemolytic anemia (i.e., blood transfusion, immunosuppressants, and other symptomatic treatment). Also consider initiation of Doxycycline as empirical treatment for tick borne disease.



PATIENT

Tessa Williams

SPECIES

Canine

BREED

Boykin spaniel

SEX

Female, spayed

AGE

4/14/18

WEIGHT

33 lbs.

INTERPRETED BY

Andrea Nicastro, DVM,
Diplomate ACVIM
(Small Animal Internal
Medicine)

IMAGING PERFORMED BY

Andrea Nicastro, DVM,
Diplomate ACVIM
(Small Animal Internal
Medicine)

HOSPITAL NAME

Flowertown

REFERRING VET

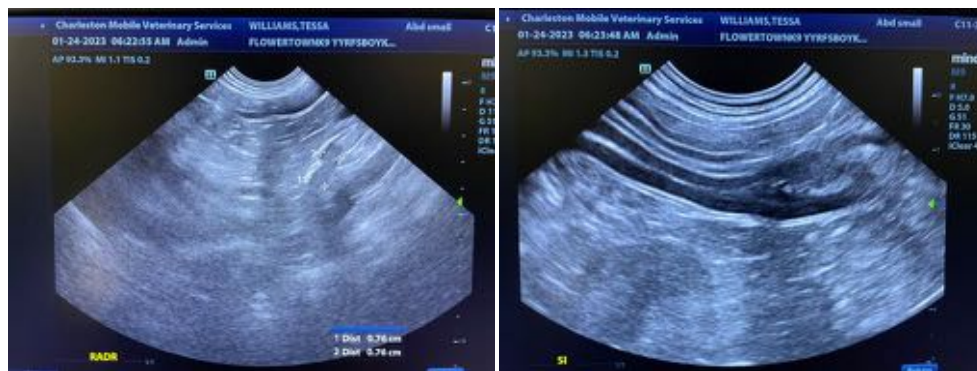
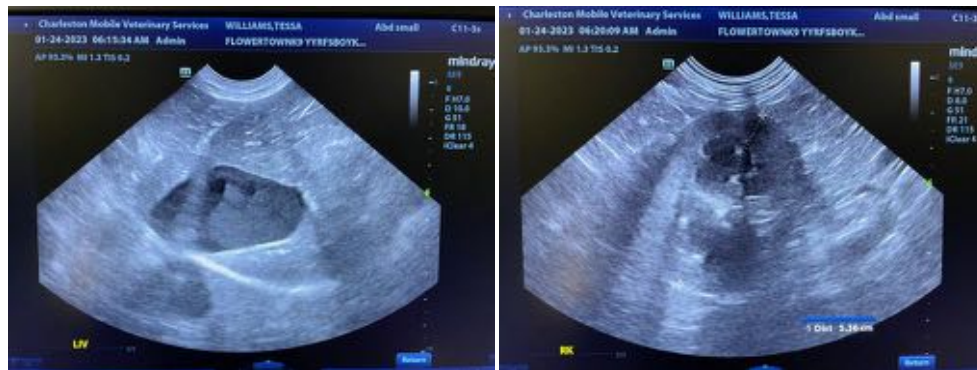
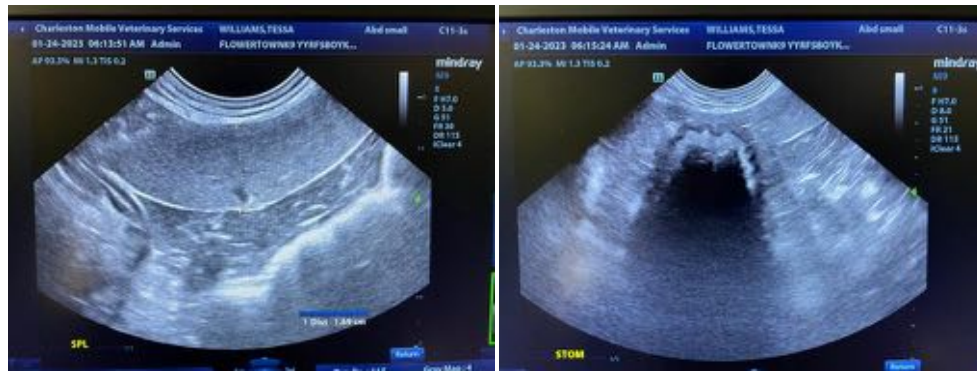
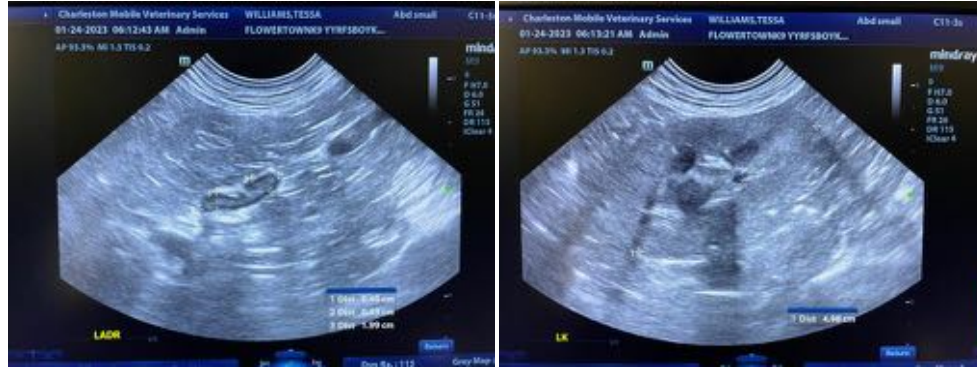
Dr. Kline

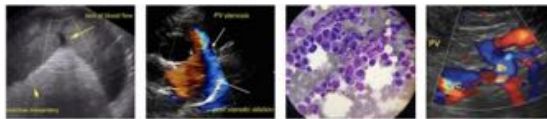
INVOICE

14496

DATE

1/24/23





PATIENT

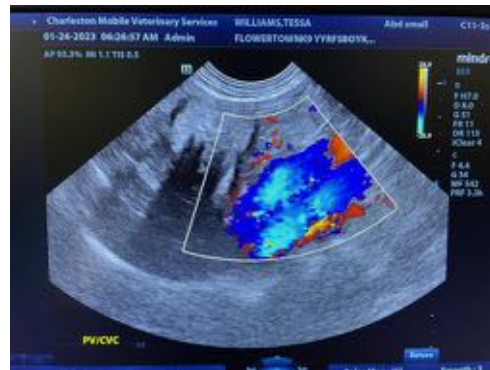
Tessa Williams

SPECIES

Canine

BREED

Boykin spaniel



SEX

Female, spayed

The information and recommendations provided are based on the images presented by the referring veterinarian/sonographer. No evaluation can be communicated regarding pathology that was not visible in the image/video clips provided.

AGE

4/14/18

Thank you for this referral. If the clinical or image interpretation does not parallel your findings or if I can be of any further assistance please contact me.

WEIGHT

33 lbs.

Andrea Nicastro, MPH, DVM, Diplomate DACVIM (Small Animal Internal Medicine)
info@SonoPath.com

INTERPRETED BY

Andrea Nicastro, DVM,
Diplomate ACVIM
(*Small Animal Internal
Medicine*)

**IMAGING
PERFORMED BY**

Andrea Nicastro, DVM,
Diplomate ACVIM
(*Small Animal Internal
Medicine*)

HOSPITAL NAME

Flowertown

REFERRING VET

Dr. Kline

INVOICE

14496

DATE

1/24/23