

PATIENT

Pip Maginnis

SPECIES

Feline

BREED

Domestic shorthair

SEX

Male, neutered

AGE

7/1/2015

WEIGHT

4.3 kg.

INTERPRETED BY

Andrea Nicastro, DVM,
 Diplomate ACVIM
 (Small Animal Internal
 Medicine)

IMAGING PERFORMED BY

Andrea Nicastro, DVM,
 Diplomate ACVIM
 (Small Animal Internal
 Medicine)

HOSPITAL NAME

Sun Dog Cat Moon

REFERRING VET

Dr. Fetterolf

INVOICE

13397

DATE

1/20/26

PRESENTING CLINICAL SIGNS

Patient History:

- Last seen for annual integrative wellness visit on 2-5-25 (4.94 kg)
- Previous exam revealed gingival arthritis but appeared healthy otherwise
- Senior wellness panel performed at previous visit was unremarkable
- T4: 1.9 (from previous visit)
- Urine not obtained at previous visit
- Recent behavioral changes: counter surfing and increased food-seeking behavior
- Eating rapidly and consuming other cat's food
- Occasional vomiting but no diarrhea
- New kitten added to household
- Weight gain initially when kitten arrived, then subsequent weight loss
- Client reports back end appears bonier than previously
- Primarily indoor cat with occasional escapes

Moderate gingival inflammation. MM loss over caudal dorsum.

ULTRASONOGRAPHIC EXAMINATION OF THE ABDOMEN

Urinary System

The urinary bladder wall is normal in thickness and the mucosal surface is smooth. The bladder is moderately distended. Luminal contents are mostly anechoic. No cystic calculi are observed. The region of the trigone and the visible portion of the proximal urethra are normal.

The left kidney is normal in size (4.20 cm in length) with a normal shape, architecture and smooth peripheral margins. There is a normal 1:3 cortex to medulla ratio with mild loss of corticomedullary distinction. There is no evidence of pyelectasia, nephroliths, infarcts or hydroureter. Renal vasculature is normal.

The right kidney is normal in size (4.42 cm in length) with a normal shape, architecture and smooth peripheral margins. There is a normal 1:3 cortex to medulla ratio with mild loss of corticomedullary distinction. There is no evidence of pyelectasia, nephroliths, infarcts or hydroureter. Renal vasculature is normal.

Adrenal Glands

The left adrenal gland is normal size (0.35 cm width). Normal shape and glandular echogenicity. The phrenicoabdominal vein and surrounding vasculature are normal.

The right adrenal gland is normal size (0.47 cm width). Normal shape and glandular echogenicity. The phrenicoabdominal vein and surrounding vasculature are normal.

Spleen

The spleen is normal in size (0.67 cm in width at the level of the hilus) with a normal capsular contour. There is appropriate echogenicity and echotexture. No focal lesions are observed. Splenic vasculature is normal.

Liver

The liver is subjectively normal in size with normal curvilinear peripheral contours. The parenchyma is isoechoic relative to the spleen and diffusely homogeneous in appearance. No distinct focal lesions are observed. Vascular and biliary tracts are of normal volume with no evidence of congestion. The portal vein to caudal vena cava ratio is approximately 1:1.



PATIENT

Pip Maginnis

SPECIES

Feline

BREED

Domestic shorthair

SEX

Male, neutered

AGE

7/1/2015

WEIGHT

4.3 kg.

INTERPRETED BY

Andrea Nicastro, DVM,
Diplomate ACVIM
(Small Animal Internal
Medicine)

**IMAGING
PERFORMED BY**

Andrea Nicastro, DVM,
Diplomate ACVIM
(Small Animal Internal
Medicine)

HOSPITAL NAME

Sun Dog Cat Moon

REFERRING VET

Dr. Fetterolf

INVOICE

13397

DATE

1/20/26

The gall bladder lumen is moderately distended. The wall is thin and smooth. Luminal contents are mostly anechoic. The cystic and common bile ducts are normal/not seen.

Gastrointestinal

The stomach and intestine are free of stasis and exhibit normal peristaltic activity. The gastric lumen is not distended. The gastric wall and pylorus are normal in thickness with a normal layering pattern. The pyloric outflow tract is patent. The small intestinal lumen is not dilated. The small intestinal wall thickness is normal. There is disruption in the normal 1:3 muscularis: mucosal ratio in most segments. Discreet masses are not identified. The ileocecal colic junction and colonic wall are normal. No obstructive disease is noted.

Pancreas

The pancreas is normal in size with normal peripheral contours. The pancreatic duct is normal. The base and limbs of the pancreas are isoechoic to surrounding omental fat. No focal lesions are observed. There is no evidence of peripancreatic inflammation or effusion.

Lymph nodes

The abdominal lymph nodes are normal/not visible.

Free Abdomen

The peritoneal cavity is normal. There is no evidence of inflammation or effusion.

Other

A brief echocardiogram reveals no evidence of pericardial effusion or obvious right atrial/auricular mass.

ULTRASONOGRAPHIC FINDINGS

Primary Findings:

- The small intestinal wall changes are suggestive of inflammatory bowel disease, however emerging lymphoma cannot be completely excluded.

Secondary Findings:

- Bilateral nonspecific, age-related renal changes.

INTERPRETATION OF THE FINDINGS & FURTHER RECOMMENDATIONS

1. A fecal evaluation for ova and Giardia along with a GI panel including serum cobalamin, folate, TLI and PLI are recommended.
2. Consider transitioning to a limited antigen or hydrolyzed protein diet.
3. Ultimately, endoscopic or surgical GI biopsies may be necessary to get a definitive diagnosis.



PATIENT

Pip Maginnis

SPECIES

Feline

BREED

Domestic shorthair

SEX

Male, neutered

AGE

7/1/2015

WEIGHT

4.3 kg.

INTERPRETED BY

Andrea Nicastro, DVM,
 Diplomate ACVIM
 (Small Animal Internal
 Medicine)

**IMAGING
 PERFORMED BY**

Andrea Nicastro, DVM,
 Diplomate ACVIM
 (Small Animal Internal
 Medicine)

HOSPITAL NAME

Sun Dog Cat Moon

REFERRING VET

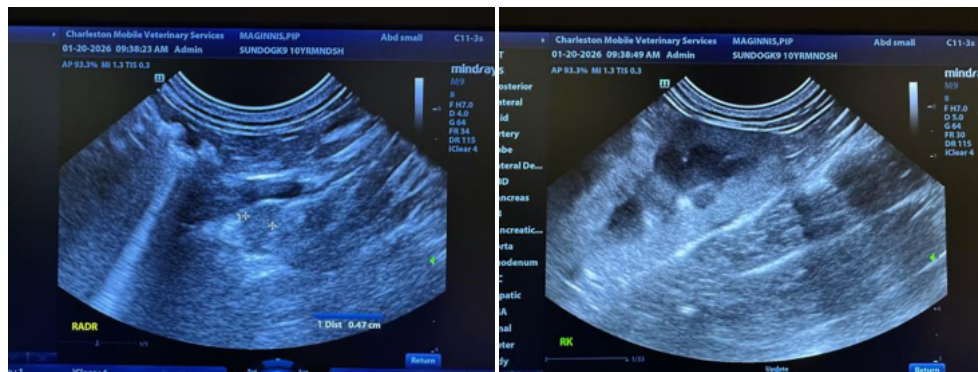
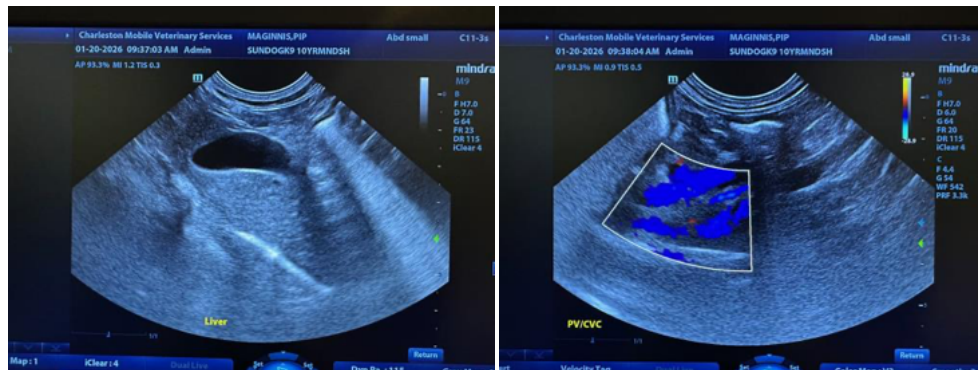
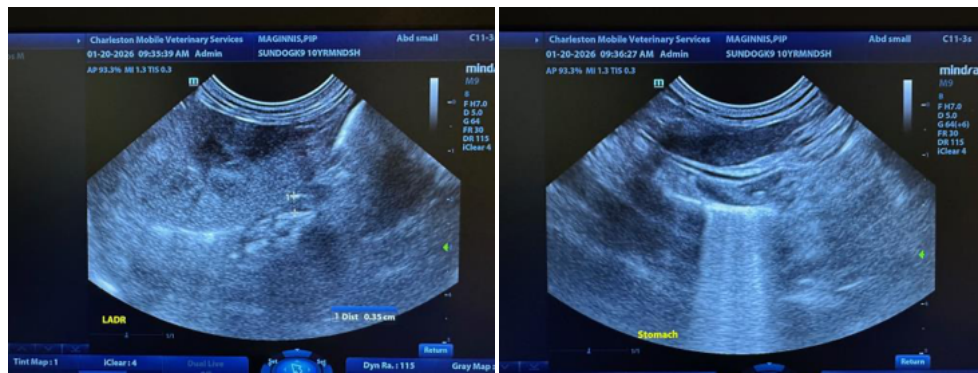
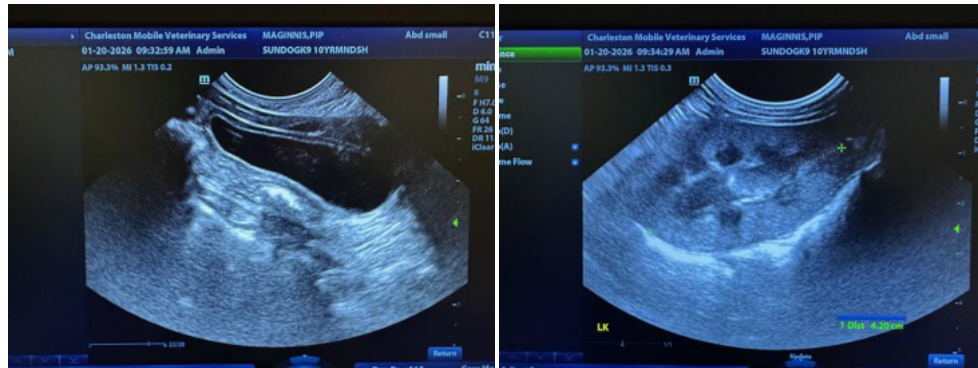
Dr. Fetterolf

INVOICE

13397

DATE

1/20/26





PATIENT

Pip Maginnis

SPECIES

Feline

BREED

Domestic shorthair

SEX

Male, neutered

AGE

7/1/2015

WEIGHT

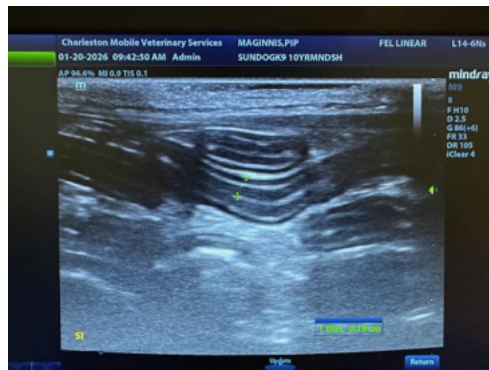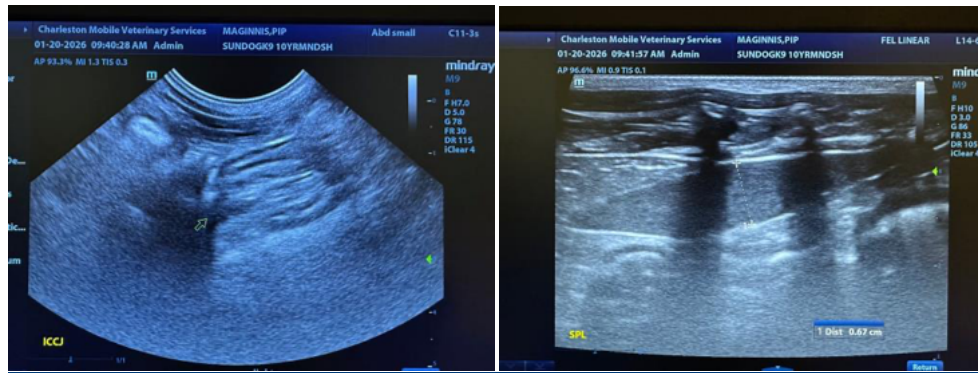
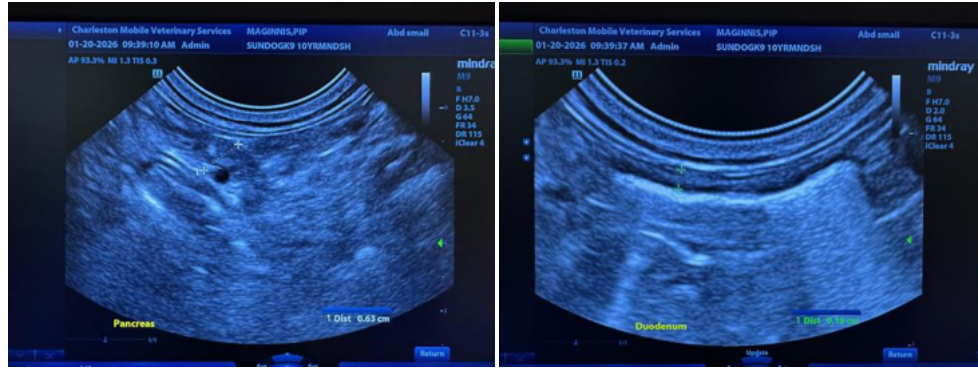
4.3 kg.

INTERPRETED BY

Andrea Nicastro, DVM,
 Diplomate ACVIM
 (Small Animal Internal
 Medicine)

IMAGING PERFORMED BY

Andrea Nicastro, DVM,
 Diplomate ACVIM
 (Small Animal Internal
 Medicine)



HOSPITAL NAME

Sun Dog Cat Moon

REFERRING VET

Dr. Fetterolf

INVOICE

13397

DATE

1/20/26

The information and recommendations provided are based on the images presented by the referring veterinarian/sonographer. No evaluation can be communicated regarding pathology that was not visible in the image/video clips provided.

Thank you for this referral. If the clinical or image interpretation does not parallel your findings or if I can be of any further assistance please contact me.

Andrea Nicastro, MPH, DVM, Diplomate DACVIM (Small Animal Internal Medicine)
info@SonoPath.com