



PATIENT

Dior Cooper

SPECIES

Canine

BREED

Poodle

SEX

Female, spayed

AGE

5/10/2015

WEIGHT

8 lbs.

INTERPRETED BY

Andrea Nicastro, DVM,
Diplomate ACVIM
(Small Animal Internal
Medicine)

**IMAGING
PERFORMED BY**

Andrea Nicastro, DVM,
Diplomate ACVIM
(Small Animal Internal
Medicine)

HOSPITAL NAME

VC of Myrtle Beach

REFERRING VET

Dr. Boland

INVOICE

13387

DATE

1/14/26

PRESENTING CLINICAL SIGNS

Presented 12/17/25 for inappetence and urinary accidents
H/o heart murmur - increased from grade 2/6 on 2/2025 to a grade 4/6 on 12/17/25. Blood pressures today ranged from 111-171 MAP.

Labs: Albumin = 2.4, BUN = 71, Creat = 1.3, SDMA = 23.5
(previous labs 10/2/25 BUN 47, Creat 0.8, SDMA 14.6; and 7/17/25 BUN = 51, Creat 0.8, SDMA 14.3), all other chems and cbc wnl. HWT/tick panel negative.

ULTRASONOGRAPHIC EXAMINATION OF THE ABDOMEN

Urinary System

The urinary bladder wall is normal in thickness and the mucosal surface is smooth. The bladder is moderately distended. Luminal contents are anechoic. No cystic calculi are observed. The region of the trigone is normal.

The left kidney is normal in size (3.73 cm in length) with a normal shape, architecture and smooth peripheral margins. There is a normal 1:3 cortex to medulla ratio with mild loss of corticomedullary distinction. Mild pyelectasia is present (0.22 cm in the longitudinal plane). There is no evidence of nephroliths, infarcts or hydroureter. Renal vasculature is normal.

The right kidney is normal in size (3.58 cm in length) with a normal shape, architecture and smooth peripheral margins. There is a normal 1:3 cortex to medulla ratio with mild loss of corticomedullary distinction. Mild pyelectasia is present (0.29 cm in the longitudinal plane). There is no evidence of nephroliths, infarcts or hydroureter. Renal vasculature is normal.

Adrenal Glands

The left adrenal gland is normal in size (0.42 cm at cranial pole) (0.41 cm at caudal pole) with a normal shape and homogenous parenchyma. The glandular echogenicity and detail are unremarkable. Capsule, cortex, and medullary definition are normal. The phrenicoabdominal vein and surrounding vasculature are normal.

The right adrenal gland is normal in size (0.84 cm at cranial pole) (0.41 cm at caudal pole) with a normal shape and homogenous parenchyma. The glandular echogenicity and detail are unremarkable. Capsule, cortex, and medullary definition are normal. The phrenicoabdominal vein and surrounding vasculature are normal.

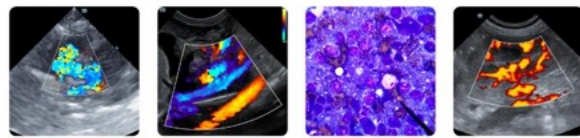
Spleen

The spleen is normal in size (1.15 cm in width at the level of the hilus) with a normal capsular contour. There is appropriate echogenicity and echotexture. No focal lesions are observed. Splenic vasculature is normal.

Liver

The liver is subjectively normal in size with normal contours and structure. There is appropriate echogenicity and echotexture. No overt structural evidence of inflammatory, infiltrative, or regenerative pathology is evident. Vascular and biliary tracts are of normal volume with no evidence of congestion. The portal vein to caudal vena cava ratio is approximately 1:1.

The gall bladder lumen is moderately distended. The wall is thin and smooth. A small to moderate amount of mobile echogenic to mineralized debris/sand is observed within the lumen. The cystic and common bile ducts are normal/not seen.



PATIENT

Dior Cooper

SPECIES

Canine

BREED

Poodle

SEX

Female, spayed

AGE

5/10/2015

WEIGHT

8 lbs.

INTERPRETED BY

Andrea Nicastro, DVM,
 Diplomate ACVIM
 (Small Animal Internal
 Medicine)

IMAGING PERFORMED BY

Andrea Nicastro, DVM,
 Diplomate ACVIM
 (Small Animal Internal
 Medicine)

HOSPITAL NAME

VC of Myrtle Beach

REFERRING VET

Dr. Boland

INVOICE

13387

DATE

1/14/26

Gastrointestinal

The gastric lumen is not distended. The gastric wall and pylorus are normal in thickness with a normal layering pattern. The pyloric outflow tract is patent. The small intestinal lumen is not dilated. The small intestinal wall is normal in thickness with a normal layering pattern and appropriate mural detail. Discreet masses are not identified. The ileocecolic junction and colonic wall are normal. The colonic lumen contains some shadowing fecal material. There is no obvious evidence of an obstructive pattern.

Pancreas

The right limb of the pancreas is visible with normal curvilinear peripheral contours. The parenchyma is largely isoechoic relative to surrounding omental fat and slightly mottled in appearance. The pancreatic duct is visible but not overtly dilated. There is no evidence of peripancreatic inflammation or effusion.

Lymph nodes

The abdominal lymph nodes are normal/not visible.

Free Abdomen

There is no obvious evidence of free fluid.

Other

A brief echocardiogram reveals no evidence of pericardial effusion or obvious right atrial/auricular mass.

ULTRASONOGRAPHIC FINDINGS

Primary Findings:

- Bilateral nonspecific chronic renal changes. The bilateral pyelectasia may be secondary to pyelonephritis, parenchymal remodeling, PU/PD (if applicable) or some combination thereof.

Secondary Findings:

- Gallbladder debris/sand, non-mucocele
- The pancreatic changes are most consistent with age-related parenchymal remodeling, potentially secondary to a prior inflammatory episode, early fibrosis or chronic pancreatitis.

INTERPRETATION OF THE FINDINGS & FURTHER RECOMMENDATIONS

- Given the azotemia, consider the following:
 1. Urinalysis with culture and sensitivity
 2. UPC (if proteinuria is present in the absence of infection)
 3. A resting cortisol level to screen for hypoadrenocorticism. If resting cortisol level is < 2.0 mcg/dL, an ACTH stimulation test is recommended
 4. Transition to a prescription renal diet (if the patient will tolerate it)
 5. Serial monitoring of the patient's renal values to assess progression of the azotemia
- Regarding the hypoalbuminemia, if significant proteinuria is not present, consider further evaluation for possible underlying etiologies. Diagnostics could include the following:
 1. Resting cortisol level (as stated above)
 2. Pre and post-prandial serum bile acids
 3. Fecal evaluation for ova and Giardia
 4. +/- endoscopic or surgical GI biopsies (if indicated)



PATIENT

Dior Cooper

SPECIES

Canine

BREED

Poodle

SEX

Female, spayed

AGE

5/10/2015

WEIGHT

8 lbs.

INTERPRETED BY

Andrea Nicastro, DVM,
 Diplomate ACVIM
 (Small Animal Internal
 Medicine)

IMAGING PERFORMED BY

Andrea Nicastro, DVM,
 Diplomate ACVIM
 (Small Animal Internal
 Medicine)

HOSPITAL NAME

VC of Myrtle Beach

REFERRING VET

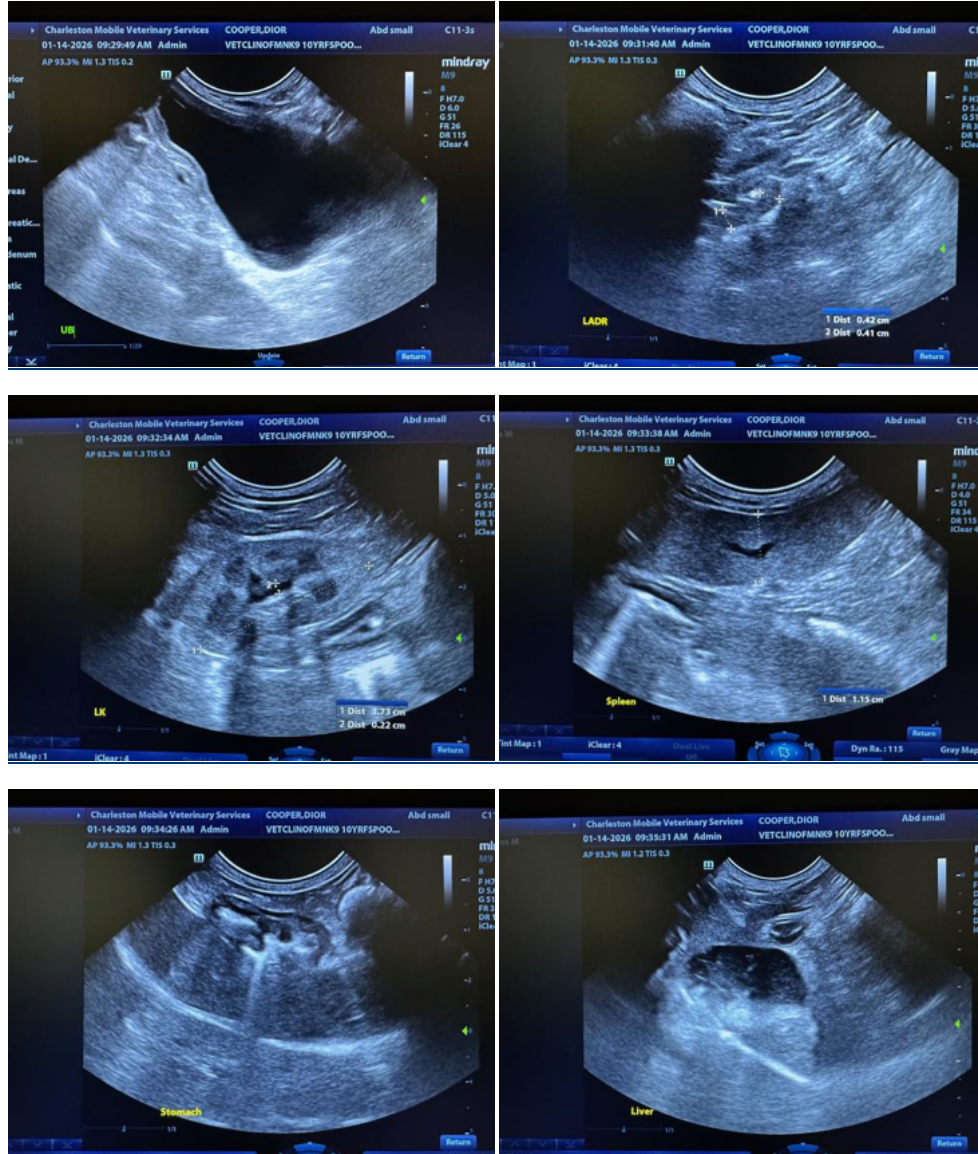
Dr. Boland

INVOICE

13387

DATE

1/14/26





PATIENT

Dior Cooper

SPECIES

Canine

BREED

Poodle

SEX

Female, spayed

AGE

5/10/2015

WEIGHT

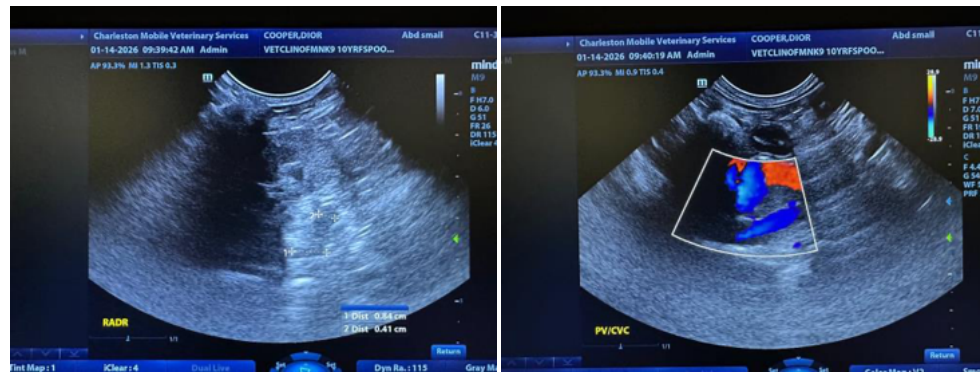
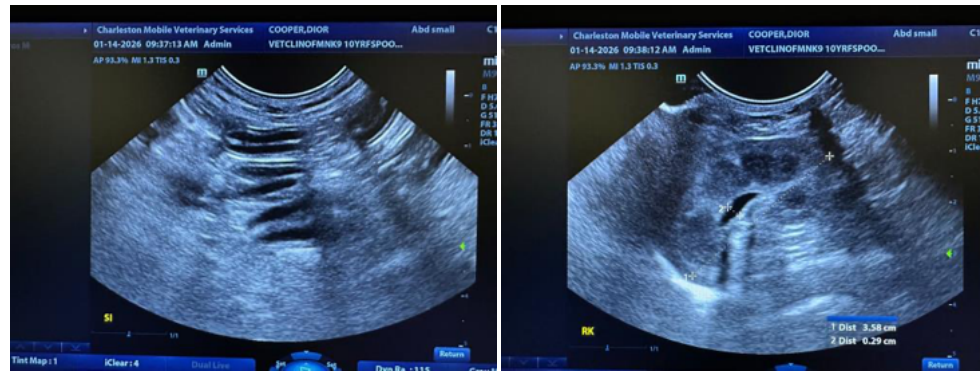
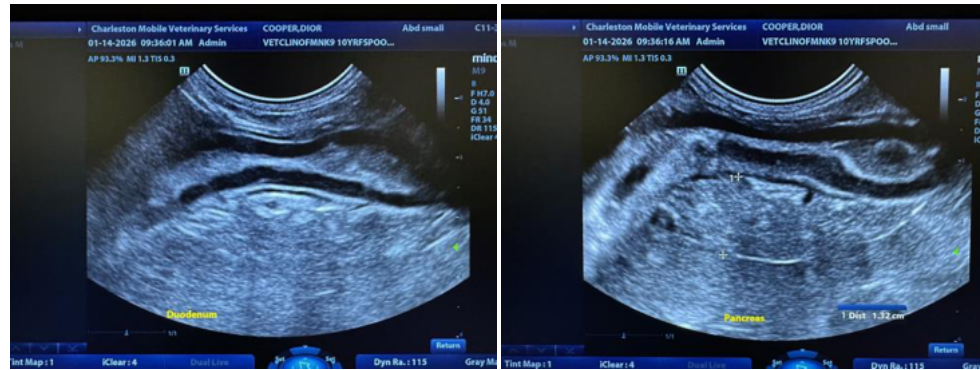
8 lbs.

INTERPRETED BY

Andrea Nicastro, DVM,
 Diplomate ACVIM
 (Small Animal Internal
 Medicine)

**IMAGING
 PERFORMED BY**

Andrea Nicastro, DVM,
 Diplomate ACVIM
 (Small Animal Internal
 Medicine)



HOSPITAL NAME

VC of Myrtle Beach

REFERRING VET

Dr. Boland

INVOICE

13387

DATE

1/14/26

The information and recommendations provided are based on the images presented by the referring veterinarian/sonographer. No evaluation can be communicated regarding pathology that was not visible in the image/video clips provided.

Thank you for this referral. If the clinical or image interpretation does not parallel your findings or if I can be of any further assistance please contact me.

Andrea Nicastro, MPH, DVM, Diplomate DACVIM (Small Animal Internal Medicine)
info@SonoPath.com