



PATIENT

Ellie Fettig

SPECIES

Canine

BREED

Yorkshire terrier mix

SEX

Female, spayed

AGE

8 Yrs.

WEIGHT

5.38 lbs.

INTERPRETED BY

Andrea Nicastro, DVM,
Diplomate ACVIM
(Small Animal Internal
Medicine)

**IMAGING
PERFORMED BY**

Jenna Walsh

HOSPITAL NAME

Companion Pet Clinic

REFERRING VET

Dr. Mills

DATE

9/12/22

INVOICE

13939

PRESENTING CLINICAL SIGNS

History: Pet asymptomatic. Current Medications Gabapentin, Denamarin advanced Primary Question/Differential to Be Answered in This Exam Reason for elevated ALT
Abnormal PE/Chem/CBC/UA Results: ALT 233

ULTRASONOGRAPHIC EXAMINATION OF THE ABDOMEN

Urinary System

The urinary bladder wall is normal in thickness and the mucosal surface is smooth. The bladder lumen is moderately distended with mostly anechoic urine. No masses, inflammatory changes or calculi are observed. The region of the trigone and the visible portion of the proximal urethra are normal.

The left kidney is normal size (3.12 cm in length); normal shape and architecture with smooth peripheral margins. There is a normal 1:3 cortex to medulla ratio with minimal loss of corticomedullary distinction. There is no evidence of pyelectasia, nephroliths, infarcts or hydroureter. Renal vasculature is normal.

The right kidney is normal size (3.34 cm in length); normal shape and architecture with smooth peripheral margins. There is a normal 1:3 cortex to medulla ratio with minimal loss of corticomedullary distinction. There is no evidence of pyelectasia, nephroliths, infarcts or hydroureter. Renal vasculature is normal.

Adrenal Glands

The left adrenal gland is normal size (0.35 cm at cranial pole) (0.40 cm at caudal pole) (1.48 cm in length); normal shape; homogenous parenchyma. The glandular echogenicity and detail are unremarkable. Capsule, cortex, and medullary definition are normal. The phrenicoabdominal vein and surrounding vasculature are normal.

The right adrenal gland is mildly enlarged (0.92 cm at cranial pole) (0.63 cm at caudal pole) (1.70 cm in length); normal shape; homogenous parenchyma. The glandular echogenicity and detail are unremarkable. Capsule, cortex, and medullary definition are normal. The phrenicoabdominal vein and surrounding vasculature are normal.

Spleen

The spleen is normal in size (0.95 cm in width at the level of the hilus) with a normal capsular contour. There is appropriate echogenicity and echotexture. No focal lesions are observed. Splenic vasculature is normal.

Liver

The liver is subjectively normal in size with normal contours and structure. There is appropriate echogenicity and echotexture. No overt structural evidence of inflammatory, infiltrative or regenerative pathology is evident. Vascular and biliary tracts are of normal volume with no evidence of congestion. No pathological hepatic lymphadenopathy observed. The portal vein: caudal vena cava ratio is approximately 1:1. The gall bladder lumen is moderately distended. The wall is thin and smooth. Luminal contents are anechoic. The cystic and common bile ducts are normal/not seen.

Gastrointestinal



PATIENT

Ellie Fettig

The gastric lumen is not distended. The gastric wall is normal in thickness with a normal layering pattern. The small intestinal lumen is not dilated. The small intestinal wall thickness is normal with a normal layering pattern and appropriate mural detail. Discreet masses are not identified. The colonic wall is normal. No obstructive disease is noted.

SPECIES

Canine

Pancreas

The region of the pancreas is isoechoic relative to surrounding omental fat. No obvious parenchymal abnormalities are observed. There is no evidence of regional inflammation or effusion.

BREED

Yorkshire terrier mix

Free Abdomen

The peritoneal cavity is normal. There is no evidence of inflammation or effusion. The abdominal lymph nodes are normal/not visible.

SEX

Female, spayed

AGE

8 Yrs.

Primary Findings:

- An obvious cause for the patient's mildly elevated ALT is not identified in this study. Considerations include reactive hepatopathy, inflammatory disease (i.e., chronic active hepatitis, bacterial cholangiohepatitis), hepatotoxicosis (i.e., copper), Leptospirosis (less likely in an asymptomatic patient), portal vein hypoplasia, other.

WEIGHT

5.38 lbs.

Secondary Findings:

- The mild right adrenomegaly may be a normal variant for this patient or may represent early hyperplastic change.

INTERPRETED BY

Andrea Nicastro, DVM,
Diplomate ACVIM
(Small Animal Internal
Medicine)

INTERPRETATION OF THE FINDINGS & FURTHER RECOMMENDATIONS

- Consider pre and post prandial serum bile acids to assess hepatic function.
- Leptospirosis testing can be considered if the clinical suspicion for disease is high.
- Ultimately, hepatic tissue sampling (i.e., fine needle aspirate or surgical biopsy) may be necessary to get a definitive diagnosis. Surgical biopsies are more likely to be representative of global organ pathology. If pursued, additional hepatic tissue sampling for copper quantitation should be performed along with aerobic and anaerobic bile cultures. Prior to any tissue sampling, clotting times (PT/PTT) should be performed.
- If a conservative approach is desired, consider empirical treatment for bacterial cholangiohepatitis (amoxicillin-clavulanic acid, Denamarin +/- metronidazole). If no improvement in the liver values is seen within 7-10 days of initiating therapy, antibiotics should be discontinued and hepatic tissue sampling reconsidered. If liver values improve, continue therapy for at least 4-6 weeks and 1 week beyond normalization of the liver values.

IMAGING PERFORMED BY

Jenna Walsh

HOSPITAL NAME

Companion Pet Clinic

REFERRING VET

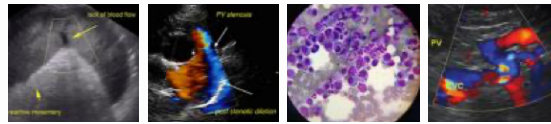
Dr. Mills

DATE

9/12/22

INVOICE

13939



PATIENT

Ellie Fettig

SPECIES

Canine

BREED

Yorkshire terrier mix

SEX

Female, spayed

AGE

8 Yrs.

WEIGHT

5.38 lbs.

INTERPRETED BY

Andrea Nicastro, DVM,
Diplomate ACVIM
(Small Animal Internal
Medicine)

IMAGING PERFORMED BY

Jenna Walsh

HOSPITAL NAME

Companion Pet Clinic

REFERRING VET

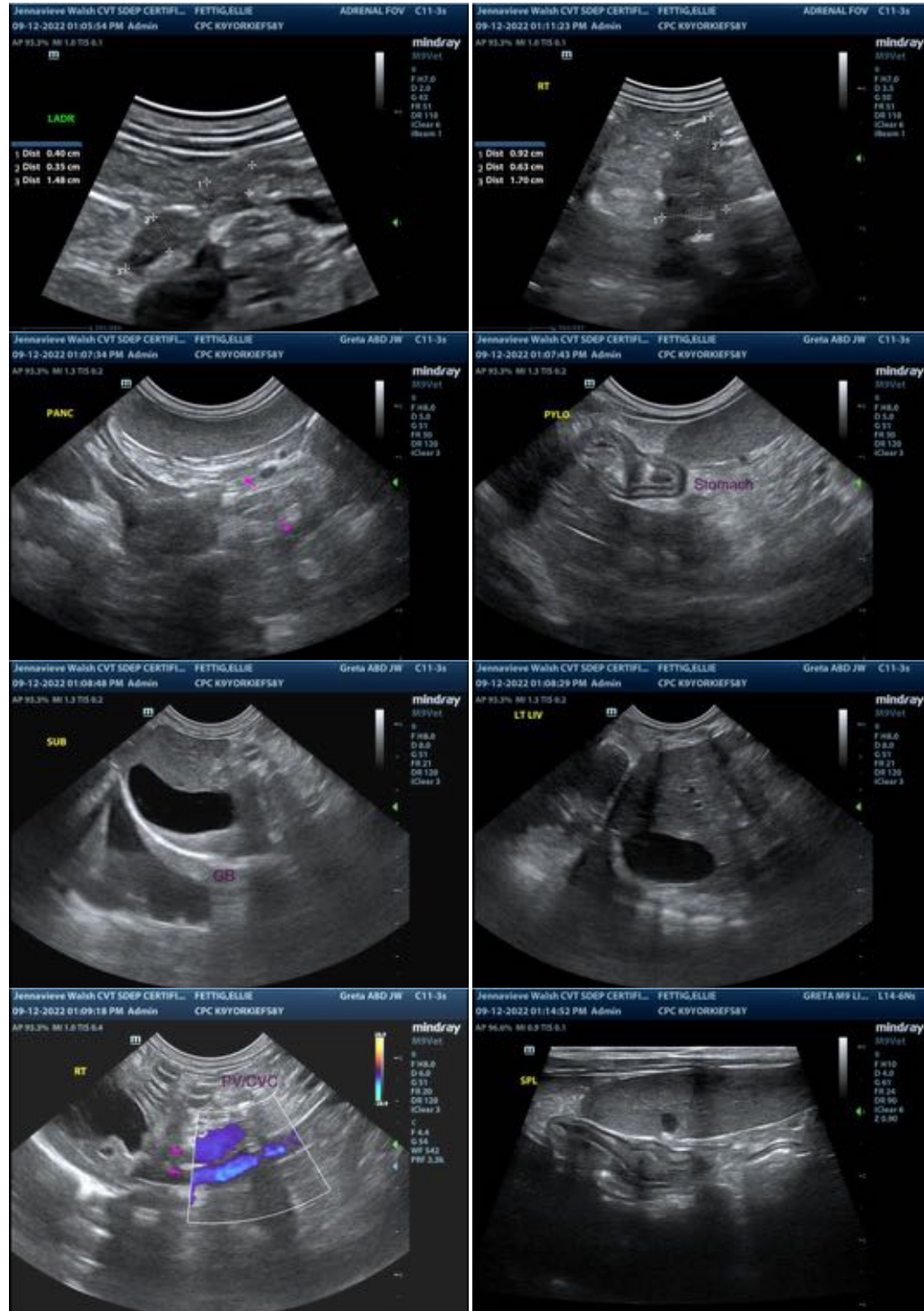
Dr. Mills

DATE

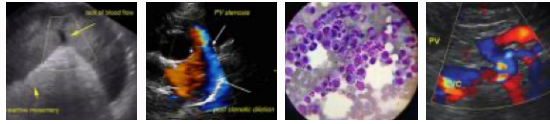
9/12/22

INVOICE

13939



The information and recommendations provided are based on the images presented by the referring veterinarian/sonographer. No evaluation can be communicated regarding pathology that was not visible



PATIENT

in the image/video clips provided.

Ellie Fettig

Thank you for this referral. If the clinical or image interpretation does not parallel your findings or if I can be of any further assistance please contact me.

SPECIES

Andrea Nicastro, MPH, DVM, Diplomate DACVIM (Small Animal Internal Medicine)
info@SonoPath.com

Canine

BREED

Yorkshire terrier mix

SEX

Female, spayed

AGE

8 Yrs.

WEIGHT

5.38 lbs.

INTERPRETED BY

Andrea Nicastro, DVM,
Diplomate ACVIM
(*Small Animal Internal
Medicine*)

**IMAGING
PERFORMED BY**

Jenna Walsh

HOSPITAL NAME

Companion Pet Clinic

REFERRING VET

Dr. Mills

DATE

9/12/22

INVOICE

13939