

PATIENT

Hannah Simmons

SPECIES

Feline

BREED

Domestic Shorthair

SEX

Female Spayed

AGE

10 years

WEIGHT

9.1 lbs.

INTERPRETED BY

Andrea Nicastro, DVM,
Diplomate ACVIM
(Small Animal Internal
Medicine)

IMAGING PERFORMED BY

Jenna Walsh

HOSPITAL NAME

Q Street Animal
Hospital

REFERRING VET

Dr. Cone

DATE

9/10/21

INVOICE
11805kk

PRESENTING CLINICAL SIGNS

History: Initially presented last week for lethargy, vomiting, and anorexia. Treated several times with SQ fluids, Cerenia, and Mirtazapine throughout the weekend. Vomiting resolved and energy has improved, but poor appetite and weight loss have continued. No known toxin or foreign body ingestion. Physical exam unremarkable; mild dehydration.

Current Medications: Mirtazapine.

Abnormal PE/Chem/CBC/UA Results: Lymphopenia (637, N=1200-8000). CBC Chem and T4 are unremarkable.

ULTRASONOGRAPHIC EXAMINATION OF THE ABDOMEN

Urinary System

The urinary bladder, trigone, and pelvic urethra are normal in thickness and the mucosal surface is smooth. The bladder is moderately distended. A small amount of suspended, echogenic debris is observed within the lumen. No masses, inflammatory changes or calculi are observed. Ureteral papillae and visualized portion of the proximal urethra, visible to a depth of 2 cm, are normal.

The left kidney is normal size (3.09 cm in length); normal shape and architecture with smooth peripheral margins. There is a normal 1:3 cortex to medulla ratio with normal corticomedullary distinction. There is no evidence of pyelectasia, nephroliths, infarcts or hydronephrosis. Renal vasculature is normal.

The right kidney is normal size (3.88 cm in length); normal shape and architecture with smooth peripheral margins. There is a normal 1:3 cortex to medulla ratio with normal corticomedullary distinction. There is no evidence of pyelectasia, nephroliths, infarcts or hydronephrosis. Renal vasculature is normal.

Adrenal Glands

The region of the left adrenal gland is evaluated. No obvious pathology is seen.

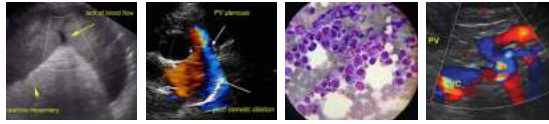
The right adrenal gland is normal size (0.96 cm length; 0.30 cm width). Normal shape and glandular echogenicity. The phrenicoabdominal vein and surrounding vasculature are normal.

Spleen

The spleen is normal in size (0.69 cm in width at the level of the hilus) with a normal capsular contour. There is appropriate echogenicity and echotexture. No focal lesions are observed. Splenic vasculature is normal.

Liver

The liver is subjectively normal in size with normal contours and structure. There is appropriate echogenicity and echotexture. No overt structural evidence of inflammatory, infiltrative, or regenerative pathology is evident. Vascular and biliary tracts are of normal volume with no evidence of congestion. No pathological hepatic lymphadenopathy observed. The gall bladder lumen is moderately distended. The wall is thin and smooth. A small amount of suspended echogenic debris is observed within the lumen. The cystic and common bile ducts are normal/not seen.



PATIENT

Gastrointestinal

Hannah Simmons

The stomach and intestine are free of stasis and exhibit normal peristaltic activity. The gastric lumen is not distended. The gastric wall and pylorus are normal in thickness with a normal layering pattern. The pyloric outflow tract is patent. The small intestinal lumen is not dilated. The small intestinal wall thickness is normal with a normal layering pattern and appropriate mural detail. There is disruption in the normal 1:3 muscularis: mucosal ratio in some segments. Discreet masses are not identified. The ileocecal colic junction and colonic wall are normal. No obstructive disease is noted.

SPECIES

Feline

BREED

Pancreas

Domestic Shorthair

The region of the pancreas is isoechoic relative to surrounding omental fat. No obvious parenchymal abnormalities are observed. There is no evidence of regional inflammation or effusion.

SEX

Free Abdomen

Female Spayed

A focal area of reactive mesentery is observed in the midabdominal cavity. No free fluid is observed. The abdominal lymph nodes are normal/not visible.

AGE

Other

10 years

A brief echocardiogram reveals no evidence of pericardial effusion.

WEIGHT

9.1 lbs.

ULTRASONOGRAPHIC FINDINGS

- Bowel pattern consistent with inflammatory bowel disease with potential for emerging lymphoma.
- A cause for the reactive mesentery in the mid-abdominal cavity is not identified. However, mild bowel inflammation is consideration.

INTERPRETED BY

INTERPRETATION OF THE FINDINGS & FURTHER RECOMMENDATIONS

Andrea Nicastro, DVM,
Diplomate ACVIM
(Small Animal Internal
Medicine)

1. The following diagnostics can be considered:
 - a. Three-view thoracic radiographs are recommended to assess for occult neoplasia and/or esophageal disease.
 - b. A malabsorption panel including serum cobalamin, folate, PLI and TLI.
 - c. A fecal evaluation for ova/Giardia.
 - d. If clinical signs do not improve with supportive care, endoscopic or surgical gastrointestinal biopsies may be necessary to get a definitive diagnosis.

IMAGING PERFORMED BY

Jenna Walsh

HOSPITAL NAME

Q Street Animal
Hospital

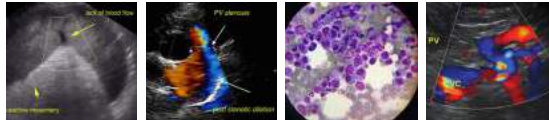
REFERRING VET

Dr. Cone

DATE

9/10/21

INVOICE
11805kk



PATIENT

Hannah Simmons

SPECIES

Feline

BREED

Domestic Shorthair

SEX

Female Spayed

AGE

10 years

WEIGHT

9.1 lbs.

INTERPRETED BY

Andrea Nicastro, DVM,
Diplomate ACVIM
(Small Animal Internal
Medicine)

IMAGING PERFORMED BY

Jenna Walsh

HOSPITAL NAME

Q Street Animal
Hospital

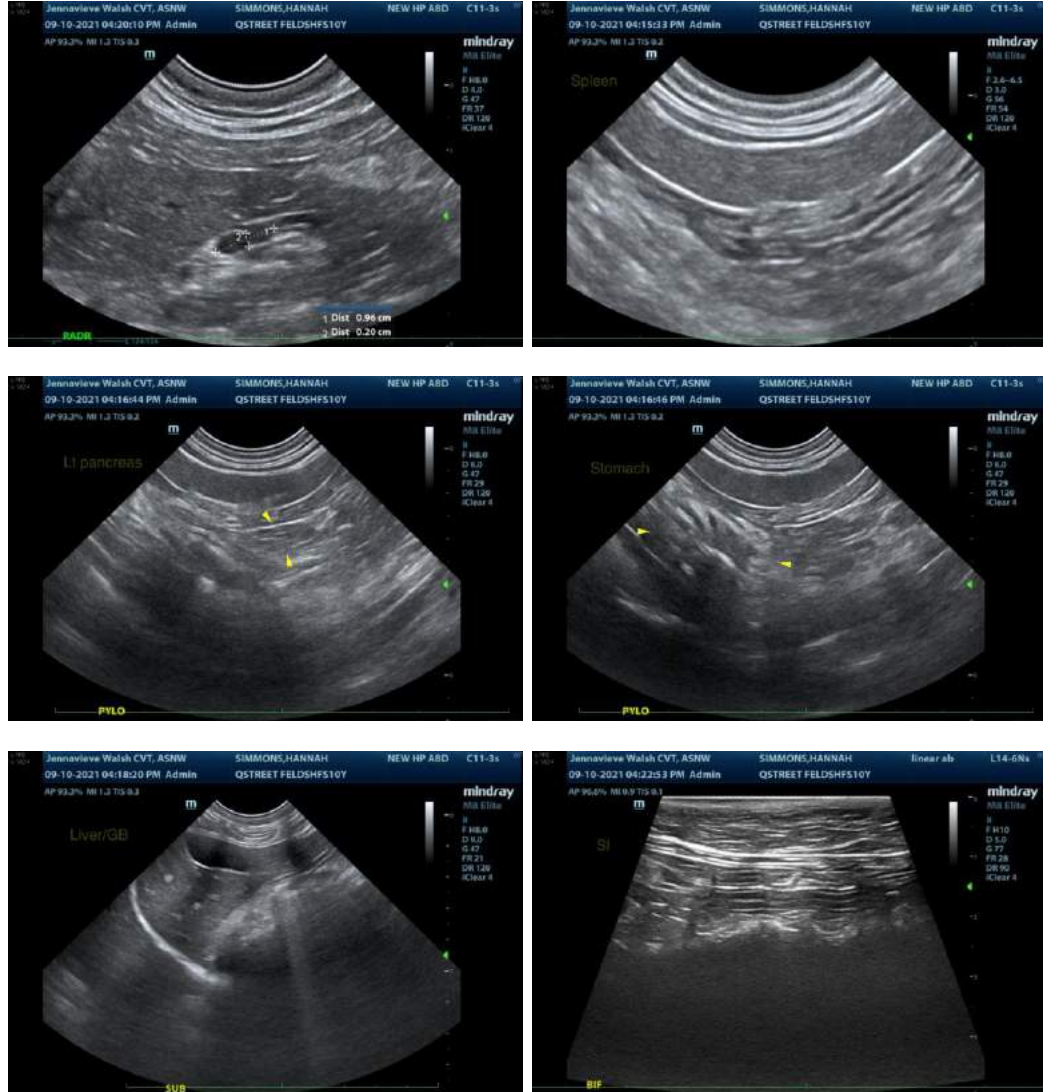
REFERRING VET

Dr. Cone

DATE

9/10/21

INVOICE
11805kk



The information and recommendations provided are based on the images presented by the referring veterinarian. No evaluation can be communicated regarding pathology that was not visible in the image/video clips provided.

Thank you for this referral. If the clinical or image interpretation does not parallel your findings or if I can be of any further assistance, please contact me.

Andrea Nicastro, DVM, Diplomate ACVIM (Small Animal Internal Medicine)
Andrea.nicastro@sonopath.com