



**PATIENT**

Axel Mitzlaff

**SPECIES**

Feline

**BREED**

Bengal

**SEX**

Male, neutered

**AGE**

13 yrs.

**WEIGHT**

7.98 lbs.

**INTERPRETED BY**

Andrea Nicastro, DVM,  
Diplomate ACVIM  
(Small Animal Internal  
Medicine)

**IMAGING  
PERFORMED BY**

Sara Hansen

**HOSPITAL NAME**

West Hills AH

**REFERRING VET**

Dr. Remcho

**INVOICE**

13104

**DATE**

3/8/2022

**PRESENTING CLINICAL SIGNS**

History: weight loss and hyporexia.

Abnormal PE/Chem/CBC/UA Results: GI panel pending. CBC, Chem and T4 - wnl. proBNP 810

Current Medications none Radiographic Findings STUDY: Thorax and abdomen radiographs (5 images)

dated March 3, 2022. THORAX: • The cardiac silhouette (VHS 7.5) and pulmonary vessels are within normal limits. • The pulmonary parenchyma is unremarkable. • The pleural space and mediastinum are unremarkable. ABDOMEN: • There is a moderate amount of heterogeneous soft tissue opaque material admixed with gas within the stomach. • The small intestines are within normal limits. • There is loosely formed fecal material admixed with gas in the colon. • The liver, spleen, kidneys, and urinary bladder are unremarkable. • The abdominal serosal margin detail is normal. MUSCULOSKELETAL: • The skeletal structures are unremarkable. Assessment: 1. Unremarkable thorax. No evidence of pulmonary metastasis or intrathoracic lymphadenopathy. No evidence of congestive heart failure. 2. Postprandial gastrointestinal changes. Further correlate with the diet and last known meal. No evidence of pathologic distention or plication of the small intestine to suggest mechanical ileus/obstruction, at this time. 3. Otherwise, unremarkable abdomen.

**ULTRASONOGRAPHIC EXAMINATION OF THE ABDOMEN**

*Urinary System*

The urinary bladder, trigone, and pelvic urethra are normal in thickness and the mucosal surface is smooth. The bladder lumen is moderately distended with mostly anechoic urine. No masses, inflammatory changes or calculi are observed. Ureteral papillae and visualized portion of the proximal urethra, visible to a depth of 2 cm, are normal.

The left kidney is normal size (4.15 cm in length); normal shape and architecture with smooth peripheral margins. The cortex is hyperechoic. There is a normal 1:3 cortex to medulla ratio with minimal loss of corticomedullary distinction. There is no evidence of pyelectasia, nephroliths, infarcts or hydroureter. Renal vasculature is normal.

The right kidney is normal size (4.76 cm in length); normal shape and architecture with smooth peripheral margins. The cortex is hyperechoic. There is a normal 1:3 cortex to medulla ratio with minimal loss of corticomedullary distinction. There is no evidence of pyelectasia, nephroliths, infarcts or hydroureter. Renal vasculature is normal.

*Adrenal Glands*

The region of the left adrenal gland is evaluated. No obvious pathology is observed.

The right adrenal gland is normal in size (0.81 cm length; 0.35 cm width). Normal shape and glandular echogenicity. The phrenicoabdominal vein and surrounding vasculature are normal.

*Spleen*

The spleen is normal in size (0.79 cm in width at the level of the hilus) with a normal capsular contour. There is appropriate echogenicity and echotexture. No focal lesions are observed. Splenic vasculature is normal.

*Liver*

The liver is subjectively normal in size with normal contours and structure. There is appropriate echogenicity and echotexture. No overt structural evidence of inflammatory, infiltrative or



**PATIENT**

Axel Mitzlaff

regenerative pathology is evident. Vascular and biliary tracts are of normal volume with no evidence of congestion. No pathological hepatic lymphadenopathy observed. The portal vein: vena cava ratio is approximately 1:1. The gall bladder lumen is moderately distended. The wall is thin and smooth. A scant amount of echogenic debris is observed within the lumen. The cystic and common bile ducts are normal.

**SPECIES**

Feline

**Gastrointestinal**

The gastric lumen is not distended. The gastric wall and pylorus are normal in thickness with a normal layering pattern. The pyloric outflow tract is patent. The small intestinal lumen is not dilated. The small intestinal wall is normal to moderately thickened (up to 0.40 cm) with a normal layering pattern and appropriate mural detail. There is disruption in the normal 1:3 muscularis: mucosal ratio and mild thickening of the submucosal layer in some segments. The ileum is normal in thickness. A few cm of ascending colon, just distal to the ileocecal colic junction, are thickened (up to 0.40 cm) with loss of the normal layering pattern. The wall tapers to a normal thickness as it extends distally. The colonic lumen contains shadowing fecal material. No obstructive disease is noted.

**BREED**

Bengal

**SEX**

Male, neutered

**Pancreas**

The left limb and body of the pancreas are prominent to enlarged with slightly irregular peripheral contours. The parenchyma is hypoechoic relative to surrounding omental fat. No focal lesions are observed. The pancreatic duct is visible but not overtly dilated (0.19 cm in diameter).

**AGE**

13 yrs.

**Free Abdomen**

The mesentery throughout the abdomen is hyperechoic. A small amount of free fluid is observed. An approximately 4 cm mass effect is observed in the mesenteric root lymph nodes. The mesenteric nodes are irregular to rounded and hypoechoic. A few smaller nodes are also seen throughout the abdomen.

**WEIGHT**

7.98 lbs.

**INTERPRETED BY**

Andrea Nicastro, DVM,  
Diplomate ACVIM  
(Small Animal Internal  
Medicine)

**ULTRASONOGRAPHIC FINDINGS**

**Primary Findings:**

- The mesenteric root changes are most concerning for infiltrative neoplasia. Lymphoma is the top differential. However, pyogranulomatous lymphadenitis (i.e., secondary to FIP) cannot be completely excluded.
- The ascending colonic wall changes are also concerning for infiltrative neoplasia with a lower possibility of an inflammatory process. The diffuse small intestinal thickening and wall changes could be consistent with inflammatory bowel disease or emerging lymphoma.
- Diffuse peritonitis is present, likely secondary to lymph node and bowel pathology.
- The pancreatic changes are suggestive of pancreatitis.

**Secondary Findings:**

- Minor age-related renal changes.

**IMAGING PERFORMED BY**

Sara Hansen

**HOSPITAL NAME**

West Hills AH

**REFERRING VET**

Dr. Remcho

**INVOICE**

13104

**INTERPRETATION OF THE FINDINGS & FURTHER RECOMMENDATIONS**

**DATE**

3/8/2022



## PATIENT

Axel Mitzlaff

## SPECIES

Feline

## BREED

Bengal

## SEX

Male, neutered

## AGE

13 yrs.

## WEIGHT

7.98 lbs.

## INTERPRETED BY

Andrea Nicastro, DVM,  
Diplomate ACVIM  
(Small Animal Internal  
Medicine)

## IMAGING PERFORMED BY

Sara Hansen

## HOSPITAL NAME

West Hills AH

## REFERRING VET

Dr. Remcho

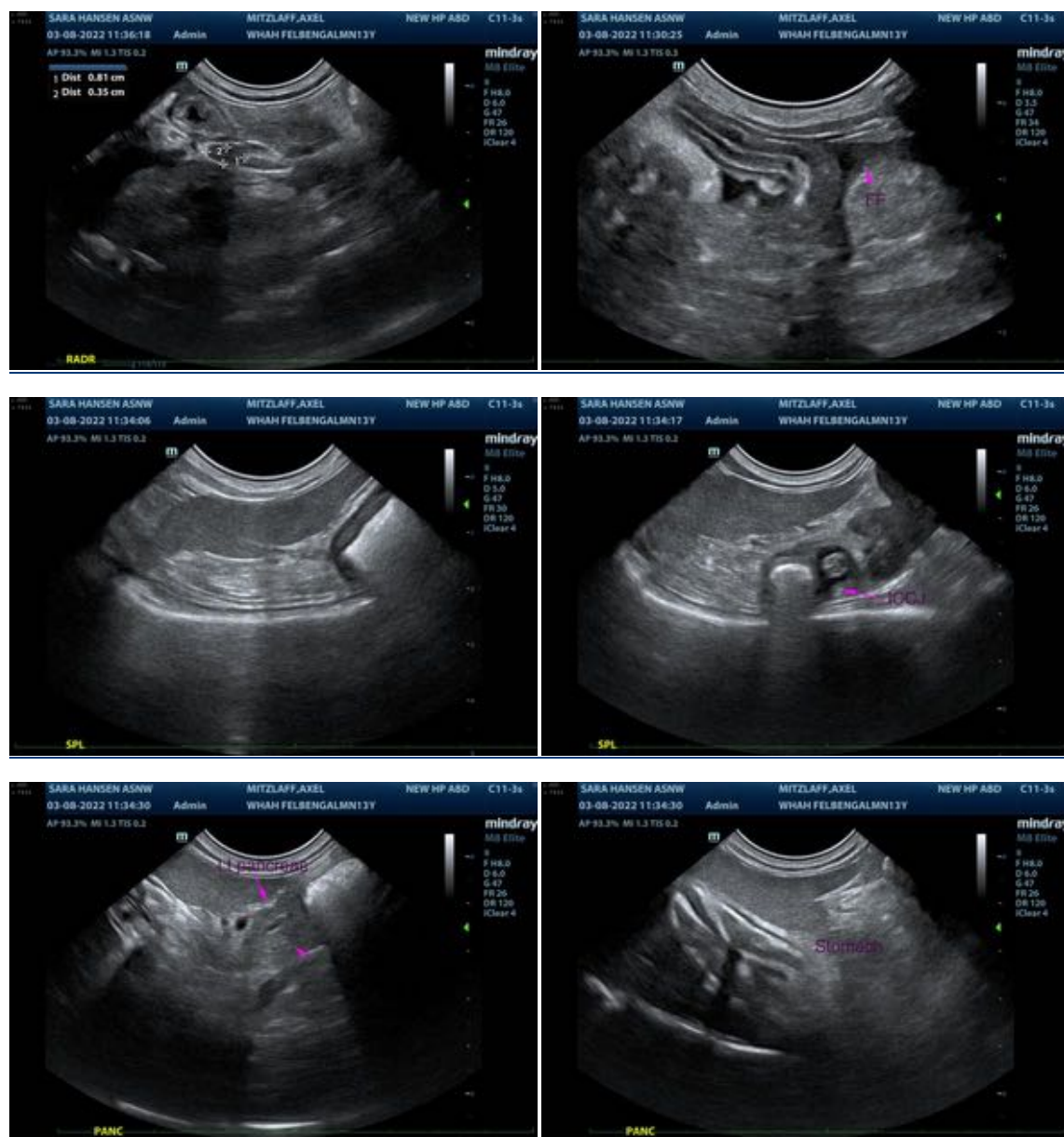
## INVOICE

13104

## DATE

3/8/2022

- Three-view thoracic radiographs are recommended to assess for lymphadenopathy in the chest.
- A fine needle aspirate of the mesenteric lymph nodes is recommended if clotting status is appropriate. A 25-gauge needle should be used. If cytology results are inconclusive, surgical biopsies of the GI tract and lymph nodes may be necessary to get a definitive diagnosis.
- Also consider a malabsorption panel (send to Texas A&M) to assess for maldigestion/malabsorption and concurrent pancreatitis.





**PATIENT**

Axel Mitzlaff

**SPECIES**

Feline

**BREED**

Bengal

**SEX**

Male, neutered

**AGE**

13 yrs.

**WEIGHT**

7.98 lbs.

**INTERPRETED BY**

Andrea Nicastro, DVM,  
Diplomate ACVIM  
(Small Animal Internal  
Medicine)

**IMAGING  
PERFORMED BY**

Sara Hansen

**HOSPITAL NAME**

West Hills AH

**REFERRING VET**

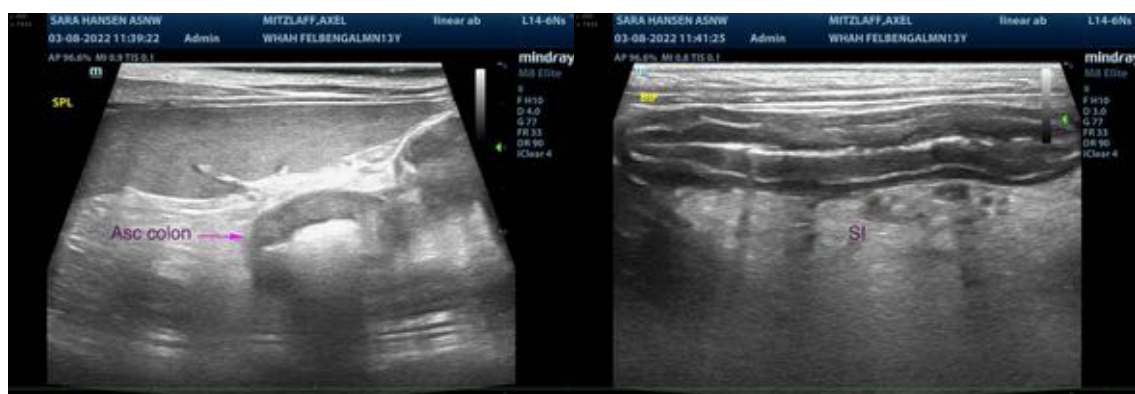
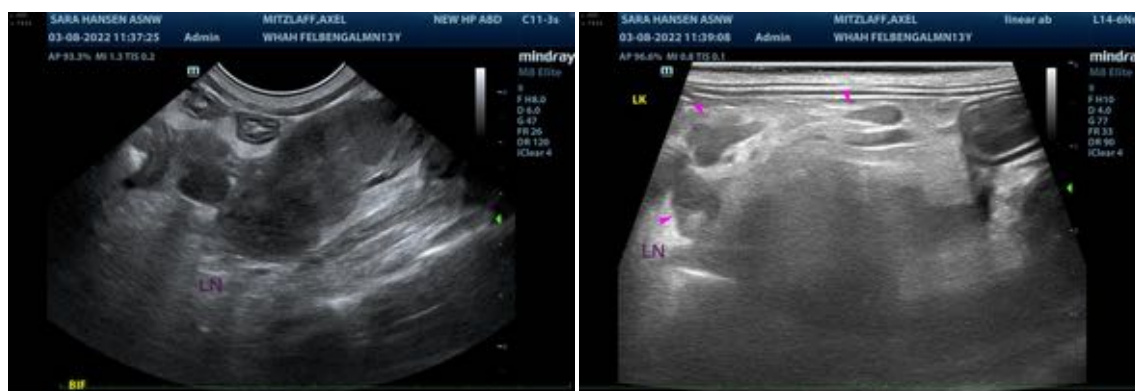
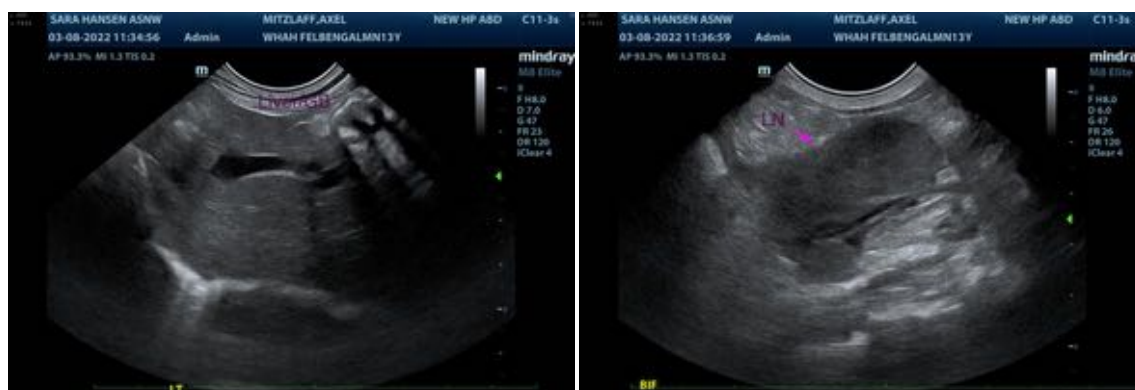Dr. Remcho

**INVOICE**

13104

**DATE**

3/8/2022



The information and recommendations provided are based on the images presented by the referring veterinarian/sonographer. No evaluation can be communicated regarding pathology that was not visible in the image/video clips provided.

Thank you for this referral. If the clinical or image interpretation does not parallel your findings or if I can be of any further assistance please contact me.

Andrea Nicastro, DVM, Diplomate ACVIM (Small Animal Internal Medicine)

Andrea.nicastro@sonopath.com