

PATIENT

Star Geertsen

SPECIES

Canine

BREED

Lab mix

SEX

Female, spayed

AGE

9 Yrs.

WEIGHT

74 lbs.

INTERPRETED BY

Andrea Nicastro, DVM,
Diplomate ACVIM
(Small Animal Internal
Medicine)

**IMAGING
PERFORMED BY**

Sara Hansen

HOSPITAL NAME

Santa Clara AH

REFERRING VET

Dr. Giddens

DATE

2/27/23

INVOICE

14648

PRESENTING CLINICAL SIGNS

History: Enlarged liver or spleen? on palpation of cranial abdomen found on routine annual exam. No clinical signs.
Abnormal PE/Chem/CBC/UA Results: ALP elevated at 405 ALT elevated at 174 Current Medications Meloxicam for arthritis Radiographic Findings Enlarged liver- mass effect near pylorus

ULTRASONOGRAPHIC EXAMINATION OF THE ABDOMEN

Urinary System

The urinary bladder wall is normal in thickness and the mucosal surface is smooth. The bladder lumen is moderately distended with anechoic urine. No masses, inflammatory changes or calculi are observed. Ureteral papillae and visualized portion of the proximal urethra, visible to a depth of 1-2 cm, are normal.

The left kidney is normal size (6.51 cm in length); normal shape and architecture with smooth peripheral margins. There is a normal 1:3 cortex to medulla ratio with minimal loss of corticomedullary distinction. There is no evidence of pyelectasia, nephroliths, infarcts or hydronephrosis. Renal vasculature is normal.

The right kidney is normal size (7.07 cm in length); normal shape and architecture with smooth peripheral margins. There is a normal 1:3 cortex to medulla ratio with minimal loss of corticomedullary distinction. There is no evidence of pyelectasia, nephroliths, infarcts or hydronephrosis. Renal vasculature is normal.

Adrenal Glands

The left adrenal gland is normal size (0.51 cm at cranial pole) (0.75 cm at caudal pole) (2.77 cm in length); normal shape; homogenous parenchyma. The glandular echogenicity and detail are unremarkable. Capsule, cortex, and medullary definition are normal. The phrenicoabdominal vein and surrounding vasculature are normal.

The region of the right adrenal gland is evaluated. No obvious pathology is observed.

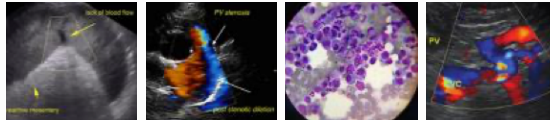
Spleen

The spleen is normal to slightly prominent in size (2.50 cm in width at the level of the hilus) with normal curvilinear peripheral contours. There is appropriate echogenicity and echotexture. No focal lesions are observed. Splenic vasculature is normal.

Liver

The liver is normal to slightly prominent in size with normal curvilinear peripheral contours. The parenchyma is isoechoic relative to the spleen and diffusely heterogeneous in appearance. No distinct focal lesions are observed. Vascular and biliary tracts are of normal volume with no evidence of congestion. The gall bladder lumen is moderately distended. The wall is thin and smooth. Luminal contents are anechoic. The cystic and common bile ducts are normal/not seen.

Gastrointestinal



PATIENT

Star Geertsen

SPECIES

Canine

BREED

Lab mix

SEX

Female, spayed

AGE

9 Yrs.

WEIGHT

74 lbs.

INTERPRETED BY

Andrea Nicastro, DVM,
Diplomate ACVIM
(Small Animal Internal
Medicine)

**IMAGING
PERFORMED BY**

Sara Hansen

HOSPITAL NAME

Santa Clara AH

REFERRING VET

Dr. Giddens

DATE

2/27/23

INVOICE

14648

The stomach and intestine are free of stasis and exhibit normal peristaltic activity. The gastric lumen is not distended. The gastric wall and pylorus are normal in thickness with a normal layering pattern. The pyloric outflow tract is patent. The small intestinal lumen is not dilated. The small intestinal wall thickness is normal with a normal layering pattern and appropriate mural detail. Discreet masses are not identified. The colonic wall is normal. No obstructive disease is noted.

Pancreas

The region of the pancreas is isoechoic relative to surrounding omental fat. No obvious parenchymal abnormalities are observed. There is no evidence of regional inflammation or effusion.

Free Abdomen

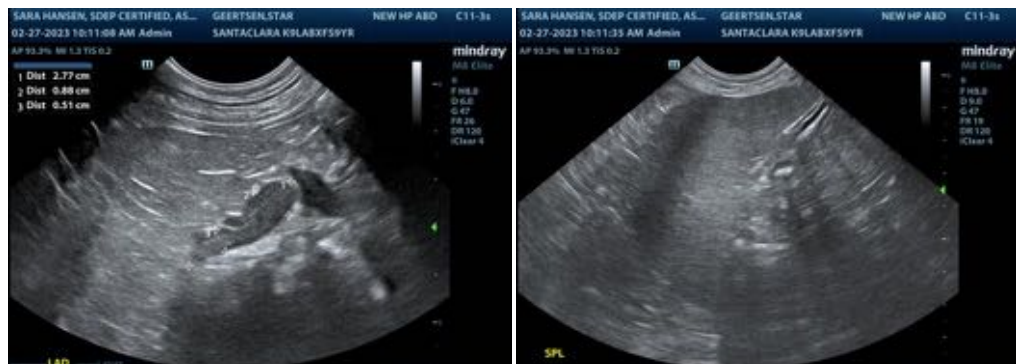The peritoneal cavity is normal. There is no evidence of inflammation or effusion. The abdominal lymph nodes are normal/not visible.

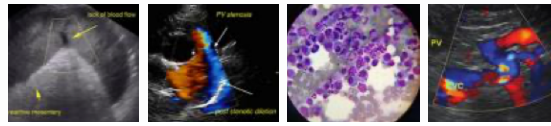
ULTRASONOGRAPHIC FINDINGS

- The diffuse hepatic changes are non-specific and could be consistent with vacuolar hepatopathy, regenerative nodular hyperplasia, and/or age-related remodeling. Inflammatory and infiltrative disease are considered less likely.
- The splenic parenchymal changes are most consistent with a benign process such as lymphoid hyperplasia, extramedullary hematopoiesis, splenitis or antigenic stimulation with a low possibility of infiltrative neoplasia (i.e., lymphoma, mast cell neoplasia).

INTERPRETATION OF THE FINDINGS & FURTHER RECOMMENDATIONS

- Fine needle aspirates of the liver and spleen can be considered, if clotting status is appropriate. However, cytologies may be of low yield as the parenchymal changes trend toward the benign.
- Serial monitoring (i.e., every 3-4 months) of the patient's liver values is recommended. If liver values continue to increase, a repeat abdominal ultrasound +/- hepatic tissue sampling may be warranted.





PATIENT

Star Geertsen

SPECIES

Canine

BREED

Lab mix

SEX

Female, spayed

AGE

9 Yrs.

WEIGHT

74 lbs.

INTERPRETED BY

Andrea Nicastro, DVM,
Diplomate ACVIM
(Small Animal Internal
Medicine)

IMAGING PERFORMED BY

Sara Hansen

HOSPITAL NAME

Santa Clara AH

REFERRING VET

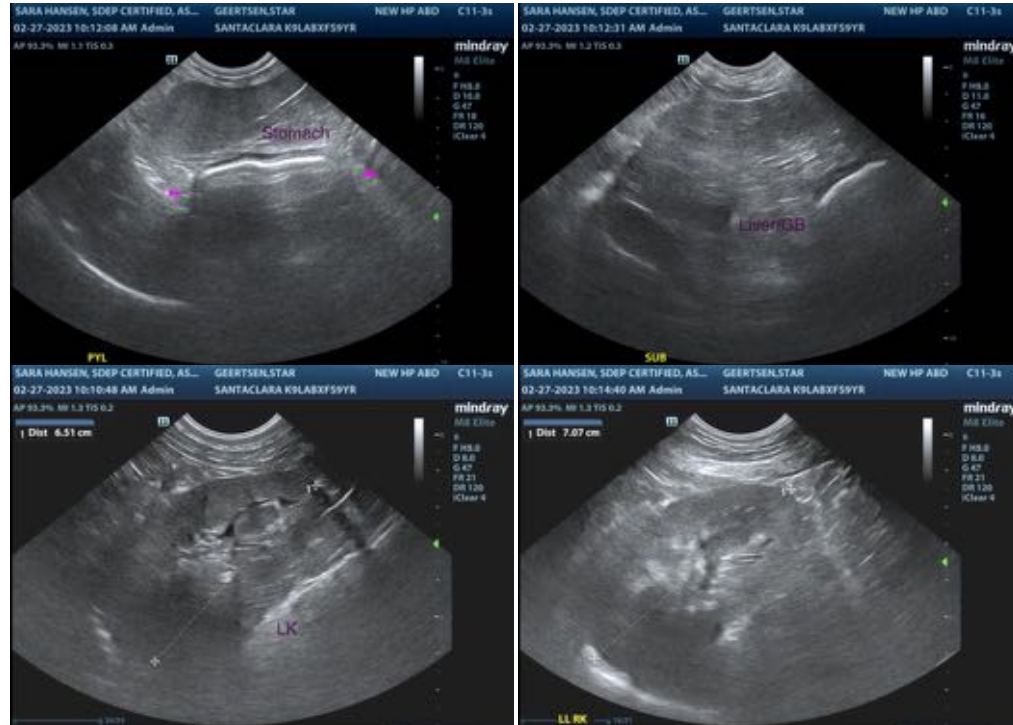
Dr. Giddens

DATE

2/27/23

INVOICE

14648



The information and recommendations provided are based on the images presented by the referring veterinarian/sonographer. No evaluation can be communicated regarding pathology that was not visible in the image/video clips provided.

Thank you for this referral. If the clinical or image interpretation does not parallel your findings or if I can be of any further assistance please contact me.

Andrea Nicastro, MPH, DVM, Diplomate DACVIM (Small Animal Internal Medicine)
info@SonoPath.com