

PATIENT

Raskal McEwen

SPECIES

Canine

BREED

Pit bull

SEX

Female, spayed

AGE

13 Yrs.

WEIGHT

73.5 lbs.

INTERPRETED BY

Andrea Nicastro, DVM,
Diplomate ACVIM
(Small Animal Internal
Medicine)

IMAGING PERFORMED BY

Jenna Walsh

HOSPITAL NAME

West Hills AH

REFERRING VET

Dr. Fogarty

DATE

11/2/21

INVOICE

12474

PRESENTING CLINICAL SIGNS

History: Hx from rDVM: distended appearance to abdomen
Abnormal PE/Chem/CBC/UA Results: Most recent labs are from 7/2020: ALP 475, UPC 0.5

ULTRASONOGRAPHIC EXAMINATION OF THE ABDOMEN

Urinary System

The urinary bladder, trigone, and pelvic urethra are normal in thickness and the mucosal surface is smooth. The bladder lumen is moderately distended with anechoic urine. No masses, inflammatory changes or calculi are observed. Ureteral papillae and visualized portion of the proximal urethra, visible to a depth of 2 cm, are normal.

The left kidney is normal in size (6.97 cm in length) with a normal shape, smooth peripheral margins and normal internal architecture. There is mild loss of corticomedullary distinction. Several hyperechoic shadowing diverticular foci are observed. There is no evidence of pyelectasia, infarcts or hydronephrosis. Renal vasculature is normal.

The right kidney is normal in size (6.98 cm in length) with a normal shape, smooth peripheral margins and normal internal architecture. There is minimal loss of corticomedullary distinction. Several hyperechoic shadowing diverticular foci are observed. There is no evidence of pyelectasia, infarcts or hydronephrosis. Renal vasculature is normal.

Adrenal Glands

The left adrenal gland is normal size (0.63 cm at cranial pole) (0.65 cm at caudal pole) (3.37 cm in length); normal shape; homogenous parenchyma. The glandular echogenicity and detail are unremarkable. Capsule, cortex, and medullary definition are normal. The phrenicoabdominal vein and surrounding vasculature are normal.

The right adrenal gland is normal size (0.68 cm at cranial pole) (0.66 cm at caudal pole) (2.32 cm in length); normal shape; homogenous parenchyma. The glandular echogenicity and detail are unremarkable. Capsule, cortex, and medullary definition are normal. The phrenicoabdominal vein and surrounding vasculature are normal.

Spleen

The spleen is normal to slightly prominent in size (2.72 cm in width at the level of the hilus) with normal curvilinear peripheral contours. The parenchyma is subtly mottled in appearance. No focal lesions are observed. Splenic vasculature is normal.

Liver

The liver is subjectively enlarged with swollen to rounded peripheral contours. The parenchyma is isoechoic relative to the spleen and subtly heterogeneous in appearance. A 5.46 cm isoechoic to slightly heterogeneous mass is observed mid to deep right liver. In addition, a 1.14 cm cyst is observed deep on the left side. Vascular and biliary tracts are of normal volume with no evidence of congestion. The gallbladder is of normal contours and contains some dependent echogenic debris. The wall is normal in thickness. No choleliths are observed. The cystic and common bile ducts are normal.



PATIENT

Gastrointestinal

Raskal McEwen

The stomach and intestine are free of stasis and exhibit normal peristaltic activity. The gastric lumen is not distended. The gastric wall and pylorus are normal in thickness with a normal layering pattern. The pyloric outflow tract is patent. The small intestinal lumen is not dilated. The small intestinal wall thickness is normal with a normal layering pattern and appropriate mural detail. Discreet masses are not identified. The colonic wall is normal. No obstructive disease is noted.

SPECIES

Canine

Pancreas

BREED

Pit bull

The right limb of the pancreas is visible/prominent with slightly irregular peripheral contours. The parenchyma is hyperechoic relative to surrounding omental fat and mottled in appearance. No distinct focal lesions are observed. The pancreatic duct is visible but not overtly dilated.

SEX

Free Abdomen

Female, spayed

Trace free fluid is observed. The abdominal lymph nodes are normal/not visible.

AGE

13 Yrs.

ULTRASONOGRAPHIC FINDINGS

Primary Findings:

WEIGHT

73.5 lbs.

- Hepatic mass. Neoplasia (i.e., adenoma, adenocarcinoma) is considered likely with a lower possibility of benign pathology (i.e., regenerative nodular hyperplasia). The diffuse hepatic parenchymal changes are most consistent with benign, age-related change with a lower possibility of underlying pathology.
- The trace ascites is suspected to be secondary to hepatic pathology. However, increased hydrostatic pressure and low oncotic pressure cannot be completely excluded.

INTERPRETED BY

Andrea Nicastro, DVM,
Diplomate ACVIM
(Small Animal Internal
Medicine)

Secondary Findings:

IMAGING PERFORMED BY

Jenna Walsh

- The pancreatic changes are most consistent with age-related parenchymal remodeling, potentially secondary to a prior inflammatory episode, early fibrosis or chronic pancreatitis.
- The splenic parenchyma changes are most consistent with a benign process such as lymphoid hyperplasia, extramedullary hematopoiesis or splenitis with a low possibility of infiltrative neoplasia (i.e., lymphoma, mast cell neoplasia).
- Minor age-related renal changes with dystrophic mineralization.

HOSPITAL NAME

West Hills AH

INTERPRETATION OF THE FINDINGS & FURTHER RECOMMENDATIONS

REFERRING VET

Dr. Fogarty

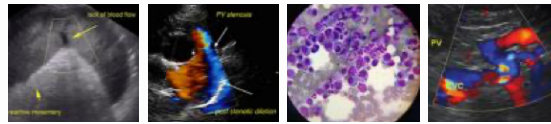
- Three-view thoracic radiographs are recommended to assess for pulmonary metastases.
- Repeat baseline labwork including a CBC chemistry panel, urinalysis and T4 is recommended to assess overall metabolic function.
- If an aggressive approach is desired, consider surgical removal of the hepatic mass and submission for histopathology. An abdominal CT scan would be useful in pre-surgical planning.

DATE

11/2/21

INVOICE

12474



PATIENT

Raskal McEwen

Ideally, surgery would be performed by a board-certified surgeon due to the potential complexity of the procedure (given the location of the mass).

SPECIES

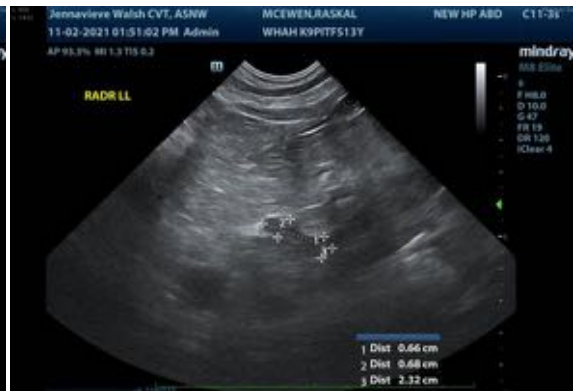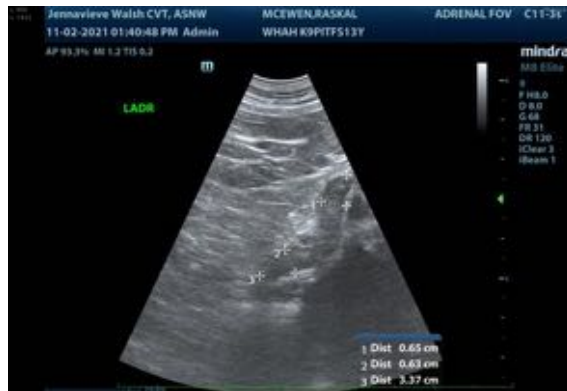Canine

BREED

Pit bull

SEX

Female, spayed

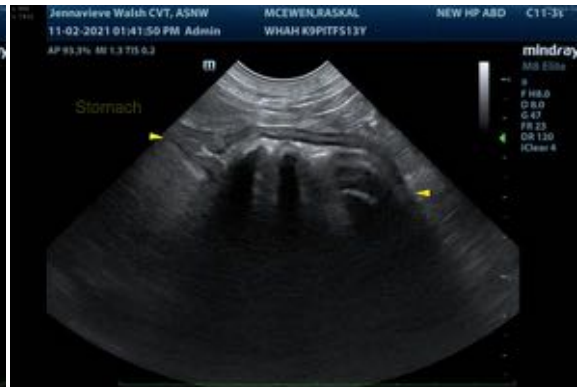
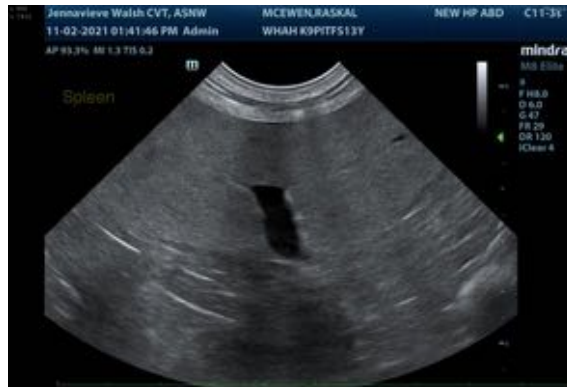
AGE

13 Yrs.

WEIGHT

73.5 lbs.

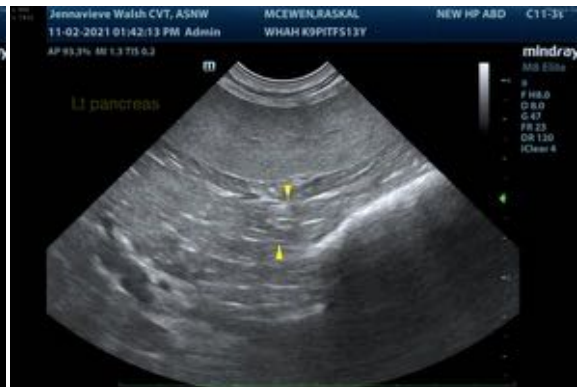
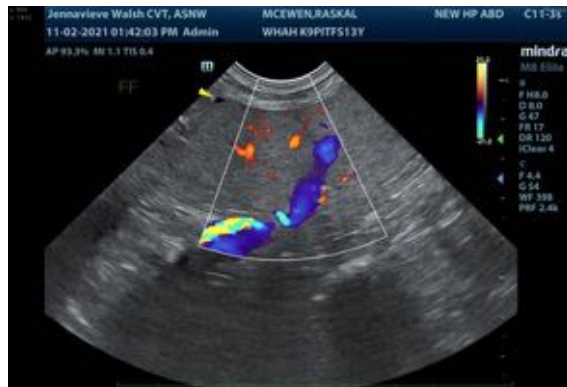
INTERPRETED BY

Andrea Nicastro, DVM,
Diplomate ACVIM
(Small Animal Internal
Medicine)

IMAGING PERFORMED BY

Jenna Walsh



HOSPITAL NAME

West Hills AH

REFERRING VET

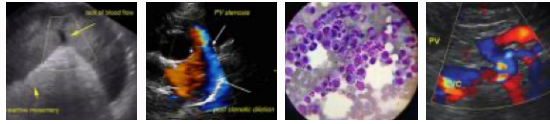
Dr. Fogarty

DATE

11/2/21

INVOICE

12474



PATIENT

Raskal McEwen

SPECIES

Canine

BREED

Pit bull

SEX

Female, spayed

AGE

13 Yrs.

WEIGHT

73.5 lbs.

INTERPRETED BY

Andrea Nicastro, DVM,
Diplomate ACVIM
(Small Animal Internal
Medicine)

IMAGING PERFORMED BY

Jenna Walsh

HOSPITAL NAME

West Hills AH

REFERRING VET

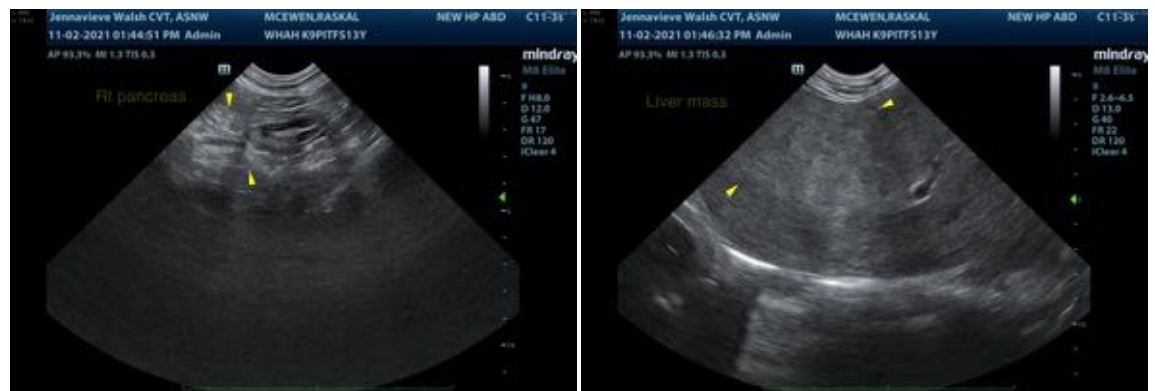
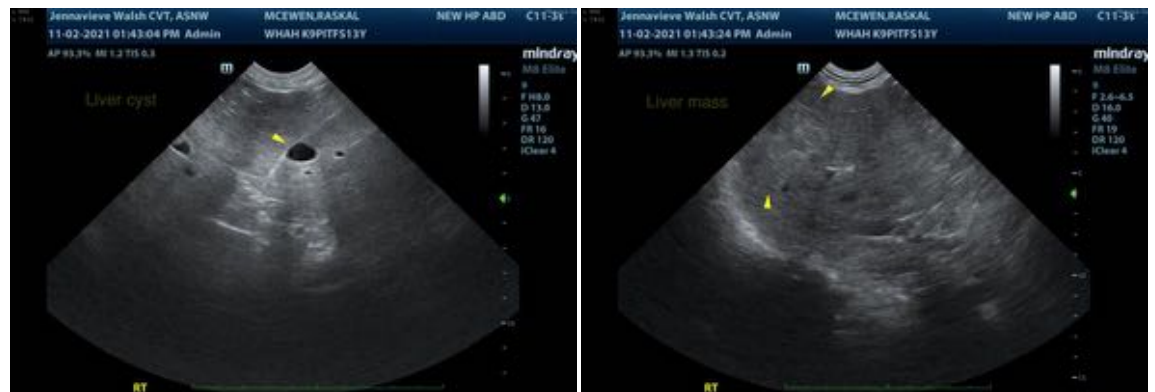
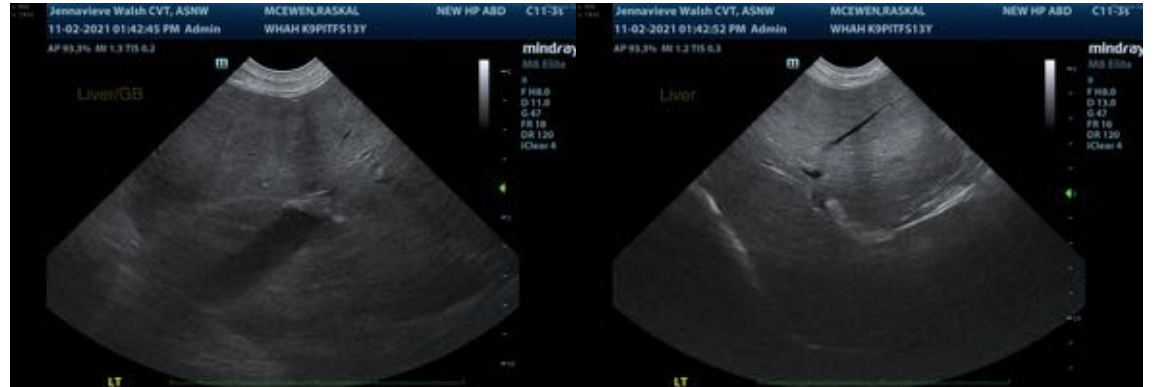
Dr. Fogarty

DATE

11/2/21

INVOICE

12474

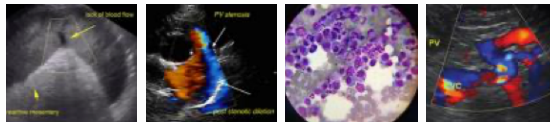


The information and recommendations provided are based on the images presented by the referring veterinarian. No evaluation can be communicated regarding pathology that was not visible in the image/video clips provided.

Thank you for this referral. If the clinical or image interpretation does not parallel your findings or if I can be of any further assistance please contact me.

Andrea Nicastro, DVM, Diplomate ACVIM (Small Animal Internal Medicine)

andrea.nicastro@sonopath.com



PATIENT

Raskal McEwen

SPECIES

Canine

BREED

Pit bull

SEX

Female, spayed

AGE

13 Yrs.

WEIGHT

73.5 lbs.

INTERPRETED BY

Andrea Nicastro, DVM,
Diplomate ACVIM
(*Small Animal Internal
Medicine*)

**IMAGING
PERFORMED BY**

Jenna Walsh

HOSPITAL NAME

West Hills AH

REFERRING VET

Dr. Fogarty

DATE

11/2/21

INVOICE

12474