



PATIENT PRESENTING CLINICAL SIGNS

Nikko Quant History: vomiting, urinating outside of box for 2 weeks

SPECIES

Feline

BREED

DSH

SEX

Neutered Male

AGE

13 years

WEIGHT

13 lbs

INTERPRETED BY

Andrea Nicastro,
DVM, Diplomate
ACVIM (*Small Animal
Internal Medicine*)

IMAGING PERFORMED BY

Jenn

HOSPITAL NAME

Rockaway AH

REFERRING VET

Dr. Maniar

INVOICE

11602

DATE

9.8.22

ULTRASONOGRAPHIC EXAMINATION OF THE ABDOMEN

Urinary System

The **urinary bladder** wall is normal in thickness and the mucosal surface is smooth. The bladder lumen is moderately distended with anechoic urine. No masses, inflammatory changes or calculi are observed. The region of the trigone and the visible portion of the proximal urethra are normal.

The **left kidney** is small in size (2.16 cm in length); with a slightly irregular shape. There is a normal 1:3 cortex to medulla ratio with mild loss of corticomedullary distinction. There is no evidence of pyelectasia, nephroliths, or hydroureter. Renal perfusion appears subnormal.

The **right kidney** is enlarged (5.00 cm in length); with a slightly irregular shape and smooth peripheral contours. The cortex is mildly thickened and hyperechoic. There is poor corticomedullary distinction. One to two small, nephroliths are visualized. There is no evidence of pyelectasia or hydroureter. Renal vasculature is normal.

Adrenal Glands

The region of the **adrenal glands** is evaluated. No obvious pathology is observed.

Spleen

The **spleen** is normal in size (0.82 cm in width at the level of the hilus) with a normal capsular contour. Using the high-frequency probe, the parenchyma appears subtly mottled. No focal lesions are observed. Splenic vasculature is normal.

Liver

The **liver** is subjectively enlarged with irregular peripheral contours. An approximately 6.00 to 6.65 cm heterogenous cystic mass is present on the right side. The lesion causes capsular expansion and displacement of the gall bladder. The remaining parenchyma is homogenous. Hepatic vasculature and intrahepatic biliary tracts are of normal volume with no evidence of congestion.

The **gall bladder** lumen is moderately distended. The wall is thin and smooth. Luminal contents are anechoic. The cystic and common bile ducts are normal/not seen.

Gastrointestinal

The **gastric lumen** is not distended. The gastric wall is normal in thickness with a normal layering pattern. The small intestinal lumen is not dilated. The small intestinal wall thickness is normal with a normal layering pattern and appropriate mural detail. Discreet masses are not identified. The colonic wall is normal. There is no evidence of an obstructive pattern.

Pancreas

The left limb is visible/prominent with normal curvilinear peripheral contours. The parenchyma is slightly hypoechoic relative to surrounding omental fat. No focal lesions are observed. The pancreatic duct is visible, but not overtly dilated.

Free Abdomen

The **peritoneal cavity** is normal. There is no evidence of inflammation or effusion. The abdominal **lymph nodes** are normal/not visible.

ULTRASONOGRAPHIC FINDINGS

Primary Findings

- Large, right cystic hepatic mass. Differentials include biliary cystadenocarcinoma, cystadenoma, other.
- It is unclear if the hepatic mass is causing the patient's clinical signs or if a concurrent disease process is present.

Secondary Findings

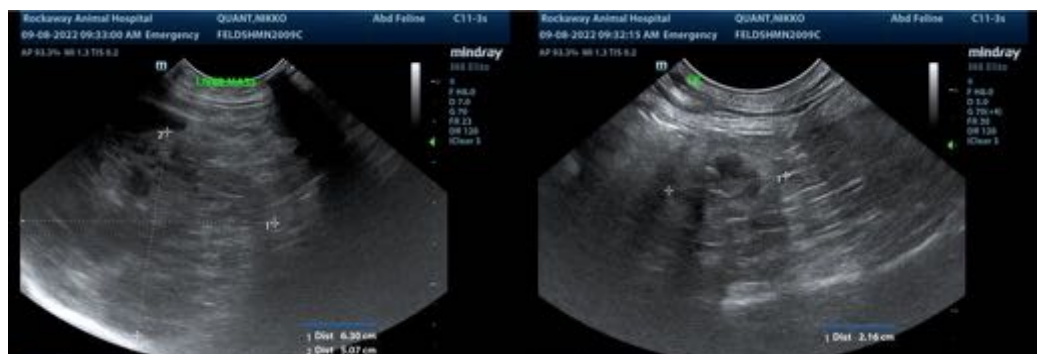- Bilateral degenerative renal changes. The right renomegaly may be secondary to compensatory hypertrophy resulting from an atrophied left kidney. A nonobstructive nephrolith is visualized in the right kidney.
- The splenic parenchymal changes are most consistent with a benign process such as lymphoid hyperplasia, extramedullary hematopoiesis, splenitis or antigenic stimulation with a low possibility of infiltrative neoplasia (i.e., lymphoma, mast cell neoplasia).
- The pancreatic changes may be a normal variant for this patient or could be consistent with mild, chronic pancreatitis. Correlation with clinical findings is recommended.

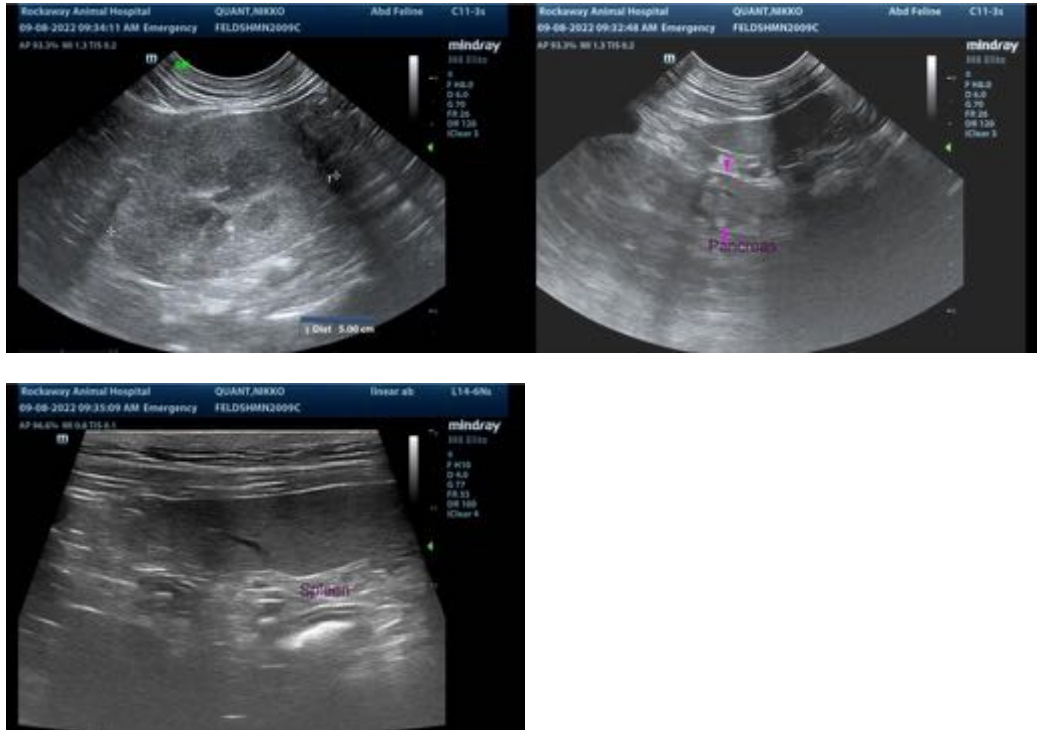
INTERPRETATION OF THE FINDINGS & FURTHER RECOMMENDATIONS

Baseline lab work, including CBC, Chemistry panel, urinalysis and T4 is recommended, along with a urine culture and sensitivity.

Three-view thoracic radiographs are also recommended to assess for pulmonary metastatic disease.

If an aggressive approach is desired, consider consultation with a board-certified surgeon to discuss mass removal or debulking. An abdominal CT scan would be useful in presurgical planning.





The information and recommendations provided are based on the images presented by the referring veterinarian/sonographer. No evaluation can be communicated regarding pathology that was not visible in the image/video clips provided.

Thank you for this referral. If the clinical or image interpretation does not parallel your findings or if I can be of any further assistance, please contact me.

Andrea Nicastro, MPH, DVM, Diplomate DACVIM (Small Animal Internal Medicine)
info@SonoPath.com