



PATIENT PRESENTING CLINICAL SIGNS

Odin Priscu History: V+ past two days, Patient has not eaten in 2 days. Suspect gastric FB on X-ray.

Abnormal PE/Chem/CBC/UA Results: HCT 61.88

SPECIES

Canine

ULTRASONOGRAPHIC EXAMINATION OF THE ABDOMEN

Urinary System

BREED

Husky

The urinary bladder, trigone, and pelvic urethra are normal in thickness and the mucosal surface is smooth. The bladder lumen is moderately distended. A small amount of suspended echogenic debris, some of which is aggregated, is observed within the lumen. No masses, inflammatory changes or calculi are observed. Ureteral papillae and visualized portion of the proximal urethra, visible to a depth of 2 cm, are normal.

SEX

The prostate is not definitively visualized due to its pelvic location.

Male Neutered

The left kidney is normal size (7.06 cm in length); normal shape and architecture with smooth peripheral margins. There is a normal 1:3 cortex to medulla ratio with normal corticomedullary distinction. There is no evidence of pyelectasia, nephroliths, infarcts or hydroureter. Renal vasculature is normal.

AGE

5 years

The right kidney is normal size (6.04 cm in length); normal shape and architecture with smooth peripheral margins. There is a normal 1:3 cortex to medulla ratio with normal corticomedullary distinction. There is no evidence of pyelectasia, nephroliths, infarcts or hydroureter. Renal vasculature is normal.

WEIGHT

68 lbs.

Adrenal Glands

The left adrenal gland is normal size (0.89 cm at cranial pole) (0.51 cm at caudal pole) (3.37 cm in length); normal shape; homogenous parenchyma. The glandular echogenicity and detail are unremarkable. Capsule, cortex, and medullary definition are normal. The phrenicoabdominal vein and surrounding vasculature are normal.

INTERPRETED BY

Andrea Nicastro, DVM,
Diplomate ACVIM
(Small Animal Internal
Medicine)

The right adrenal gland is normal size (0.66 cm at cranial pole) (0.77 cm at caudal pole) (1.88 cm in length); normal shape; homogenous parenchyma. The glandular echogenicity and detail are unremarkable. Capsule, cortex, and medullary definition are normal. The phrenicoabdominal vein and surrounding vasculature are normal.

IMAGING PERFORMED BY

Jessica Miller

Spleen

The spleen is normal in size (1.32 cm in width at the level of the hilus) with a normal capsular contour. There is appropriate echogenicity and echotexture. No focal lesions are observed. Splenic vasculature is normal.

HOSPITAL NAME

Basking Ridge Animal
Hospital

Liver

The liver is subjectively normal in size with normal contours and structure. There is appropriate echogenicity and echotexture. No overt structural evidence of inflammatory, infiltrative, or regenerative pathology is evident. Vascular and biliary tracts are of normal volume with no evidence of congestion. No pathological hepatic lymphadenopathy observed. The gallbladder is of normal contours and contains some dependent echogenic debris. The wall is normal in thickness. No choleliths are observed. The cystic and common bile ducts are normal.

REFERRING VET

Dr. Ulassin

INVOICE 12044

Gastrointestinal

The gastric lumen is severely fluid distended and hypomotile. Within the lumen, echogenic to hyperechoic debris, some of which is aggregated, as well as some gas is observed within the lumen. Several small intestinal loops are mildly to moderately fluid distended and hypomotile. Within one segment, which is thought to be small intestine, a 2.56 cm shadowing structure is visualized. In other segments, the small intestinal lumen is not

DATE 9/8/21



PATIENT

Odin Priscu

dilated. The small intestinal wall thickness is normal with a normal layering pattern and appropriate mural detail. Discreet masses are not identified. The colonic wall is normal.

Pancreas

SPECIES

Canine

No obvious abnormalities are observed in the region of the left limb. See also *Free Abdomen*.

Free Abdomen

BREED

Husky

A few prominent mesenteric lymph nodes are visualized. The mesentery in the right cranial quadrant is hyperechoic. There is questionable trace free fluid.

ULTRASONOGRAPHIC FINDINGS

Primary Findings:

- Gastric and proximal small intestinal hypomotility with suspected obstructive pattern and possible small intestinal foreign body. Regional peritonitis.

Secondary Findings:

- The lymph node changes are most consistent with reactive lymphadenitis or lymphoid hyperplasia.
- Urinary bladder debris.

SEX

Male Neutered

AGE

5 years

WEIGHT

68 lbs.

INTERPRETATION OF THE FINDINGS & FURTHER RECOMMENDATIONS

- Three-view thoracic radiographs are recommended to assess for occult aspiration pneumonia.
- If an aggressive approach is desired, consider an abdominal exploratory to assess for a small intestinal obstruction. If a more conservative approach is desired, consider a repeat sonogram in 12 hours. If findings are similar, consider surgery at that time. If surgery is pursued but a foreign body/obstruction is not seen, gastrointestinal biopsies should be obtained.

INTERPRETED BY

Andrea Nicastro, DVM,
Diplomate ACVIM
(Small Animal Internal
Medicine)

IMAGING PERFORMED BY

Jessica Miller

HOSPITAL NAME

Basking Ridge Animal
Hospital

REFERRING VET

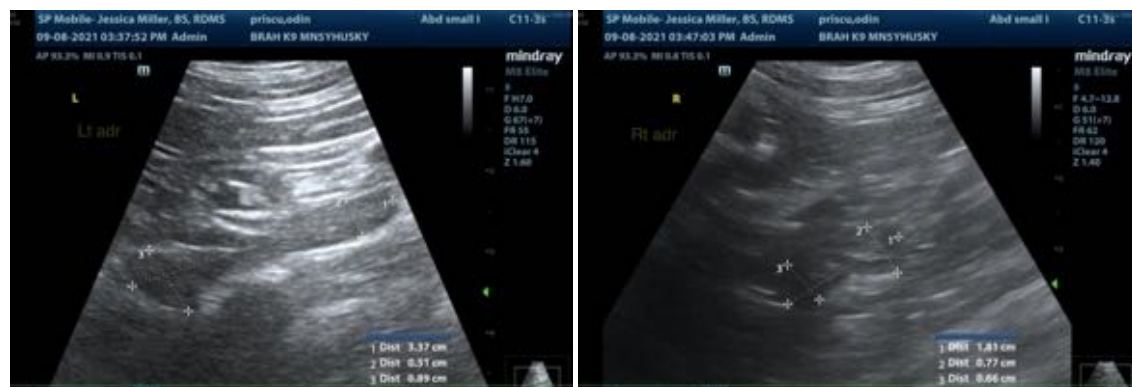
Dr. Ulassin

INVOICE

12044

DATE

9/8/21





PATIENT

Odin Prisco

SPECIES

Canine

BREED

Husky

SEX

Male Neutered

AGE

5 years

WEIGHT

68 lbs.

INTERPRETED BY

Andrea Nicastro, DVM,
Diplomate ACVIM
(Small Animal Internal
Medicine)

IMAGING PERFORMED BY

Jessica Miller

HOSPITAL NAME

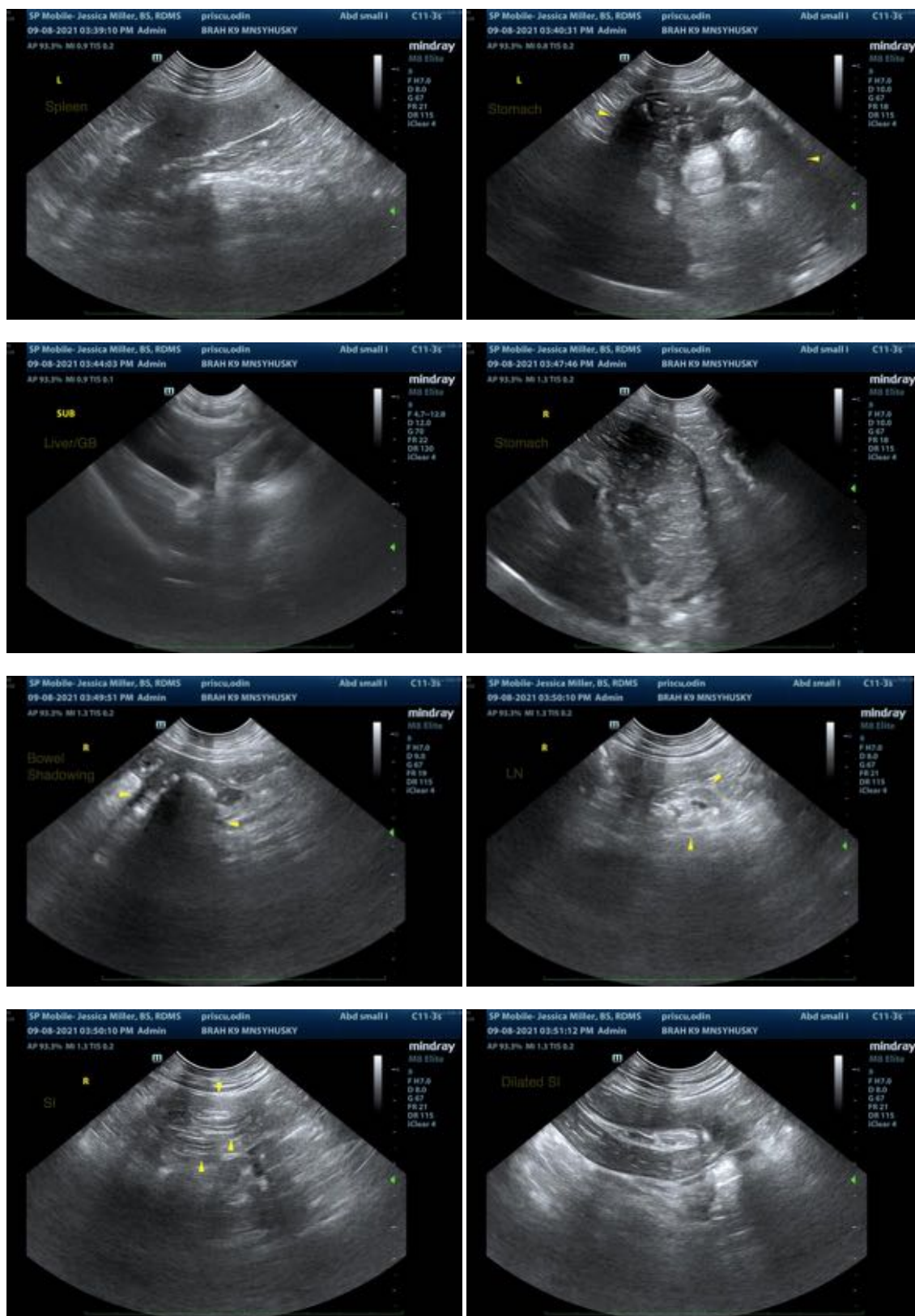
Basking Ridge Animal
Hospital

REFERRING VET

Dr. Ulassin

INVOICE
12044

DATE
9/8/21





PATIENT

Odin Priscu

SPECIES

Canine

BREED

Husky

SEX

Male Neutered

AGE

5 years

WEIGHT

68 lbs.

INTERPRETED BY

Andrea Nicastro, DVM,
Diplomate ACVIM
(*Small Animal Internal
Medicine*)

**IMAGING
PERFORMED BY**

Jessica Miller

HOSPITAL NAME

Basking Ridge Animal
Hospital

REFERRING VET

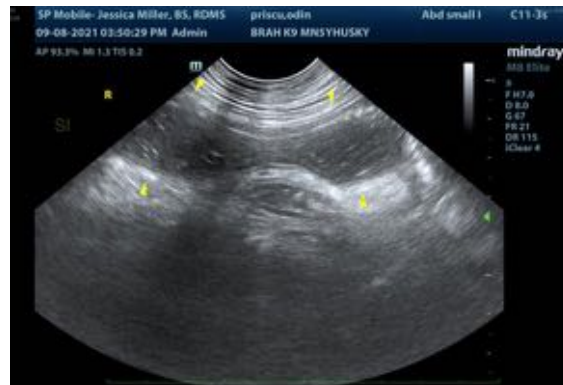
Dr. Ulassin

INVOICE

12044

DATE

9/8/21



The information and recommendations provided are based on the images presented by the referring veterinarian. No evaluation can be communicated regarding pathology that was not visible in the image/video clips provided.

Thank you for this referral. If the clinical or image interpretation does not parallel your findings or if I can be of any further assistance, please contact me.

Andrea Nicastro, DVM, Diplomate ACVIM (*Small Animal Internal Medicine*)
Andrea.nicastro@sonopath.com