



**PATIENT**

Nina Lopez

**PRESENTING CLINICAL SIGNS**

History: Mild elevation of SDMA (18) and BUN (38) with normal creatinine (2.1).

Abnormal PE/Chem/CBC/UA Results: USG: 1.020.

**SPECIES**

Feline

**ULTRASONOGRAPHIC EXAMINATION OF THE ABDOMEN**

*Urinary System*

**BREED**

Domestic Shorthair

The urinary bladder, trigone, and pelvic urethra are normal in thickness and the mucosal surface is smooth. The bladder lumen is moderately distended with anechoic urine. No masses, inflammatory changes or calculi are observed. Ureteral papillae and visualized portion of the proximal urethra, visible to a depth of 2 cm, are normal.

**SEX**

Female Spayed

The left kidney is small in size (2.85 cm in length) with a normal shape and smooth peripheral contours. There is a normal 1:3 cortex to medulla ratio with poor corticomedullary distinction. There is no evidence of pyelectasia, nephroliths, infarcts or hydroureter. Renal vasculature is normal.

**AGE**

10 years

The right kidney is small in size (3.30 cm in length) with a normal shape and smooth peripheral contours. There is a normal 1:3 cortex to medulla ratio with poor corticomedullary distinction. A 0.50 cm cortical cyst is observed at the craniolateral aspect. There is no evidence of pyelectasia, nephroliths, infarcts or hydroureter. Renal vasculature is normal.

**WEIGHT**

11.4 lbs.

*Adrenal Glands*

The left adrenal gland is normal size (0.39 cm width). Normal shape and glandular echogenicity. The phrenicoabdominal vein and surrounding vasculature are normal.

The region of the right adrenal gland is evaluated. No obvious pathology is observed in this region.

**INTERPRETED BY**

Andrea Nicastro, DVM,  
Diplomate ACVIM  
(Small Animal Internal  
Medicine)

*Spleen*

The spleen is normal in size (0.69 cm in width at the level of the hilus) with a normal capsular contour. There is appropriate echogenicity and echotexture. No focal lesions are observed. Splenic vasculature is normal.

**IMAGING PERFORMED BY**

Kelly Vazquez, CVT

*Liver*

The liver is subjectively normal in size with normal contours and structure. There is appropriate echogenicity and echotexture. No overt structural evidence of inflammatory, infiltrative, or regenerative pathology is evident. Vascular and biliary tracts are of normal volume with no evidence of congestion. No pathological hepatic lymphadenopathy observed. The gall bladder lumen is mildly distended. The wall is thin and smooth. Luminal contents are anechoic. The cystic and common bile ducts are normal/not seen.

**HOSPITAL NAME**

Englewood Vet Center

*Gastrointestinal*

The stomach and intestine are free of stasis and exhibit normal peristaltic activity. The gastric lumen is not distended. The gastric wall and pylorus are normal in thickness with a normal layering pattern. The pyloric outflow tract is patent. The small intestinal lumen is not dilated. The small intestinal wall thickness is normal with a normal layering pattern and appropriate mural detail. Discreet masses are not identified. The colonic wall is normal. No obstructive disease is noted.

**REFERRING VET**

Dr. Ezik

*Pancreas*

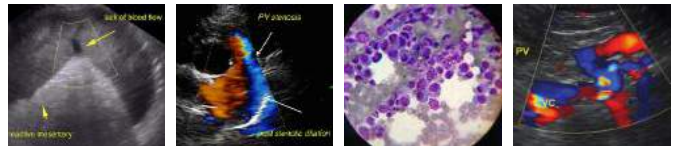
The pancreas in the region of the left limb is isoechoic relative to surrounding omental fat. See also "Free Abdomen" category.

**INVOICE**

11779kk

**DATE**

9/8/21



**PATIENT**

**Free Abdomen**

Nina Lopez

A 2.82 x 2.39 cm irregular, hyperechoic lesion is observed in the right cranial quadrant. No free fluid is observed. The abdominal lymph nodes are normal/not visible.

**SPECIES**

Feline

**ULTRASONOGRAPHIC FINDINGS**

- Non-specific, bilateral, age-related renal pathology.
- The origin of the hyperechoic lesion in the right cranial quadrant is unclear. It is suspected to represent reactive mesentery. However, a hyperechoic lesion arising from pancreas, liver, and other is also possible.

**BREED**

Domestic Shorthair

**INTERPRETATION OF THE FINDINGS & FURTHER RECOMMENDATIONS**

**SEX**

Female Spayed

1. Given the azotemia, consider the following:

- Urine culture and sensitivity.
- UPC (if proteinuria is present)
- Baseline blood pressure measurement.
- Transition to a prescription renal diet if the patient will tolerate it.
- Serial monitoring of the patient's renal values and blood pressure.

**AGE**

10 years

2. Regarding the hyperechoic lesion in the right cranial quadrant:

- A fine needle aspirate can be considered (if clotting status is appropriate). A 25-gauge needle should be used. Alternatively, consider a repeat ultrasound in 3-4 weeks to assess for progression/resolution.
- A PLI may also be useful in further evaluating for pancreatitis.

**WEIGHT**

11.4 lbs.

**INTERPRETED BY**

Andrea Nicastro, DVM,  
Diplomate ACVIM  
(Small Animal Internal  
Medicine)

**IMAGING PERFORMED BY**

Kelly Vazquez, CVT

**HOSPITAL NAME**

Englewood Vet Center

**REFERRING VET**

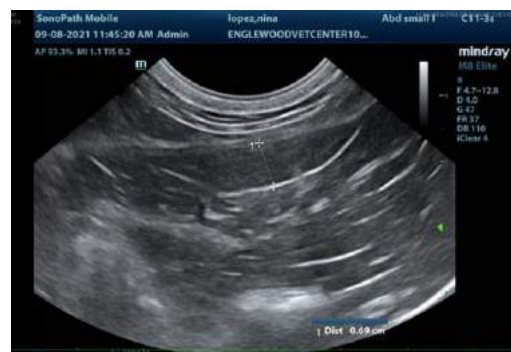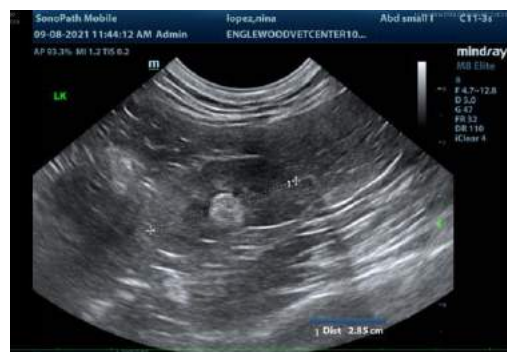Dr. Ezik

**INVOICE**

11779kk

**DATE**

9/8/21





**PATIENT**

Nina Lopez

**SPECIES**

Feline

**BREED**

Domestic Shorthair

**SEX**

Female Spayed

**AGE**

10 years

**WEIGHT**

11.4 lbs.

**INTERPRETED BY**

Andrea Nicastro, DVM,  
Diplomate ACVIM  
(Small Animal Internal  
Medicine)

**IMAGING PERFORMED BY**

Kelly Vazquez, CVT

**HOSPITAL NAME**

Englewood Vet Center

**REFERRING VET**

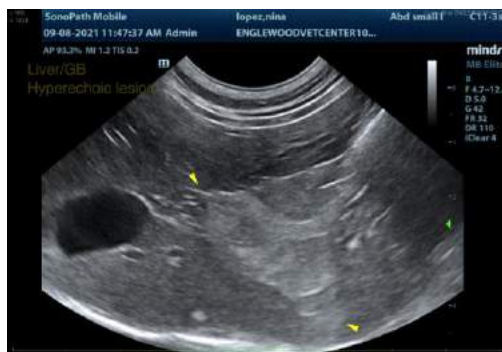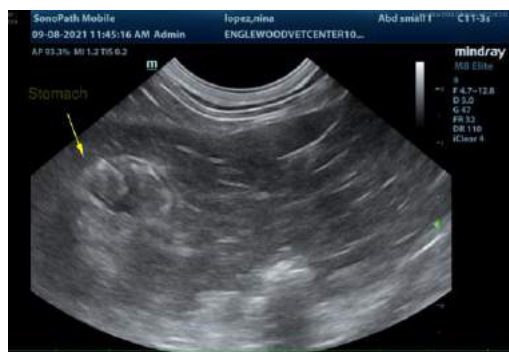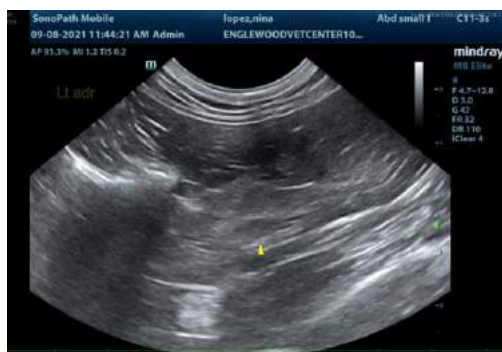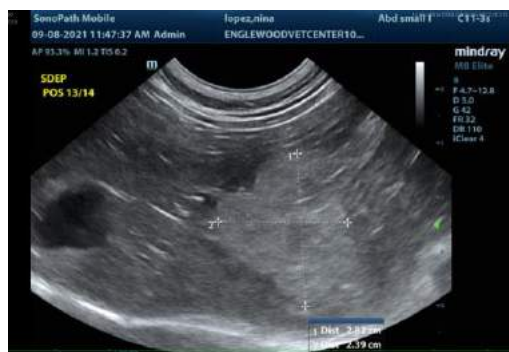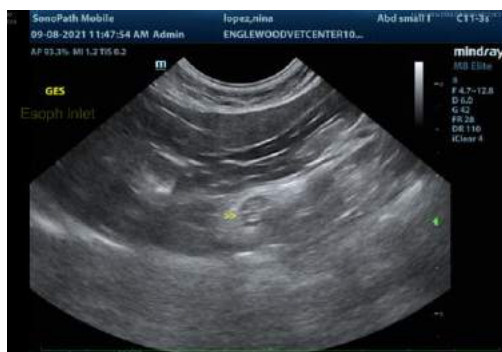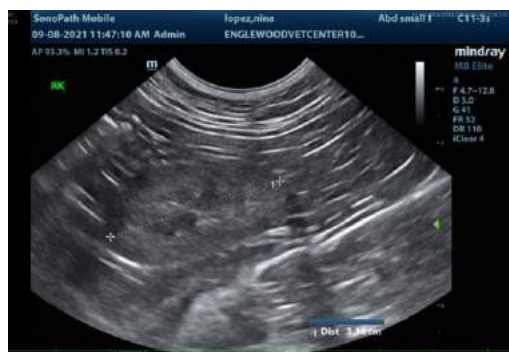Dr. Ezik

**INVOICE**

11779kk

**DATE**

9/8/21



The information and recommendations provided are based on the images presented by the referring veterinarian. No evaluation can be communicated regarding pathology that was not visible in the image/video clips provided.

Thank you for this referral. If the clinical or image interpretation does not parallel your findings or if I can be of any further assistance, please contact me.

Andrea Nicastro, DVM, Diplomate ACVIM (Small Animal Internal Medicine)  
Andrea.nicastro@sonopath.com