



PATIENT

Finn Yuen

PRESENTING CLINICAL SIGNS

History: Suspicious opacity on rads, Nausea and Vomiting, blood on rectal. No current meds.

Abnormal PE/Chem/CBC/UA Results: WNL

SPECIES

Canine

ULTRASONOGRAPHIC EXAMINATION OF THE ABDOMEN

Urinary System

BREED

Golden Doodle

The urinary bladder, trigone, and pelvic urethra are normal in thickness and the mucosal surface is smooth. The bladder lumen is moderately distended with anechoic urine. No masses, inflammatory changes or calculi are observed. Ureteral papillae and visualized portion of the proximal urethra, visible to a depth of 2 cm, are normal.

SEX

Male Neutered

The prostate is not definitively visualized due to its pelvic location.

AGE

1.5 years

The left kidney is normal size (5.42 cm in length); normal shape and architecture with smooth peripheral margins. There is a normal 1:3 cortex to medulla ratio with normal corticomedullary distinction. There is no evidence of pyelectasia, nephroliths, infarcts or hydronephrosis. Renal vasculature is normal.

WEIGHT

42 lbs.

The right kidney is normal size (5.92 cm in length); normal shape and architecture with smooth peripheral margins. There is a normal 1:3 cortex to medulla ratio with normal corticomedullary distinction. There is no evidence of pyelectasia, nephroliths, infarcts or hydronephrosis. Renal vasculature is normal.

Adrenal Glands

INTERPRETED BY

Andrea Nicastro, DVM,
Diplomate ACVIM
(Small Animal Internal
Medicine)

The left adrenal gland is normal size (0.47 cm at cranial pole) (0.60 cm at caudal pole) (2.04 cm in length); normal shape; homogenous parenchyma. The glandular echogenicity and detail are unremarkable. Capsule, cortex, and medullary definition are normal. The phrenicoabdominal vein and surrounding vasculature are normal.

The right adrenal gland is normal size (1.04 cm at cranial pole) (0.52 cm at caudal pole) (2.47 cm in length); normal shape; homogenous parenchyma. The glandular echogenicity and detail are unremarkable. Capsule, cortex, and medullary definition are normal. The phrenicoabdominal vein and surrounding vasculature are normal.

IMAGING PERFORMED BY

Jessica Miller

Spleen

HOSPITAL NAME

Basking Ridge AH

The spleen is normal in size (1.90 cm in width at the level of the hilus) with a normal capsular contour. There is appropriate echogenicity and echotexture. No focal lesions are observed. Splenic vasculature is normal.

REFERRING VET

Dr. Piehler

Liver

The liver is subjectively normal in size with normal contours and structure. There is appropriate echogenicity and echotexture. No overt structural evidence of inflammatory, infiltrative, or regenerative pathology is evident. Vascular and biliary tracts are of normal volume with no evidence of congestion. No pathological hepatic lymphadenopathy observed. The gall bladder lumen is moderately distended. The wall is thin and smooth. Luminal contents are anechoic. The cystic and common bile ducts are normal/not seen.

INVOICE
11778kk

Gastrointestinal

DATE

9/8/21



PATIENT

Finn Yuen

SPECIES

Canine

BREED

Golden Doodle

SEX

Male Neutered

AGE

1.5 years

WEIGHT

42 lbs.

The stomach and intestine are free of stasis and exhibit normal peristaltic activity. The gastric lumen is not distended. The gastric wall and pylorus are normal in thickness with a normal layering pattern. The pyloric outflow tract is patent. The small intestinal lumen is not dilated. The small intestinal wall is normal in thickness with a normal layering pattern and appropriate mural detail. There is slight disruption in the normal 1:3 muscularis to mucosal ratio in some segments. Discreet masses are not identified. The ileocolic junction and colonic wall are normal. The lumen of the descending colon is gas-distended. There is no evidence of obstruction.

Pancreas

The region of the pancreas is isoechoic relative to surrounding omental fat. No obvious parenchymal abnormalities are observed. There is no evidence of regional inflammation or effusion.

Free Abdomen

The peritoneal cavity is normal. There is no evidence of inflammation or effusion. A few prominent mesenteric lymph nodes are visualized, the largest measuring 4.75 cm in length.

ULTRASONOGRAPHIC FINDINGS

- Bowel pattern consistent with inflammatory bowel disease with potential for emerging lymphoma.
- The prominent abdominal lymph nodes are most consistent with reactive lymphadenitis or lymphoid hyperplasia. Neoplastic infiltration is considered less likely.

**There is no obvious evidence of foreign body/obstruction.

INTERPRETATION OF THE FINDINGS & FURTHER RECOMMENDATIONS

1. A fecal evaluation for ova/Giardia
2. Prophylactic deworming with Fenbendazole at 50 mg/kg once a day for 5 days is recommended. Repeat above protocol in 3 weeks.
3. Three-view thoracic radiographs are recommended to assess for occult esophageal dysfunction.
4. Supportive care for acute gastroenteritis is recommended.
5. If gastrointestinal signs persist or recur, consider a more advanced GI work up, which could include the following:
 - a. A malabsorption panel including serum cobalamin, folate, PLI and TLI.
 - b. A resting cortisol level to screen for hypoadrenocorticism. If resting cortisol level is < 2.0 mcg/dL, an ACTH stimulation test is recommended.
 - c. Pre- and post-prandial serum bile acids to assess for occult hepatic dysfunction
 - d. +/- endoscopic or surgical gastrointestinal biopsies.

INTERPRETED BY

Andrea Nicastro, DVM,
Diplomate ACVIM
(Small Animal Internal
Medicine)

IMAGING PERFORMED BY

Jessica Miller

HOSPITAL NAME

Basking Ridge AH

REFERRING VET

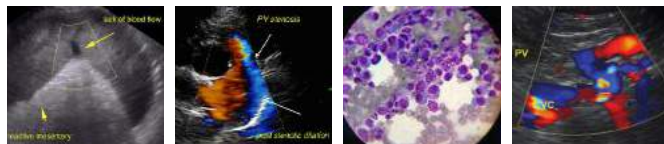
Dr. Piehler

INVOICE

11778kk

DATE

9/8/21



PATIENT

Finn Yuen

SPECIES

Canine

BREED

Golden Doodle

SEX

Male Neutered

AGE

1.5 years

WEIGHT

42 lbs.

INTERPRETED BY

Andrea Nicastro, DVM,
Diplomate ACVIM
(Small Animal Internal
Medicine)

**IMAGING
PERFORMED BY**

Jessica Miller

HOSPITAL NAME

Basking Ridge AH

REFERRING VET

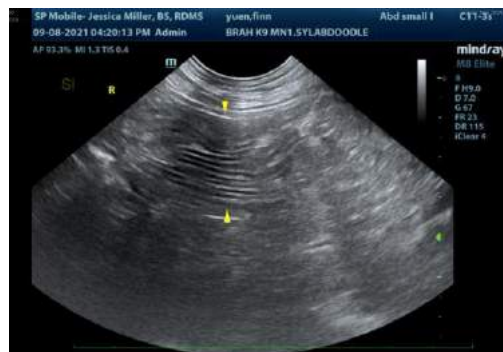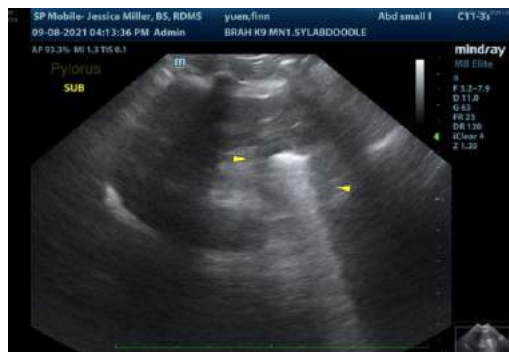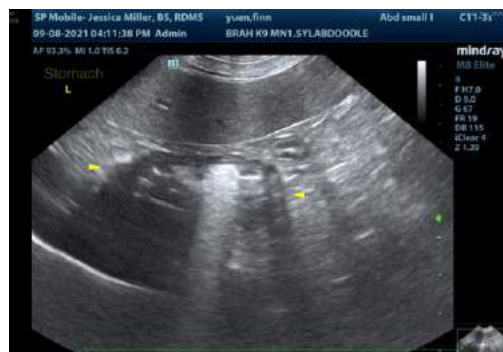
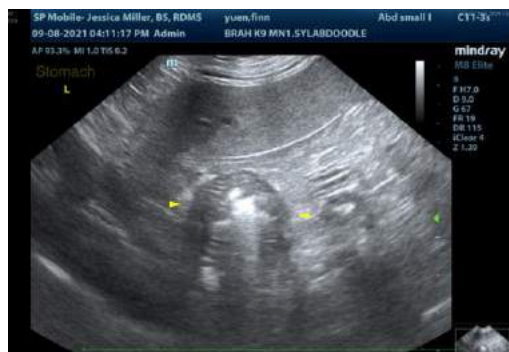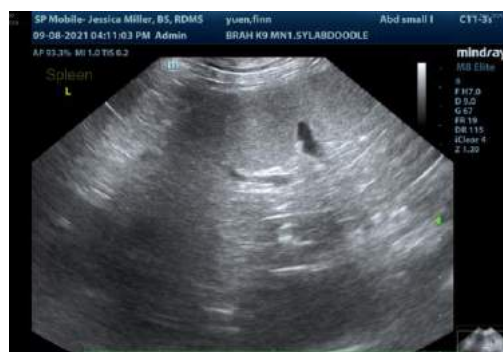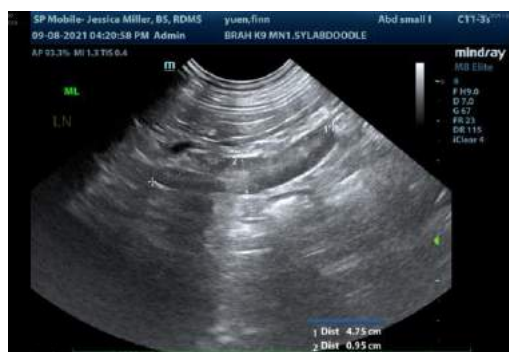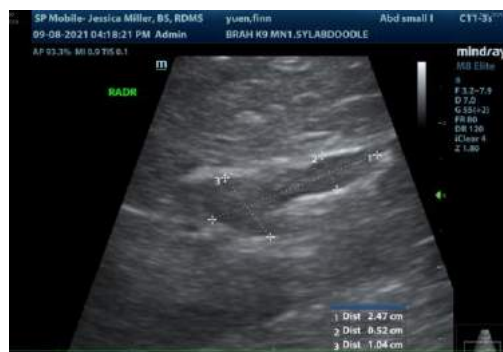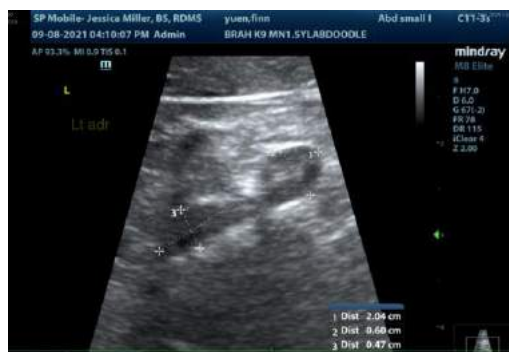Dr. Piehler

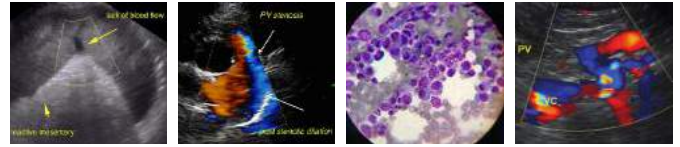
INVOICE

11778kk

DATE

9/8/21





PATIENT

Finn Yuen

SPECIES

Canine

BREED

Golden Doodle

SEX

Male Neutered

AGE

1.5 years

WEIGHT

42 lbs.

INTERPRETED BY

Andrea Nicastro, DVM,
Diplomate ACVIM
(*Small Animal Internal
Medicine*)

**IMAGING
PERFORMED BY**

Jessica Miller

HOSPITAL NAME

Basking Ridge AH

REFERRING VET

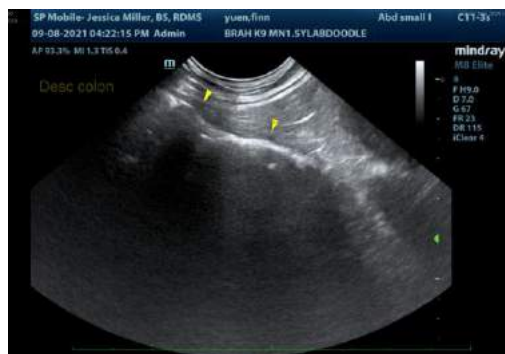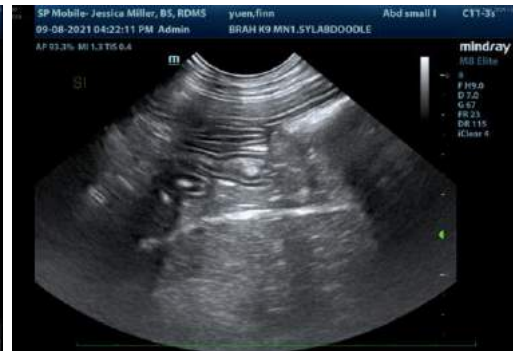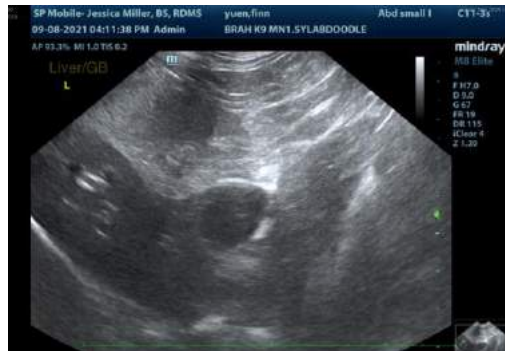Dr. Piehler

INVOICE

11778kk

DATE

9/8/21



The information and recommendations provided are based on the images presented by the referring veterinarian. No evaluation can be communicated regarding pathology that was not visible in the image/video clips provided.

Thank you for this referral. If the clinical or image interpretation does not parallel your findings or if I can be of any further assistance, please contact me.

Andrea Nicastro, DVM, Diplomate ACVIM (*Small Animal Internal Medicine*)
Andrea.nicastro@sonopath.com