

**DATE PRESENTING CLINICAL SIGNS**

9/7/21

History: Patient presents for history of complicated UTI - most recent UTI cleared but patient has persistent hematuria.

PATIENT

Lily Zimmerman

Current Medications: Treated UTI with Doxycycline and treated with Rimadyl - on Trazodone for scan. Lab Results: USG 1.037, 3+ proteinuria with blood and white cells on urinalysis on 8/6. Calcium oxalate crystals. Urine culture 1 month ago was negative following treatment for UTI. Triple phosphate crystals. CBC chem in June of 2021 WNL. T4 normal.

SPECIES

Canine

Radiographs: Not provided by the veterinarian.
 Date of Previous IntraPet Ultrasound: No previous IntraPet scans.
 Sedation: Sedation not required for scan.
 Stat Report: STAT report not requested by the veterinarian.

BREED

Bichon

ULTRASONOGRAPHIC EXAMINATION OF THE ABDOMEN**SEX**

Female, spayed

Urinary System

The urinary bladder is mildly distended. The wall in the craniodorsal and cranioventral aspects is heterogeneous, thickened (up to 0.96 cm) and irregular with foci of mineralization within the wall. A small amount of mineralized sand and a scant amount of suspended echogenic debris is present within the lumen. The region of the trigone and the visible portion of the proximal urethra are normal.

AGE

4/26/2014

The left kidney is normal in size (4.26 cm in length) with a normal shape, smooth peripheral margins and normal internal architecture. There is mild loss of corticomedullary distinction. Several hyperechoic shadowing diverticular foci are observed. A few small nephroliths are present. There is no evidence of pyelectasia, infarcts or hydroureter.

WEIGHT

14 lbs.

The right kidney is normal in size (4.61 cm in length) with a normal shape, smooth peripheral margins and normal internal architecture. There is mild loss of corticomedullary distinction. Several hyperechoic shadowing diverticular foci are observed. A few small nephroliths are present. There is no evidence of pyelectasia, infarcts or hydroureter.

INTERPRETED BY

Andrea Nicastro, DVM,
 Diplomate ACVIM
 (Small Animal Internal
 Medicine)

Adrenal Glands

The left adrenal gland is normal size (0.36 cm at cranial pole) (0.43 cm at caudal pole) (1.33 cm in length); normal shape; homogenous parenchyma. The glandular echogenicity and detail are unremarkable. Capsule, cortex, and medullary definition are normal. The phrenicoabdominal vein and surrounding vasculature are normal.

HOSPITAL NAME

Perry Hall AH

The right adrenal gland is normal size (0.54 cm at cranial pole) (0.50 cm at caudal pole) (1.51 cm in length); normal shape; homogenous parenchyma. The glandular echogenicity and detail are unremarkable. Capsule, cortex, and medullary definition are normal. The phrenicoabdominal vein and surrounding vasculature are normal.

REFERRING VET

Dr. Miller

Spleen

The spleen is normal in size (1.61 cm in width at the level of the hilus) with a normal capsular contour. There is appropriate echogenicity and echotexture. No focal lesions are observed. Splenic vasculature is normal.

INVOICE

12032

Liver

The liver is subjectively normal in size with normal contours and structure. There is appropriate echogenicity and echotexture. No overt structural evidence of inflammatory, infiltrative or regenerative pathology is evident. Vascular and biliary tracts are of normal volume with no evidence of congestion. No pathological hepatic lymphadenopathy observed. The gall bladder is not visualized in its entirety. In the visualized portion,

the wall is normal in thickness. A scant amount of echogenic debris is seen. The cystic and common bile ducts are normal/not visualized.

Gastrointestinal

The stomach and intestine are free of stasis and exhibit normal peristaltic activity. The gastric lumen is not distended. The gastric wall and pylorus are normal in thickness with a normal layering pattern. The pyloric outflow tract is patent. The small intestinal lumen is not dilated. The small intestinal wall thickness is normal with a normal layering pattern and appropriate mural detail. Discreet masses are not identified. The colonic wall is normal. No obstructive disease is noted.

Pancreas

The right limb of the pancreas is visible with normal curvilinear peripheral contours. The parenchyma is largely isoechoic relative to surrounding omental fat and slightly mottled in appearance. The pancreatic duct is visible but not overtly dilated. There is no evidence of peripancreatic inflammation or effusion.

Free Abdomen

The peritoneal cavity is normal. There is no evidence of inflammation or effusion. The abdominal lymph nodes are normal/not visible.

ULTRASONOGRAPHIC FINDINGS

Primary Findings:

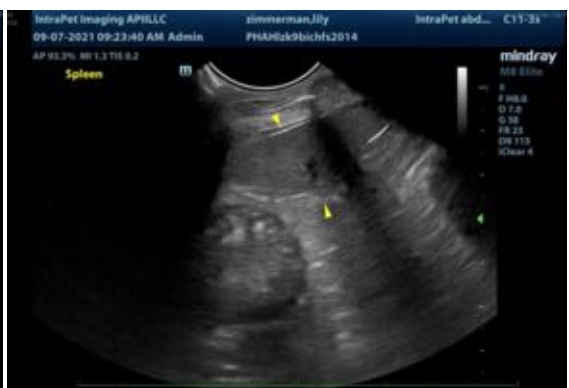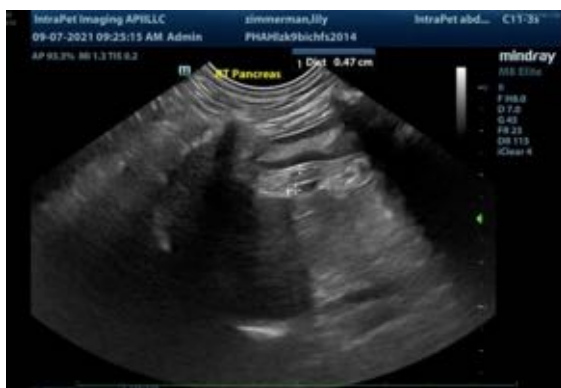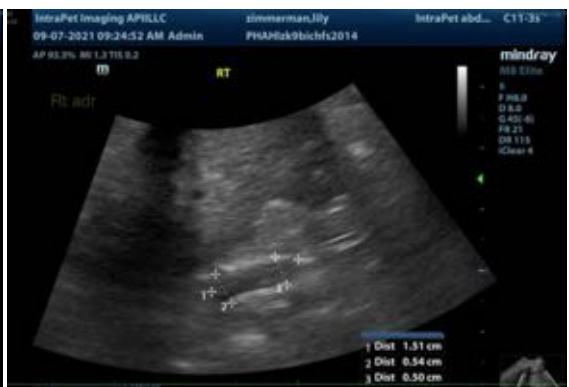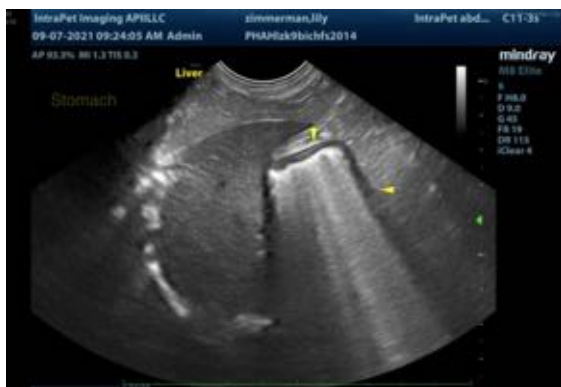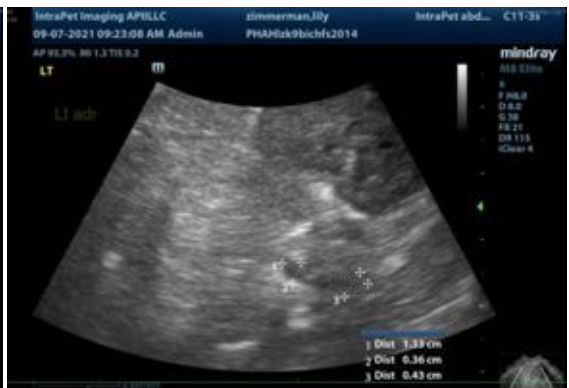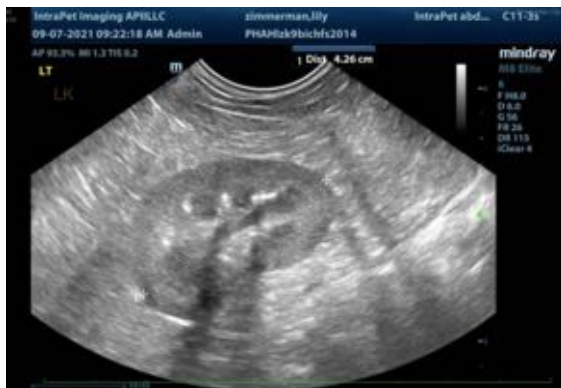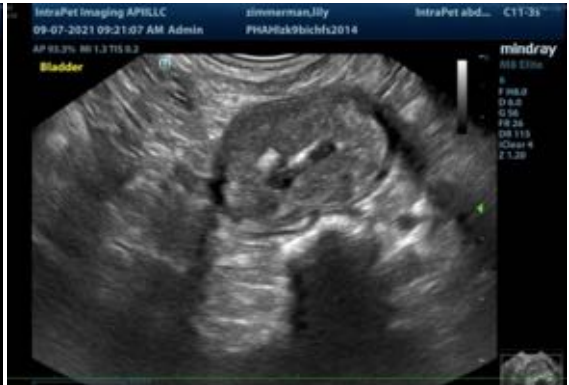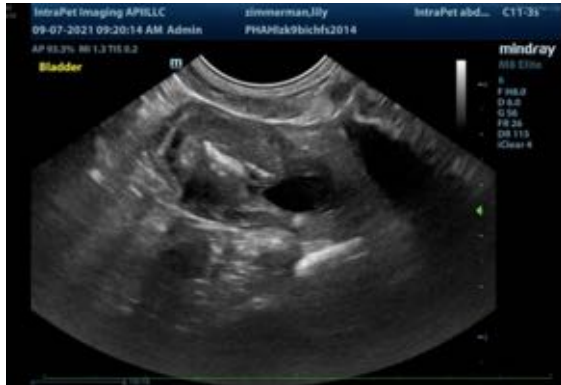- The bladder wall changes could be consistent with cystitis or infiltrative neoplasia (i.e., transitional cell carcinoma). Mineralized sand without obvious distinct cystic calculi.
- Bilateral age-related renal changes with non-obstructive nephroliths and dystrophic mineralization.

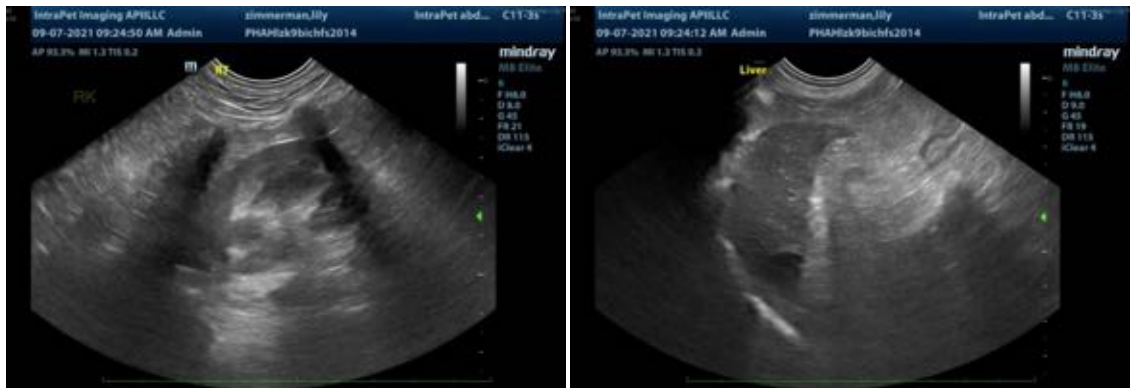
Secondary Findings:

- The pancreatic changes are most consistent with age-related parenchymal remodeling, potentially secondary to a prior inflammatory episode, early fibrosis or chronic pancreatitis.

INTERPRETATION OF THE FINDINGS & FURTHER RECOMMENDATIONS

- Consider a urine BRAF test to further assess for bladder neoplasia.
- Abdominal radiographs may be useful in determining if distinct cystic calculi are present, although none are seen sonographically.
- Consider a repeat urine culture and sensitivity +/- an extended sensitivity panel (if warranted). If an infection is present, a prolonged course of antibiotics (based on the urine culture results) may be warranted given the patient's history. ***Note: Occult pyelonephritis may be present. Therefore, if the culture is negative, consider empirical antibiotic treatment with serial monitoring of the patient's urine to determine if the hematuria improves.





The information and recommendations provided are based on the images presented by the referring veterinarian. No evaluation can be communicated regarding pathology that was not visible in the image/video clips provided.

Thank you for this referral. If the clinical or image interpretation does not parallel your findings or if I can be of any further assistance please contact me.

Andrea Nicastro, DVM, Diplomate ACVIM (*Small Animal Internal Medicine*)
Andrea.nicastro@sonopath.com