



**PATIENT**

Coffee Nastase

**SPECIES**

Canine

**BREED**

Yorkshire Terrier

**SEX**

Male Neutered

**AGE**

8 Years 9 Months

**WEIGHT**

22.2 lbs.

**INTERPRETED BY**

Andrea Nicastro, DVM,  
Diplomate ACVIM  
(Small Animal Internal  
Medicine)

**IMAGING  
PERFORMED BY**

Potomac Mobile  
Veterinary Ultrasound

**HOSPITAL NAME**

Banfield Leesburg

**REFERRING VET**

Dr. Jarrett

**INVOICE**

12039

**DATE**

9/7/21

**PRESENTING CLINICAL SIGNS**

History: Asymptomatic. Was given Denamarin and Actigall last year when the gall bladder changes were seen. The dog seemed to do better at the time. Doing OK now, but liver values are a bit elevated, client a bit concerned.

Abnormal PE/Chem/CBC/UA Results: 8/31/21- ALP 417, glob 4.6, Tbili 1.0, TP 8.6

**ULTRASONOGRAPHIC EXAMINATION OF THE ABDOMEN**

*Urinary System*

The urinary bladder, trigone, and pelvic urethra are normal in thickness and the mucosal surface is smooth. The bladder lumen is moderately distended with mostly anechoic urine. No masses, inflammatory changes or calculi are observed. Ureteral papillae and visualized portion of the proximal urethra, visible to a depth of 2 cm, are normal.

The prostate is not definitively visualized due to its pelvic location.

The left kidney is normal size (4.74 cm in length); normal shape and architecture with smooth peripheral margins. There is a normal 1:3 cortex to medulla ratio with minimal loss of corticomedullary distinction. There is no evidence of pyelectasia, nephroliths, infarcts or hydronephrosis. Renal vasculature is normal.

The right kidney is normal size (5.03 cm in length); normal shape and architecture with smooth peripheral margins. There is a normal 1:3 cortex to medulla ratio with minimal loss of corticomedullary distinction. There is no evidence of pyelectasia, nephroliths, infarcts or hydronephrosis. Renal vasculature is normal.

*Adrenal Glands*

The left adrenal gland is normal size (0.51 cm at cranial pole) (0.52 cm at caudal pole) (1.73 cm in length); normal shape; homogenous parenchyma. The glandular echogenicity and detail are unremarkable. Capsule, cortex, and medullary definition are normal. The phrenicoabdominal vein and surrounding vasculature are normal.

The right adrenal gland is normal size (0.62 cm at cranial pole) (0.43 cm at caudal pole) (1.92 cm in length); normal shape; homogenous parenchyma. The glandular echogenicity and detail are unremarkable. Capsule, cortex, and medullary definition are normal. The phrenicoabdominal vein and surrounding vasculature are normal.

*Spleen*

The spleen is normal in size (1.89 cm in width at the level of the hilus) with a normal capsular contour. There is appropriate echogenicity and echotexture. A few small hyperechoic nodules are observed. Splenic vasculature is normal.

*Liver*

The liver is subjectively prominent in size with normal curvilinear peripheral contours. The parenchyma is isoechoic relative to the spleen with minor changes consistent with age-related remodeling. 1-2 small hyperechoic nodules are observed. Vascular and biliary tracts are of normal volume with no evidence of congestion. The gall bladder lumen is moderately distended. The wall is thin and smooth. A small to moderate amount of gravity-dependent echogenic to mineralized debris is observed within the lumen. The cystic and common bile ducts are normal/not seen.



**PATIENT**

***Gastrointestinal***

Coffee Nastase

The stomach and intestine are free of stasis and exhibit normal peristaltic activity. The gastric lumen is not distended. The gastric wall and pylorus are normal in thickness with a normal layering pattern. The pyloric outflow tract is patent. The proximal duodenal lumen is mildly fluid distended. In a more distal segment of small intestine, a 1.04 cm shadowing structure is observed within the lumen. The small intestinal lumen, however, is not overtly dilated. The small intestinal wall thickness is normal with a normal layering pattern. There is evidence of mucosal speckling in some segments. Discreet masses are not identified. The colonic wall is normal.

**SPECIES**

Canine

**BREED**

Yorkshire Terrier

***Pancreas***

The right limb of the pancreas is visible with normal curvilinear peripheral contours. The parenchyma is largely isoechoic relative to surrounding omental fat and slightly mottled in appearance. The pancreatic duct is visible but not overtly dilated. There is no evidence of peripancreatic inflammation or effusion.

**SEX**

Male Neutered

***Free Abdomen***

The peritoneal cavity is normal. There is no evidence of inflammation or effusion. A 1.22 x 0.47 cm medial iliac lymph node is visualized.

**AGE**

8 Years 9 Months

**WEIGHT**

22.2 lbs.

**ULTRASONOGRAPHIC FINDINGS**

**Primary Findings:**

- Gallbladder debris, non-mucocele.
- The diffuse hepatic changes are non-specific and could be consistent with vacuolar hepatopathy, regenerative nodular hyperplasia, and/or age-related remodeling. Inflammatory and infiltrative disease are considered less likely.

**Secondary Findings:**

- The hyperechoic lesions adjacent to the splenic vessels are most consistent with myelolipomas. Although a neoplastic process within the spleen cannot be excluded, it is considered unlikely in this patient.
- Minor bilateral age-related renal changes.
- The shadowing structure within the small intestinal lumen likely represents non-obstructive foreign material and is likely transient.
- The small intestinal wall changes is suggestive of inflammatory disease. However, correlation with clinical findings is recommended.

**INTERPRETATION OF THE FINDINGS & FURTHER RECOMMENDATIONS**

- Consider repeating a total bilirubin using a vacutainer for blood collection, to avoid hemolysis during sampling. Hemolysis can cause false elevations in the total bilirubin.
- Serial monitoring (i.e., every 3-4 months) of the patient's liver values is recommended. If liver values continue to increase, repeat abdominal ultrasound +/- hepatic tissue sampling may be warranted.

**INTERPRETED BY**

Andrea Nicastro, DVM,  
Diplomate ACVIM  
(*Small Animal Internal  
Medicine*)

**IMAGING  
PERFORMED BY**

Potomac Mobile  
Veterinary Ultrasound

**HOSPITAL NAME**

Banfield Leesburg

**REFERRING VET**

Dr. Jarrett

**INVOICE**

12039

**DATE**

9/7/21



**PATIENT**

Coffee Nastase

**SPECIES**

Canine

**BREED**

Yorkshire Terrier

**SEX**

Male Neutered

**AGE**

8 Years 9 Months

**WEIGHT**

22.2 lbs.

**INTERPRETED BY**

Andrea Nicastro, DVM,  
Diplomate ACVIM  
(Small Animal Internal  
Medicine)

**IMAGING  
PERFORMED BY**

Potomac Mobile  
Veterinary Ultrasound

**HOSPITAL NAME**

Banfield Leesburg

**REFERRING VET**

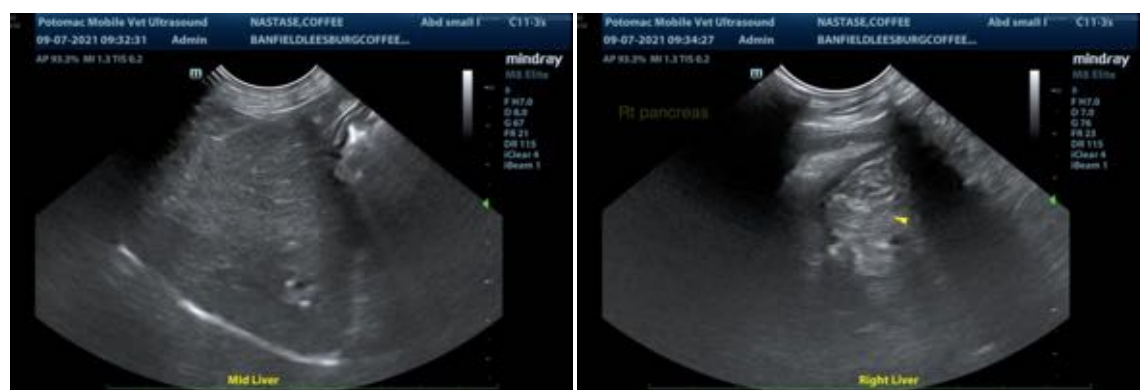
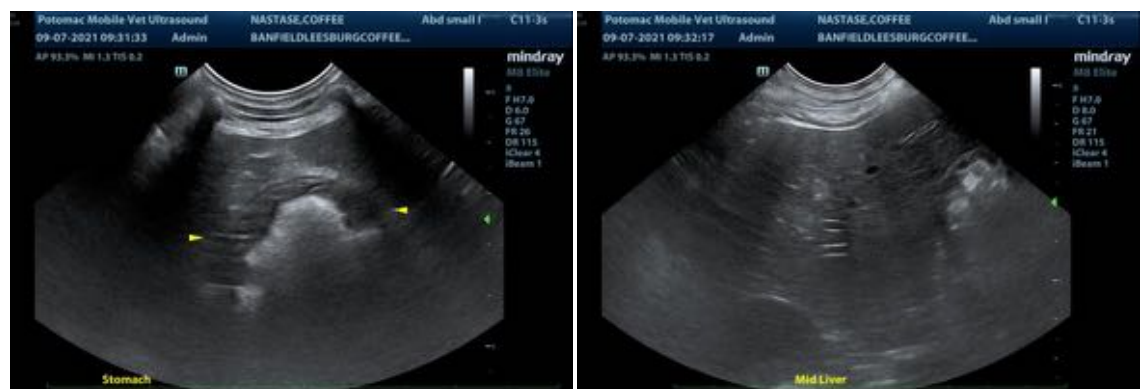
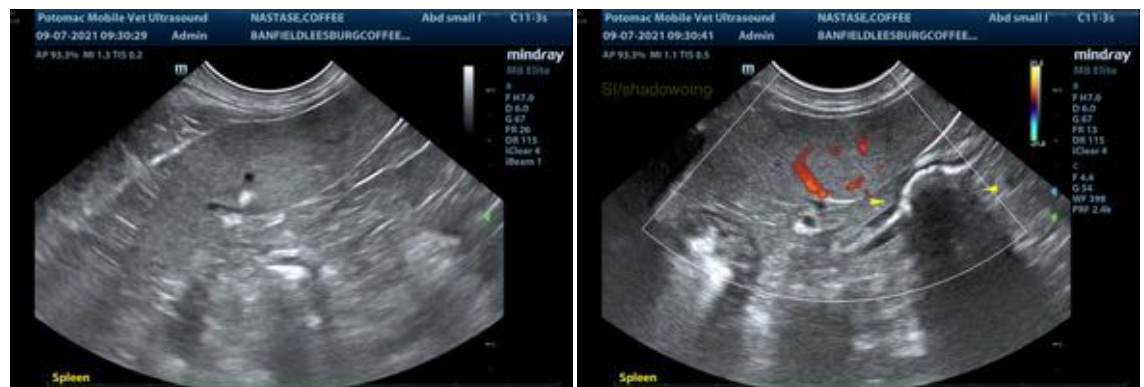
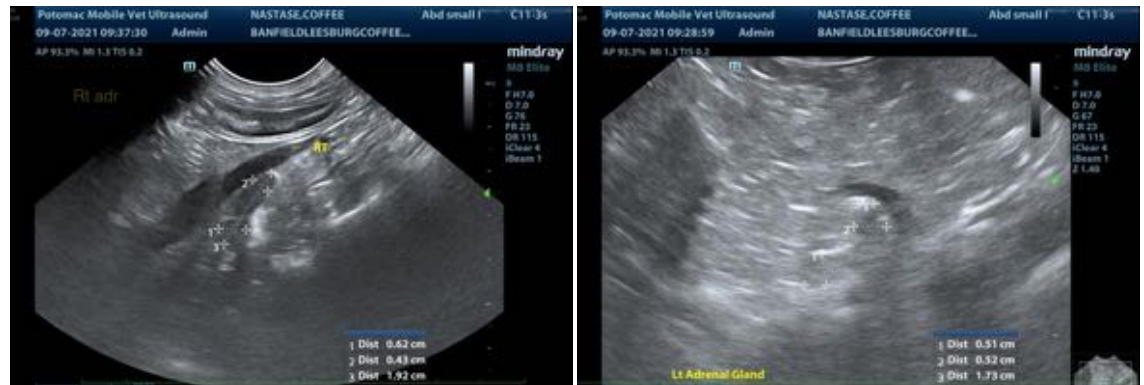
Dr. Jarrett

**INVOICE**

12039

**DATE**

9/7/21





**PATIENT**

Coffee Nastase

**SPECIES**

Canine

**BREED**

Yorkshire Terrier

**SEX**

Male Neutered

**AGE**

8 Years 9 Months

**WEIGHT**

22.2 lbs.

**INTERPRETED BY**

Andrea Nicastro, DVM,  
Diplomate ACVIM  
(*Small Animal Internal  
Medicine*)

**IMAGING  
PERFORMED BY**

Potomac Mobile  
Veterinary Ultrasound

**HOSPITAL NAME**

Banfield Leesburg

**REFERRING VET**

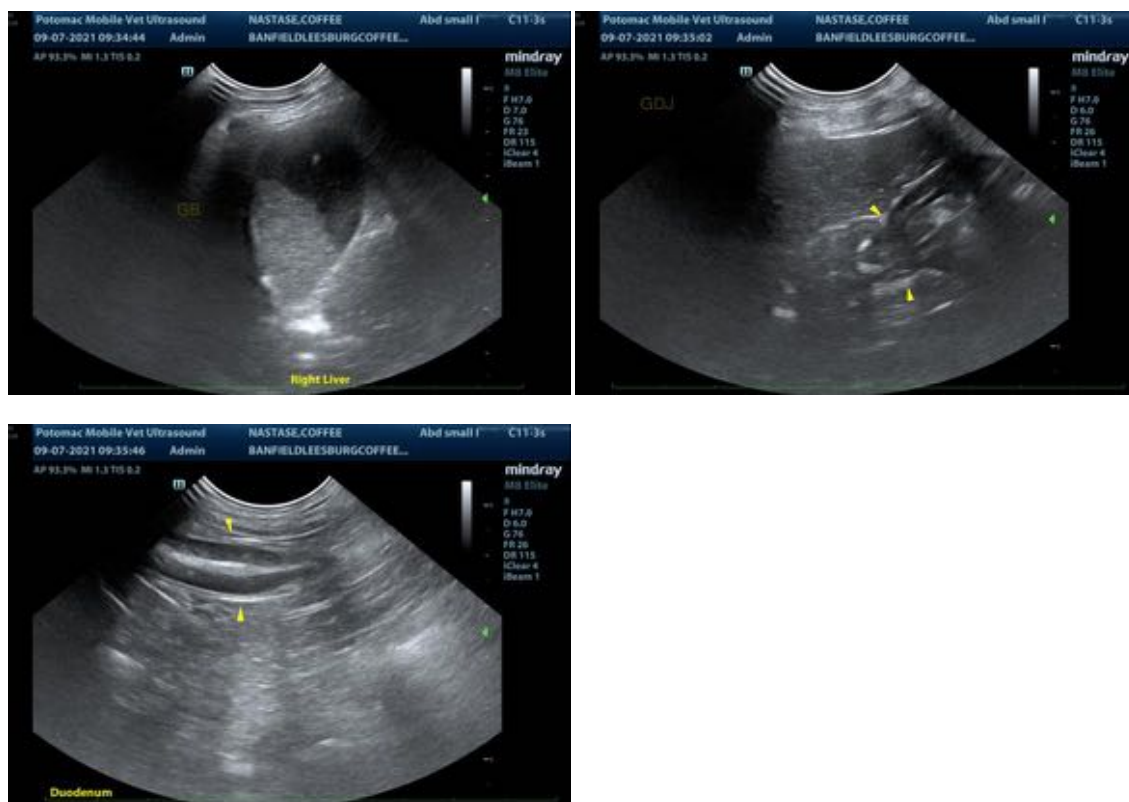
Dr. Jarrett

**INVOICE**

12039

**DATE**

9/7/21



The information and recommendations provided are based on the images presented by the referring veterinarian. No evaluation can be communicated regarding pathology that was not visible in the image/video clips provided.

Thank you for this referral. If the clinical or image interpretation does not parallel your findings or if I can be of any further assistance, please contact me.

Andrea Nicastro, DVM, Diplomate ACVIM (*Small Animal Internal Medicine*)  
Andrea.nicastro@sonopath.com