

**DATE PRESENTING CLINICAL SIGNS**

9/6/22

Recently was seen at ER while owner out of town and developed bloody diarrhea. Dx with colitis. At ER BW showed elevated LE, esp ALKP.

PATIENT

Linus O'Brien

Current Medications: Provable.
 Date of Previous IntraPet Ultrasound: No previous.
 Sedation: Not required to complete full diagnostic ultrasound.
 Stat Report: Not requested.
 Imaging Performed By: Rachel Brilhart, RDMS.

SPECIES

Canine

ULTRASONOGRAPHIC EXAMINATION OF THE ABDOMEN**BREED**

Miniature Schnauzer

Urinary System

The urinary bladder wall is normal in thickness and the mucosal surface is smooth. The bladder lumen is moderately distended with anechoic urine. No masses, inflammatory changes or calculi are observed. Ureteral papillae and visualized portion of the proximal urethra, visible to a depth of 1-2 cm, are normal.

SEX

Male, neutered

The prostate is normal in size (0.82 cm in width) and shape. Parenchyma is homogenous. The prostatic urethra appears normal without evidence of dilation or obstruction.

AGE

11/23/2009

The left kidney is normal size (5.83 cm in length); normal shape and architecture with smooth peripheral margins. There is a normal 1:3 cortex to medulla ratio with normal corticomedullary distinction. There is no evidence of pyelectasia, nephroliths, infarcts or hydroureter. Renal vasculature is normal.

WEIGHT

20.4 lbs.

The right kidney is normal size (5.21 cm in length); normal shape and architecture with smooth peripheral margins. There is a normal 1:3 cortex to medulla ratio with minimal loss of corticomedullary distinction. There is no evidence of pyelectasia, nephroliths, infarcts or hydroureter. Renal vasculature is normal.

INTERPRETED BY

Andrea Nicastro, DVM,
 Diplomate ACVIM
 (Small Animal Internal
 Medicine)

Adrenal Glands

The left adrenal gland is enlarged and irregular (0.93 cm at cranial pole) (1.02 cm at caudal pole) (2.85 cm in length) with a mass effect (2.13 x 1.46 cm) at the cranial to mid-aspect. The mass extends into the phrenic vein. There is loss of glandular detail. The glandular echogenicity and detail at the tip of the caudal pole are normal.

HOSPITAL NAME

Happier at Home
 Mobile Vet

The right adrenal gland is normal size (0.90 cm at cranial pole) (0.51 cm at caudal pole) (2.64 cm in length) with a slightly irregular shape. A 0.48 x 0.39 cm hyperechoic nodule is observed at the cranial pole. In addition, a pinpoint hyperechoic to mineralized focus is observed at the cranial aspect. Glandular echogenicity and detail in the remainder of the gland are normal. The phrenicoabdominal vein and surrounding vasculature are normal.

REFERRING VET

Dr. Haskin

Spleen

The spleen is normal in size (1.65 cm in width at the level of the hilus) with a normal capsular contour. The parenchyma is diffusely mottled in appearance. A 0.85 x 0.64 cm ill-defined hypoechoic area is observed in the region of the hilus along with 1-2 ill-defined myelolipomas. Splenic vasculature is normal.

INVOICE

13929

Liver

The liver is subjectively prominent in size with irregular peripheral margins on the right side. A 5.24 x 4.75 cm heterogeneous mass is arising from the caudate process. Surrounding mesentery is hyperechoic. The remaining hepatic parenchyma is mottled and heterogeneous in appearance with a few ill-defined hyperechoic nodules. Vascular and biliary tracts are of normal volume with no evidence of congestion. The portal vein: caudal vena cava ratio is approximately 1:1. The gall bladder lumen is moderately distended. The wall is thin and smooth. A small amount of aggregated echogenic gravity-dependent debris/sludge is observed within the lumen. The cystic and common bile ducts are normal/not seen.

Gastrointestinal

The stomach and intestine are free of stasis and exhibit normal peristaltic activity. The gastric lumen is not distended. The gastric wall and pylorus are normal in thickness with a normal layering pattern. The pyloric outflow tract is patent. The small intestinal lumen is not dilated. The small intestinal wall thickness is normal with a normal layering pattern and appropriate mural detail. Discreet masses are not identified. The colonic wall is normal. No obstructive disease is noted.

Pancreas

The region of the pancreas is isoechoic relative to surrounding omental fat. No obvious parenchymal abnormalities are observed. There is no evidence of regional inflammation or effusion.

Free Abdomen

There is no evidence of free fluid. The abdominal lymph nodes are normal/not visible.

Other

A brief echocardiogram reveals no evidence of pericardial effusion or obvious right atrial/auricular mass.

ULTRASONOGRAPHIC FINDINGS

Primary Findings:

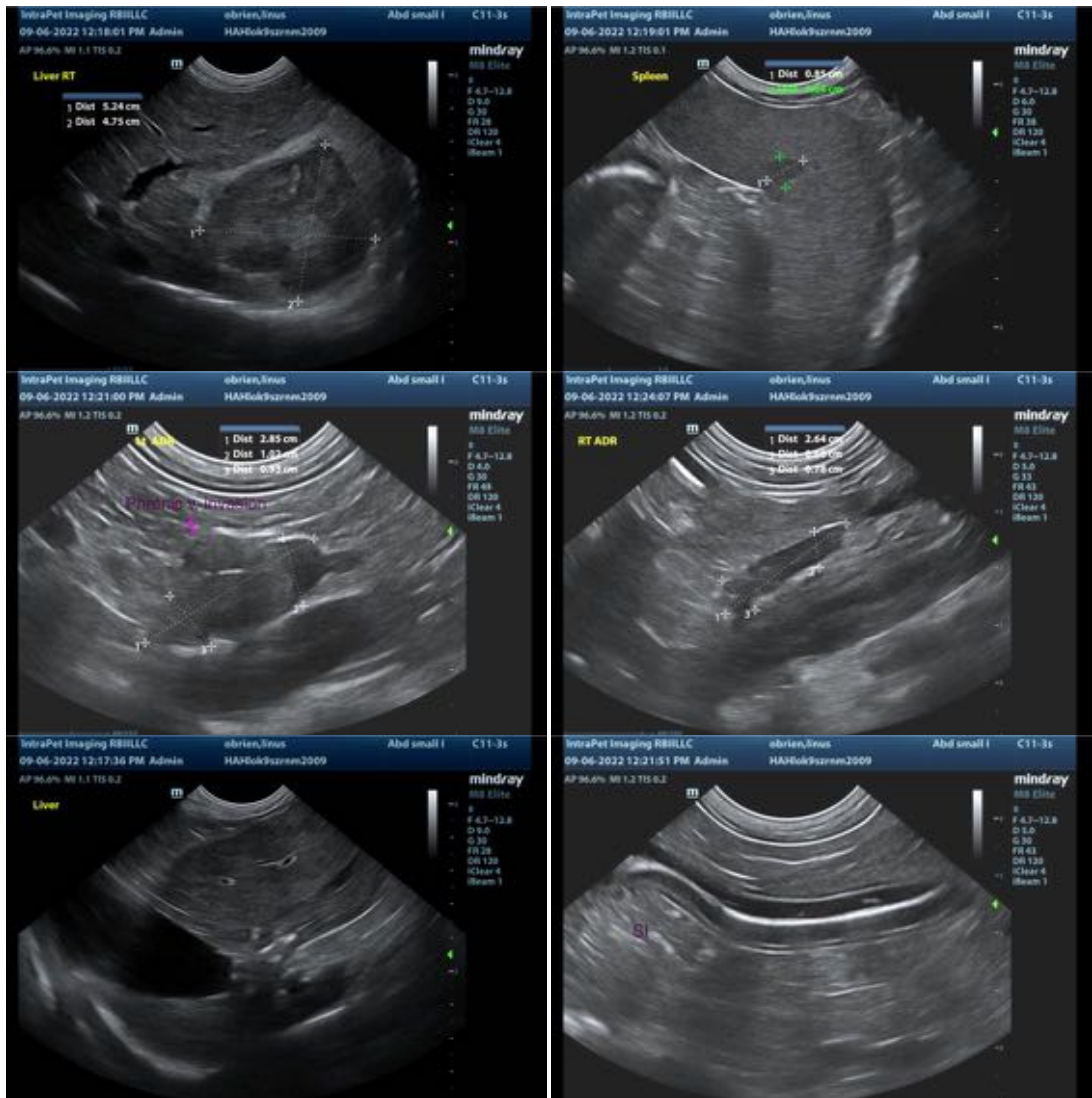
- Right hepatic mass. Neoplasia (i.e., adenoma, adenocarcinoma, round cell tumor) is considered likely with a lower possibility of a benign process. Regional peritonitis is present. The diffuse hepatic parenchymal changes could be consistent with infiltrative neoplasia, age-related remodeling, regenerative nodular hyperplasia, inflammatory disease, other hepatopathy.
- Left adrenal mass with invasion into the phrenic vein. Neoplasia (i.e., adenocarcinoma, pheochromocytoma) is suspected. The right adrenal nodule trends toward the benign (i.e., nodular hyperplasia) with a lower possibility of an emerging tumor.

Secondary Findings:

- The splenic parenchymal changes are most consistent with a benign process such as lymphoid hyperplasia, extramedullary hematopoiesis, splenitis or antigenic stimulation with a low possibility of infiltrative neoplasia (i.e., lymphoma, mast cell neoplasia).

INTERPRETATION OF THE FINDINGS & FURTHER RECOMMENDATIONS

- Three-view thoracic radiographs are recommended to assess for pulmonary metastases.
- Consider a fine needle aspirate of the right hepatic mass (if clotting status is appropriate).
- If an aggressive approach is desired, an abdominal exploratory with hepatic mass removal +/- left adrenalectomy can be considered. If pursued, referral to a board-certified surgeon is recommended due to the potential for perioperative complications. An abdominal CT scan would be useful in pre-surgical planning. However, prior to surgery, the client should be warned of the potential of multiple neoplasias or metastatic neoplasia.
- If surgery is not pursued, palliative/symptomatic care is recommended.



The information and recommendations provided are based on the images presented by the referring veterinarian. No evaluation can be communicated regarding pathology that was not visible in the image/video clips provided.

Thank you for this referral. If the clinical or image interpretation does not parallel your findings or if I can be of any further assistance please contact me.

Andrea Nicastro, MPH, DVM, Diplomate DACVIM (Small Animal Internal Medicine)
info@SonoPath.com