

**DATE PRESENTING CLINICAL SIGNS**

9/3/21 History: Weight loss / eats very little / indoor/outdoor cat Felv/FIV negative. Grade 1-2 heart murmur.

PATIENT Lab Results: Alt / Alp low.

Boogs Long Radiographs: space occupying mass dorsal/ cranial abdomen. Attached separately.

Date of Previous IntraPet Ultrasound: No previous IntraPet scans.

SPECIES

Feline

Sedation: not needed

Stat Report: not requested

BREED

Domestic Shorthair

ULTRASONOGRAPHIC EXAMINATION OF THE ABDOMEN**Urinary System**

The urinary bladder, trigone, and pelvic urethra are normal in thickness and the mucosal surface is smooth. The bladder lumen is mildly distended with anechoic urine. No masses, inflammatory changes or calculi are observed. Ureteral papillae and visualized portion of the proximal urethra, visible to a depth of 2 cm, are normal.

SEX

Male Neutered

AGE

2010

The left kidney, when including the renal capsule, is enlarged (6.62 cm in length). The left kidney itself is mildly enlarged (5.23 cm in length) with an irregular shape. The cortex is thinner than normal and there is slight loss of corticomedullary distinction. Severe pyelectasia/hydronephrosis is present (1.87 cm in the longitudinal plane). A large amount of subcapsular fluid is present and appears somewhat septated/cystic near the caudomedial aspect. There is no evidence of nephroliths or hydroureter. Renal vasculature is normal. Surrounding mesentery is hyperechoic.

WEIGHT

7 lbs. 5 oz.

The right kidney is normal size (4.34 cm in length); normal shape and architecture with smooth peripheral margins. There is a normal 1:3 cortex to medulla ratio with minimal to mild loss of corticomedullary distinction. There is no evidence of pyelectasia, nephroliths, infarcts or hydroureter. Renal vasculature is normal.

INTERPRETED BY

Andrea Nicastro, DVM,
Diplomate ACVIM
(Small Animal Internal
Medicine)

Adrenal Glands

The region of the adrenal glands is evaluated. No obvious pathology is observed.

HOSPITAL NAME

Chadwell

Spleen

The spleen is normal in size (0.96 cm in width at the level of the hilus) with a normal capsular contour. There is appropriate echogenicity and echotexture. No focal lesions are observed. Splenic vasculature is normal.

REFERRING VET

Dr. Malick

Liver

The liver is subjectively normal in size with normal contours and structure. There is appropriate echogenicity and echotexture. No overt structural evidence of inflammatory, infiltrative, or regenerative pathology is evident. Vascular and biliary tracts are of normal volume with no evidence of congestion. No pathological hepatic lymphadenopathy observed. The gall bladder is moderately distended. The wall is normal in thickness. A moderate amount of aggregated, echogenic, debris/sludge is observed within the lumen. The cystic and common bile ducts are visible/tortuous but not overtly dilated.

INVOICE

11769kk

Gastrointestinal

The stomach and intestine are free of stasis and exhibit normal peristaltic activity. The gastric lumen is not distended. The gastric wall and pylorus are normal in thickness with a normal layering pattern. The pyloric outflow tract is patent. The small intestinal lumen is not dilated. The small intestinal wall is normal in thickness with a normal layering pattern and appropriate mural detail. There is disruption in the normal 1:3 muscularis to mucosal ratio with a 1:1 ratio in some segments. Discreet masses are not identified. There is a prominent muscularis layer in the distal ileum at the level of the ileocolic junction. The colonic wall is normal. There is no evidence of an obstructive pattern.

Pancreas

The right limb of the pancreas is prominent in size with minimal deviation from the normal peripheral contours. The parenchyma is hypoechoic relative to surrounding omental fat and slightly heterogeneous in appearance. No distinct focal lesions are observed. The pancreatic duct is visible but not overtly dilated (0.20 cm in diameter). The mesentery effacing the serosal surface is mildly hyperechoic.

Free Abdomen

There is no evidence of free fluid. One to two prominent lymph nodes are observed at the ileocolic junction, the largest measuring 0.58 cm in diameter.

Other

A brief echocardiogram reveals no evidence of pericardial effusion.

ULTRASONOGRAPHIC FINDINGS

Primary Findings:

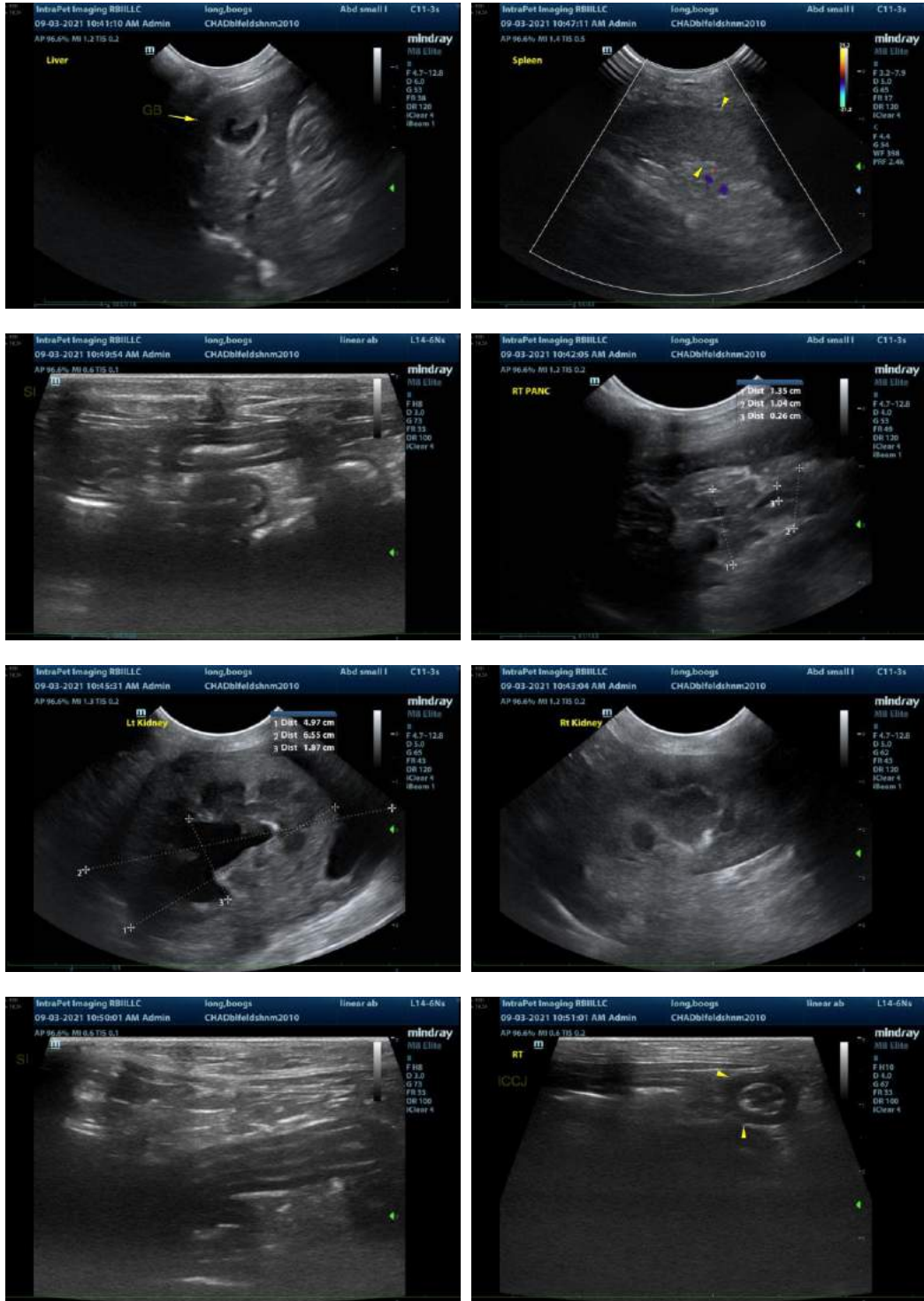
- The left renal changes could be consistent with a severe inflammatory process/pyelonephritis; however, infiltrative neoplasia cannot be completely excluded. Age-related renal pathology is observed in both kidneys. Retroperitonitis is present, secondary to renal pathology.
- Bowel pattern consistent with inflammatory bowel disease or emerging lymphoma.

Secondary Findings:

- The prominent abdominal lymph nodes are most consistent with reactive lymphadenitis or lymphoid hyperplasia. Neoplastic infiltration is considered less likely.
- The pancreatic changes are most consistent with age-related remodeling/fibrosis +/- concurrent low-grade inflammation.

INTERPRETATION OF THE FINDINGS & FURTHER RECOMMENDATIONS

1. VD and left lateral thoracic radiographs are recommended to complete the metastatic check.
2. With regard to the left renal changes, consider the following diagnostics:
 - a. Urine culture and sensitivity.
 - b. Ultrasound-guided, fine needle aspirate of the left subcapsular fluid with submission for fluid analysis and cytology.
3. Other diagnostic considerations include:
 - a. A malabsorption panel including serum cobalamin, folate, PLI and TLI.
 - b. A fecal evaluation for ova/Giardia
4. Ultimately, if the above diagnostics are inconclusive, an abdominal exploratory with left renal and gastrointestinal biopsies may be necessary to get a definitive diagnosis. If surgery is pursued, an echocardiogram, ECG, and baseline blood pressure measurements are recommended (given the presence of a heart murmur).



The information and recommendations provided are based on the images presented by the referring veterinarian. No evaluation can be communicated regarding pathology that was not visible in the image/video clips provided.

Thank you for this referral. If the clinical or image interpretation does not parallel your findings or if I can be of any further assistance, please contact me.

Andrea Nicastro, DVM, Diplomate ACVIM (*Small Animal Internal Medicine*)
Andrea.nicastro@sonopath.com