



PATIENT

Pepper Demy

SPECIES

Canine

BREED

Mini Schnauzer

SEX

Neutered Male

AGE

8 years

WEIGHT

24 lbs

INTERPRETED BY

Andrea Nicastro,
DVM, Diplomate
ACVIM (*Small Animal
Internal Medicine*)

IMAGING PERFORMED BY

Meghan Myers VMD

HOSPITAL NAME

Hershire AH

REFERRING VET

Meghan Myers VMD

INVOICE

11749

DATE

9.29.22

PRESENTING CLINICAL SIGNS

History: Routine wellness screening showed elevated liver enzymes No clinical signs noted at home other than atopy which is controlled with apoquel. PE - moderate tartar, mild hepatomegaly Ultrasound recommended as next diagnostic step for evaluation of increased liver values

Abnormal PE/Chem/CBC/UA Results: CBC/chem/lytes/t4: 9/2022- ALKP 1448; remainder of chemistry and CBC wnl; Bloodwork done at previous DVM July 2021 ALKP 874 LDDS 9/2022 not consistent with Cushing's

ULTRASONOGRAPHIC EXAMINATION OF THE ABDOMEN

Urinary System

The **urinary bladder** and visible portion of the pelvic urethra are normal for the degree of luminal distension. The urine is anechoic with no evidence of debris. Cystic calculi and discrete masses are not observed. The region of the trigone and the visible portion of the proximal urethra are normal.

The **prostate** is normal in size (1.05 cm in width) and shape. Parenchyma is homogenous. The prostatic urethra appears normal without evidence of dilation or obstruction.

The **left kidney** is normal in size (4.62 cm in length) with a normal shape, smooth peripheral margins, and normal internal architecture. There is mild loss of corticomedullary distinction. Several hyperechoic shadowing diverticular foci are observed. A few pinpoint hyperechoic foci are observed within the cortex. There is no evidence of pyelectasia, infarcts or hydronephrosis. Renal vasculature is normal.

The **right kidney** is normal in size (3.92 cm in length) with a normal shape, smooth peripheral margins, and normal internal architecture. There is mild loss of corticomedullary distinction. Several hyperechoic shadowing diverticular foci are observed. There is no evidence of pyelectasia, infarcts or hydronephrosis. Renal vasculature is normal.

Adrenal Glands

The caudal pole of the left **adrenal gland** is well-visualized and is normal in size (0.54 cm in width); with a normal shape, glandular echogenicity and detail. Surrounding vasculature appears normal.

The **right adrenal gland** is normal size (0.59 cm at cranial pole) (0.43 cm at caudal pole); normal shape; homogenous parenchyma. The glandular echogenicity and detail are unremarkable. Capsule, cortex, and medullary definition are normal. The phrenicoabdominal vein and surrounding vasculature are normal.

Spleen

The **spleen** is normal in size (1.33 cm in width at the level of the hilus) with a normal capsular contour. There is appropriate echogenicity and echotexture. No focal lesions are observed. Splenic vasculature is normal.

Liver

The **liver** is subjectively enlarged with slightly swollen peripheral contours. The parenchyma is isoechoic relative to the spleen and diffusely homogeneous in appearance. No distinct focal lesions are observed. Vascular and biliary tracts are of normal volume with no evidence of congestion.

The **gall bladder** lumen is moderately distended. The wall is thin and smooth. A small amount of suspended, echogenic debris is observed within the lumen. The cystic and common bile ducts are normal/not seen.

Gastrointestinal

The **stomach and intestine** are free of stasis and exhibit normal peristaltic activity. The gastric lumen is not distended. The gastric wall and pylorus are normal in thickness with a normal layering pattern. The pyloric outflow tract is patent. The small intestinal lumen is not dilated. The small intestinal wall thickness is normal with a normal layering pattern and appropriate mural detail. Discreet masses are not identified. The colonic wall is normal. There is no evidence of an obstructive pattern.

Pancreas

The base and limbs of the **pancreas** are normal in size with normal curvilinear peripheral contours. The parenchyma is largely isoechoic relative to surrounding omental fat and slightly mottled in appearance. The pancreatic duct is visible but not overtly dilated. There is no evidence of peripancreatic inflammation or effusion.

Free Abdomen

The **peritoneal cavity** is normal. There is no evidence of inflammation or effusion. The abdominal **lymph nodes** are normal/not visible.

ULTRASONOGRAPHIC FINDINGS

Primary Findings

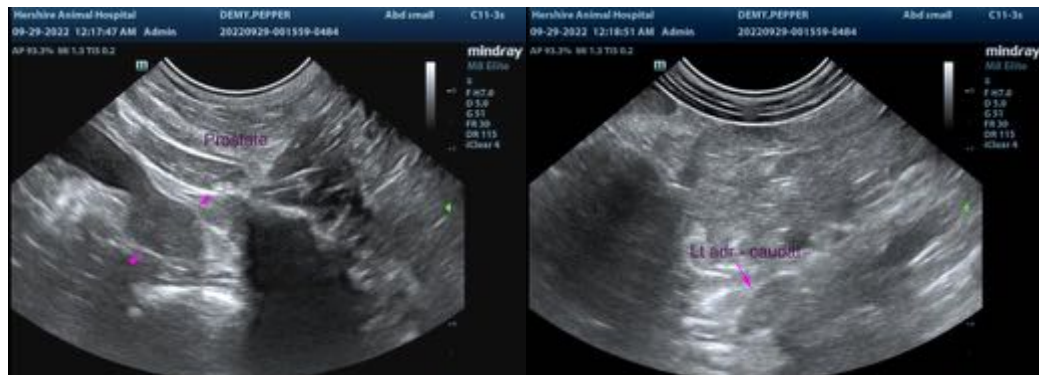
- The diffuse hepatic changes are non-specific and could be consistent with vacuolar hepatopathy, regenerative nodular hyperplasia, and/or age-related remodeling. Inflammatory and infiltrative disease are considered less likely.

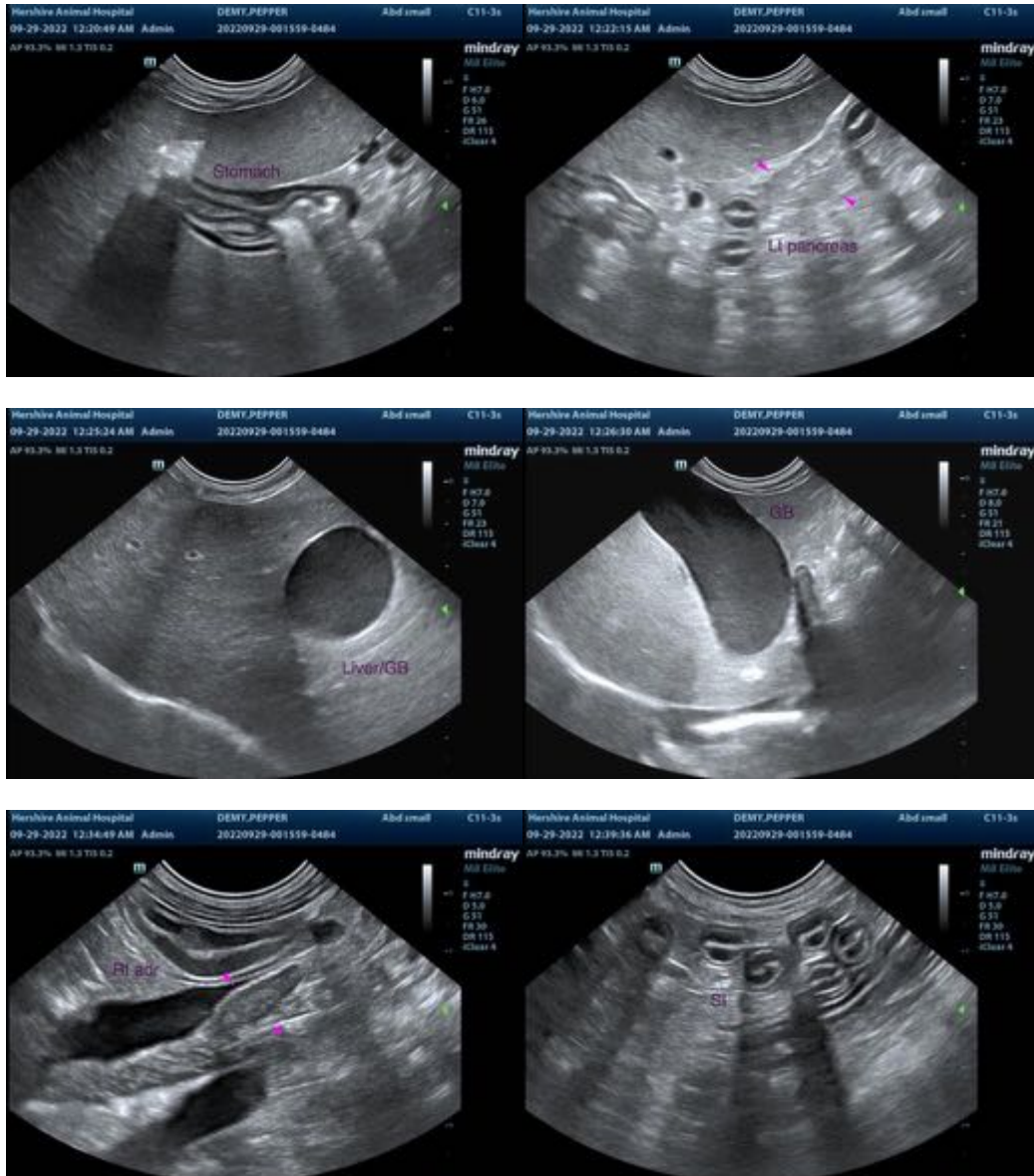
Secondary Findings

- Minor age-related pancreatic and renal changes

INTERPRETATION OF THE FINDINGS & FURTHER RECOMMENDATIONS

Serial monitoring (i.e., every 3-4 months) of the patient's liver values is recommended. If values continue to increase, a repeat abdomen ultrasound +/- a more advanced hepatic work-up (i.e., tissue sampling) may be warranted.





The information and recommendations provided are based on the images presented by the referring veterinarian/sonographer. No evaluation can be communicated regarding pathology that was not visible in the image/video clips provided.

Thank you for this referral. If the clinical or image interpretation does not parallel your findings or if I can be of any further assistance, please contact me.

Andrea Nicastro, MPH, DVM, Diplomate DACVIM (Small Animal Internal Medicine)
info@SonoPath.com