



PATIENT PRESENTING CLINICAL SIGNS

Pumpkin Stekler History: Weight loss, intermittent vomiting. History of IBD. Current meds: Metronidazole 50 mgs SID, Prednisolone 5 mgs SID.

SPECIES Abnormal PE/Chem/CBC/UA Results: CBC/CHEM: WNL.

Feline

ULTRASONOGRAPHIC EXAMINATION OF THE ABDOMEN

BREED *Urinary System*

DSH The **urinary bladder** wall is normal in thickness and the mucosal surface is smooth. The bladder is moderately distended. A scant amount of echogenic debris is observed within the lumen. No masses, inflammatory changes or calculi are observed. The region of the trigone and the visible portion of the proximal urethra are normal.

SEX

Neutered Male The **left kidney** is normal size (4.33 cm in length); normal shape and architecture with smooth peripheral margins. There is a normal 1:3 cortex to medulla ratio with minimal to mild loss of corticomedullary distinction. There is no evidence of pyelectasia, nephroliths, infarcts or hydroureter. Renal vasculature is normal.

AGE

16 years The **right kidney** is normal size (3.77 cm in length); normal shape and architecture with smooth peripheral margins. There is a normal 1:3 cortex to medulla ratio with normal corticomedullary distinction. There is no evidence of pyelectasia, nephroliths, infarcts or hydroureter. Renal vasculature is normal.

WEIGHT

10 lbs The region of the **left adrenal gland** is evaluated. No obvious pathology is observed.

The **right adrenal gland** is enlarged (0.30 cm cranial; 0.87 cm caudal; 1.23 cm in length) with an irregular shape. The parenchyma is homogenous. There is no obvious evidence of vascular invasion. The phrenicoabdominal vein and surrounding vasculature are normal.

INTERPRETED BY

Andrea Nicastro,
DVM, Diplomate
ACVIM (*Small Animal
Internal Medicine*)

Spleen

The **spleen** is normal in size (0.77 cm in width at the level of the hilus) with a normal capsular contour. There is appropriate echogenicity and echotexture. No focal lesions are observed. Splenic vasculature is normal.

IMAGING PERFORMED BY

Kelly Vazquez

Liver

The **liver** is subjectively normal in size with normal curvilinear peripheral contours. The parenchyma is hyperechoic relative to the spleen. In the right lateral lobe, a 1.73 cm irregular, multi-septated cystic lesion is visualized. The remaining parenchyma is homogenous. Hepatic vasculature and intrahepatic biliary tracts are of normal volume with no evidence of congestion.

HOSPITAL NAME

Glen Rock VH

The **gall bladder** lumen is moderately distended. The wall is thin and smooth. Luminal contents are anechoic. The cystic and common bile ducts are normal/not seen.

REFERRING VET

Dr. Scott Stekler

Gastrointestinal

The **gastric lumen** is mildly to moderately distended with ingesta. The gastric wall and pylorus are normal in thickness with a normal layering pattern. The pyloric outflow tract appears patent. The small intestinal lumen is segmentally dilated with chyme. The small intestinal wall is normal in thickness with retention of the normal layering pattern. There is slight disruption in the normal 1:3 muscularis: mucosal ratio in some segments. Discreet masses are not identified. The muscularis layer at the ileocecal colic junction is prominent. The colonic wall is normal. There is no evidence of an obstructive pattern.

INVOICE

11736

DATE

9.28.22

Pancreas

The region of the **pancreas** is isoechoic relative to surrounding omental fat. No obvious parenchymal abnormalities are observed. There is no evidence of regional inflammation or effusion.

Free Abdomen

There is no evidence of free fluid. A few prominent, hypoechoic, mesenteric **lymph nodes** are visualized, the largest measuring 1.17 cm in length. Surrounding mesentery is hyperechoic.

ULTRASONOGRAPHIC FINDINGS

Primary Findings

- Bowel pattern suggestive of inflammatory bowel disease. There is some potential for emerging lymphoma. However, neoplasia is considered less likely at this time.
- The prominent abdominal lymph nodes are most consistent with reactive lymphadenitis or lymphoid hyperplasia. Neoplastic infiltration is considered less likely.
- The right adrenal changes could be consistent with adenoma, adenocarcinoma, hyperplasia, other.

Secondary Findings

- The right, cystic, hepatic lesion is most consistent with a benign cyst or biliary cystadenoma with a lower possibility of cystadenocarcinoma.
- Minor age-related renal changes

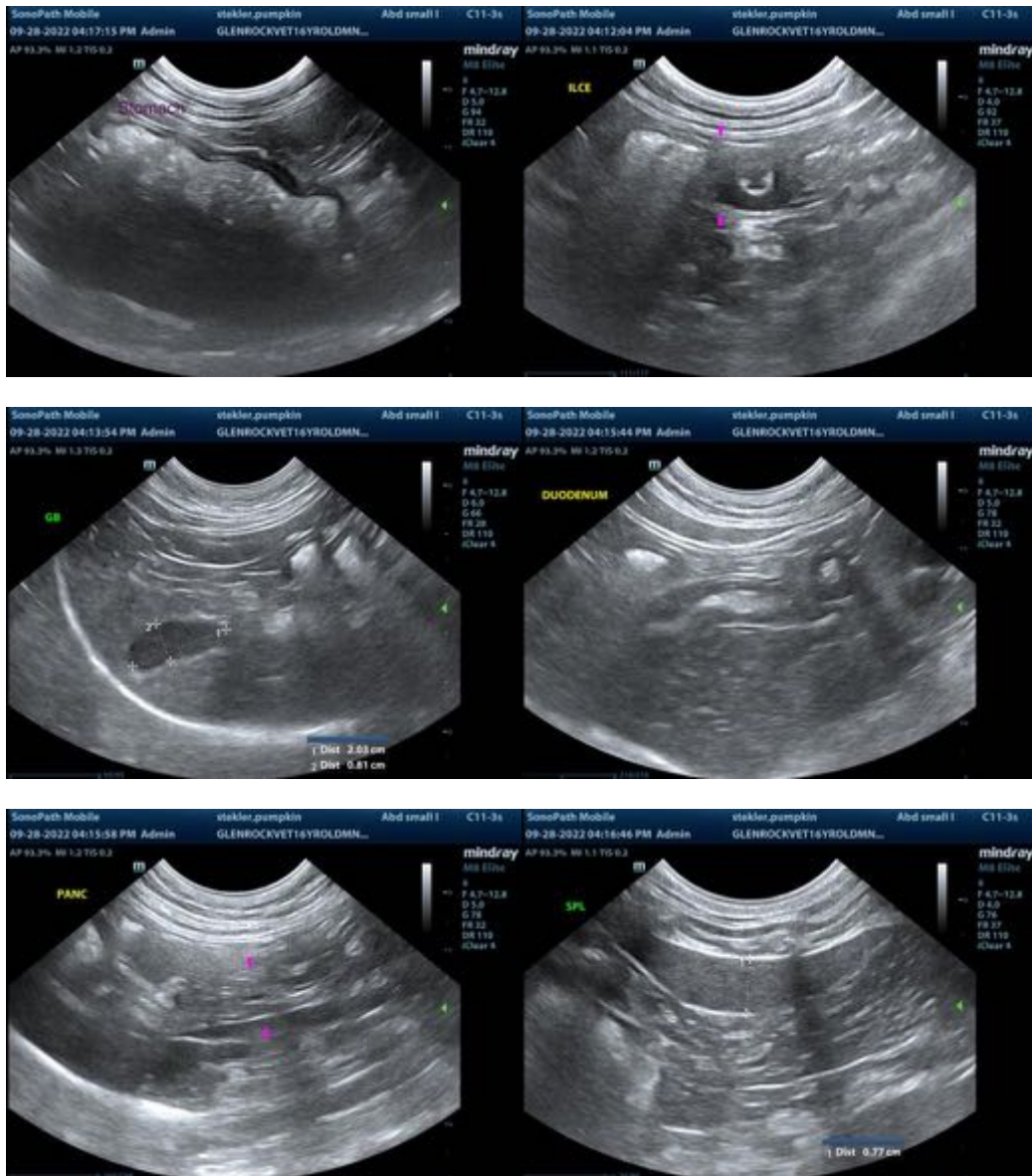
INTERPRETATION OF THE FINDINGS & FURTHER RECOMMENDATIONS

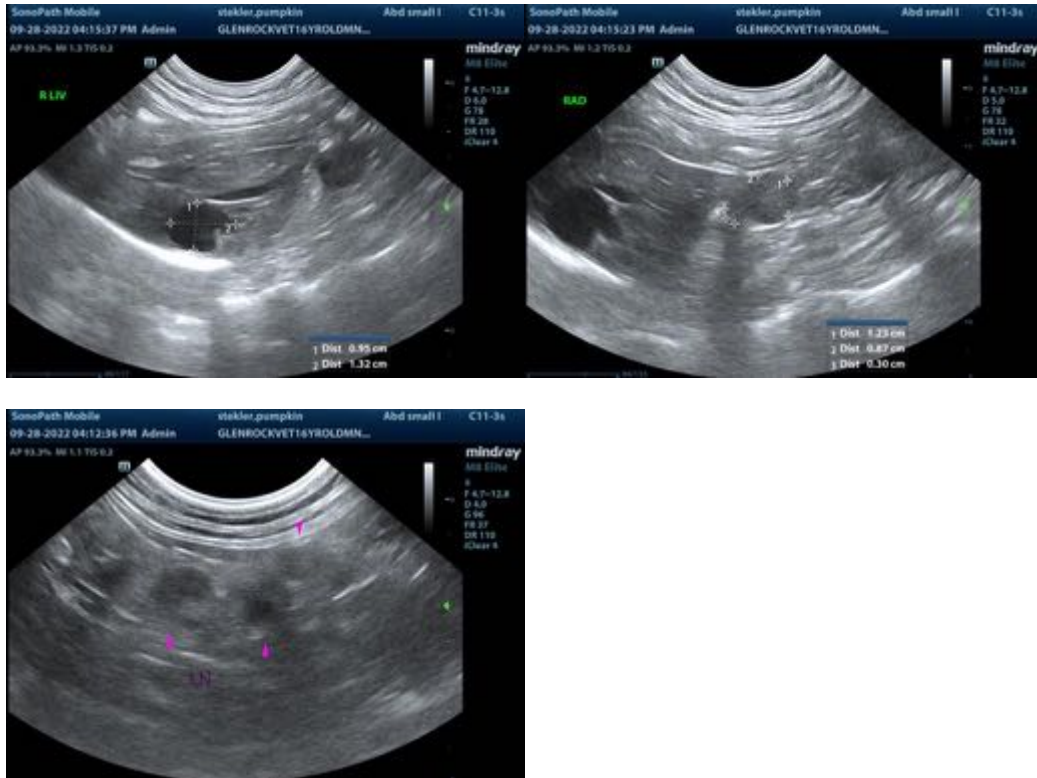
The following diagnostic/treatment recommendations can be considered:

1. Serum cobalamin, folate, PLI and TLI
2. Fecal evaluation for ova/Giardia
3. 6-week limited antigen or hydrolyzed protein diet trial to assess for food allergies
4. If the above diagnostics/therapeutics are inconclusive, endoscopic or surgical gastrointestinal biopsies may be warranted.
5. For patients where chronic vomiting is present but additional diagnostics are not to be performed, consider triple therapy as empirical treatment for Helicobacter gastritis:
 - a. Amoxicillin: 10-22 mg/kg PO q 12 hours x 14-21 days
 - b. Metronidazole: 10-15 mg/kg PO q 12 hours for 14-21 days
 - c. Omeprazole: 0.7 mg/kg PO q 24 hours for 14-21 days
 - d. (+/- the addition of Bismuth subsalicylate: 3.85 mg/kg PO q 6-8 hours x 14-21 days)

- Also consider heartworm antigen and antibody testing as heartworm disease can be a cause of chronic vomiting in cats.

Regarding the right adrenal changes, consider a baseline blood pressure measurement to assess for systemic hypertension, which can occur with hyperaldosteronism. Close monitoring of the patient's sodium and potassium is also recommended.





The information and recommendations provided are based on the images presented by the referring veterinarian/sonographer. No evaluation can be communicated regarding pathology that was not visible in the image/video clips provided.

Thank you for this referral. If the clinical or image interpretation does not parallel your findings or if I can be of any further assistance, please contact me.

Andrea Nicastro, MPH, DVM, Diplomate DACVIM (Small Animal Internal Medicine)
info@SonoPath.com