



PATIENT PRESENTING CLINICAL SIGNS

Ollie Pandit History: History of grade 2 mast cell tumor - low grade, fully resected with good margins. Thoracic radiographs WNL. Current meds: Carprofen, diphenhydramine, famotidine, and gabapentin. Abnormal PE/Chem/CBC/UA Results: CBC/Chem: WNL. Platelet count 332,00, HCT 54%.

SPECIES

Canine

BREED

Mini Goldendoodle

SEX

Neutered Male

AGE

2.5 years

WEIGHT

25.5 lbs

INTERPRETED BY

Andrea Nicastro,
DVM, Diplomate
ACVIM (*Small Animal
Internal Medicine*)

IMAGING PERFORMED BY

Kelly Vazquez

HOSPITAL NAME

Companion VH
Wayne

REFERRING VET

Dr. Ben Spitz

INVOICE

11733

DATE

9.28.22

ULTRASONOGRAPHIC EXAMINATION OF THE ABDOMEN

Urinary System

The **urinary bladder** wall is normal in thickness and the mucosal surface is smooth. The bladder lumen is mildly distended with anechoic urine. No masses, inflammatory changes or calculi are observed. Ureteral papillae and visualized portion of the proximal urethra, visible to a depth of 2 cm, are normal.

The **prostate** is normal in size (0.74 cm in width) and shape. Parenchyma is homogenous. The prostatic urethra appears normal without evidence of dilation or obstruction.

The **left kidney** is normal size (4.33 cm in length); normal shape and architecture with smooth peripheral margins. There is a normal 1:3 cortex to medulla ratio with normal corticomedullary distinction. There is no evidence of pyelectasia, nephroliths, infarcts or hydronephrosis. Renal vasculature is normal.

The **right kidney** is normal size (4.43 cm in length); normal shape and architecture with smooth peripheral margins. There is a normal 1:3 cortex to medulla ratio with normal corticomedullary distinction. There is no evidence of pyelectasia, nephroliths, infarcts or hydronephrosis. Renal vasculature is normal.

Adrenal Glands

The **left adrenal gland** is normal size (0.47 cm at cranial pole) (0.44 cm at caudal pole) (0.86 cm in length); normal shape; homogenous parenchyma. The glandular echogenicity and detail are unremarkable. Capsule, cortex, and medullary definition are normal. The phrenicoabdominal vein and surrounding vasculature are normal.

The **right adrenal gland** is normal size (0.84 cm at cranial pole) (0.41 cm at caudal pole) (2.05 cm in length); normal shape; homogenous parenchyma. The glandular echogenicity and detail are unremarkable. Capsule, cortex, and medullary definition are normal. The phrenicoabdominal vein and surrounding vasculature are normal.

Spleen

The **spleen** is normal in size (1.50 cm in width at the level of the hilus) with a normal capsular contour. The parenchyma is very subtly mottled in appearance. No focal lesions are observed. Splenic vasculature is normal.

Liver

The **liver** is subjectively normal in size with normal contours and structure. There is appropriate echogenicity and echotexture. No overt structural evidence of inflammatory, infiltrative, or regenerative pathology is evident. Vascular and biliary tracts are of normal volume with no evidence of congestion. No pathological hepatic lymphadenopathy observed.

The **gall bladder** lumen is moderately distended. The wall is thin and smooth. Luminal contents are anechoic. The cystic and common bile ducts are normal/not seen.

Gastrointestinal

The **stomach and intestine** are free of stasis and exhibit normal peristaltic activity. The gastric lumen is minimally distended with ingesta. The gastric wall and pylorus are normal in thickness with a normal layering pattern. The pyloric outflow tract is patent. The small intestinal lumen is not dilated. The small

intestinal wall thickness is normal with a normal layering pattern and appropriate mural detail. Discreet masses are not identified. The colonic wall is normal. There is no evidence of an obstructive pattern.

Pancreas

The region of the **pancreas** is isoechoic relative to surrounding omental fat. No obvious parenchymal abnormalities are observed. There is no evidence of regional inflammation or effusion.

Free Abdomen

The **peritoneal cavity** is normal. There is no evidence of inflammation or effusion. The abdominal **lymph nodes** are normal/not visible.

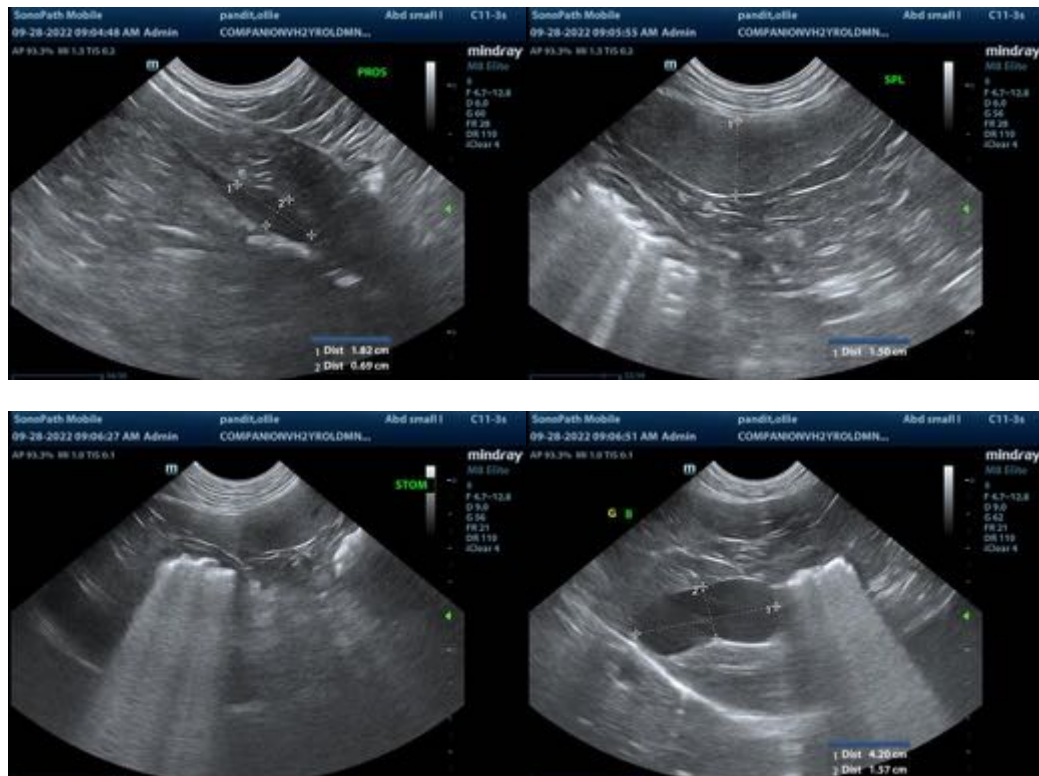
ULTRASONOGRAPHIC FINDINGS

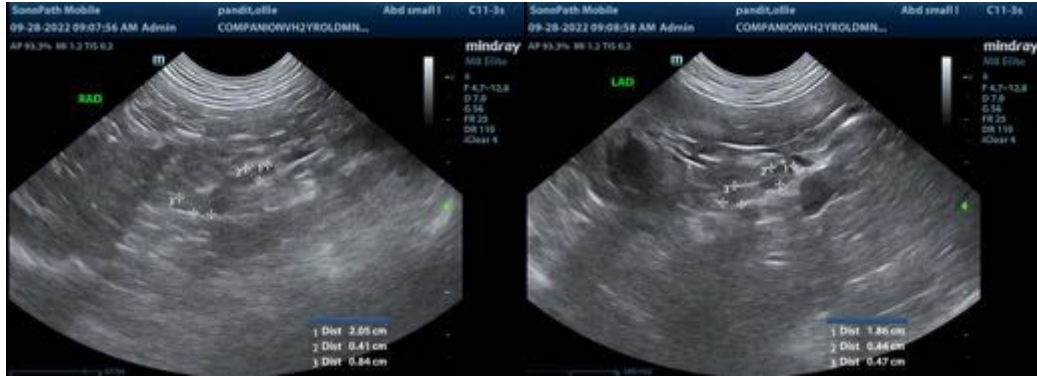Primary Findings

- The splenic parenchymal changes may be a normal variant for this patient. Alternatively, they may represent lymphoid hyperplasia, extramedullary hematopoiesis, splenitis, antigenic stimulation, or less likely, infiltrative neoplasia.

INTERPRETATION OF THE FINDINGS & FURTHER RECOMMENDATIONS

A fine-needle aspirate of the spleen can be considered (for peace of mind) to assess for mast cell disease. If pursued, the patient should be pretreated with diphenhydramine at 2.2 mg/kg subcutaneously prior to aspiration to reduce the risk of mast cell degranulation. A 25-gauge needle should be used for aspiration.





The information and recommendations provided are based on the images presented by the referring veterinarian/sonographer. No evaluation can be communicated regarding pathology that was not visible in the image/video clips provided.

Thank you for this referral. If the clinical or image interpretation does not parallel your findings or if I can be of any further assistance, please contact me.

Andrea Nicastro, MPH, DVM, Diplomate DACVIM (Small Animal Internal Medicine)
info@SonoPath.com