



PATIENT

Daphne Scala

PRESENTING CLINICAL SIGNS

History: Patient presents for decreased detail in the cranial abdomen on radiographs, patient is lethargic. On Clindamycin for dental.

SPECIES

Canine

Abnormal PE/Chem/CBC/UA Results: Low PLTs 93,000.

ULTRASONOGRAPHIC EXAMINATION OF THE ABDOMEN

BREED

Mixed

Urinary System

The **urinary bladder** wall is normal in thickness and the mucosal surface in the region of the apex is slightly irregular. The bladder lumen is moderately distended with anechoic urine. No masses, inflammatory changes or calculi are observed. Ureteral papillae and visualized portion of the proximal urethra, visible to a depth of 2 cm, are normal.

SEX

Spayed Female

The **left kidney** is normal in size (5.00 cm in length); normal shape and architecture with smooth peripheral margins. There is a normal 1:3 cortex to medulla ratio with minimal loss of corticomedullary distinction. There is no evidence of pyelectasia, nephroliths, infarcts or hydronephrosis. Renal vasculature is normal.

AGE

14 years

The **right kidney** is normal size (4.80 cm in length); normal shape and architecture with smooth peripheral margins. There is a normal 1:3 cortex to medulla ratio with minimal loss of corticomedullary distinction. There is no evidence of pyelectasia, nephroliths, infarcts or hydronephrosis. Renal vasculature is normal.

WEIGHT

N/A

Adrenal Glands

The **left adrenal gland** is normal size (0.82 cm at cranial pole) (0.68 cm at caudal pole) (1.85 cm in length); normal shape; homogenous parenchyma. The glandular echogenicity and detail are unremarkable. Capsule, cortex, and medullary definition are normal. The phrenicoabdominal vein and surrounding vasculature are normal.

INTERPRETED BY

Andrea Nicastro,
DVM, Diplomate
ACVIM (*Small Animal
Internal Medicine*)

The **right adrenal gland** is normal size (0.96 cm at cranial pole) (0.54 cm at caudal pole) (1.98 cm in length); normal shape; homogenous parenchyma. The glandular echogenicity and detail are unremarkable. Capsule, cortex, and medullary definition are normal. The phrenicoabdominal vein and surrounding vasculature are normal.

IMAGING PERFORMED BY

Kelly Vazquez

Spleen

The **spleen** is normal in size (1.65 cm in width at the level of the hilus) with a normal capsular contour. A light micronodular pattern is observed throughout the parenchyma. A small hypoechoic nodule is observed approximately mid-spleen. Splenic vasculature is normal.

HOSPITAL NAME

Animal General on
Hudson

Liver

The **liver** is subjectively normal in size with normal contours and structure. There is appropriate echogenicity and echotexture. No overt structural evidence of inflammatory, infiltrative, or regenerative pathology is evident. Vascular and biliary tracts are of normal volume with no evidence of congestion. No pathological hepatic lymphadenopathy observed. The portal vein to caudal vena cava ratio is approximately 1: 1.

REFERRING VET

Dr. Karen Zelinski

The **gall bladder** lumen is moderately distended. The wall is thin and smooth. A small amount of gravity dependent, echogenic to mineralized debris is observed within the lumen. The cystic and common bile ducts are normal/not seen.

INVOICE

11735

Gastrointestinal

The **stomach and intestine** are free of stasis and exhibit normal peristaltic activity. The gastric lumen is not distended. The gastric wall and pylorus are normal in thickness with a normal layering pattern. The pyloric outflow tract is patent. The small intestinal lumen is not dilated. The small intestinal wall thickness is

DATE

9.28.22

normal with a normal layering pattern and appropriate mural detail. Discreet masses are not identified. The colonic wall is normal. There is no evidence of an obstructive pattern.

Pancreas

The **pancreas** is normal in size with normal peripheral contours. The pancreatic duct is normal. The base and limbs of the pancreas are isoechoic to surrounding omental fat. No focal lesions are observed. There is no evidence of peripancreatic inflammation or effusion.

Free Abdomen

The **peritoneal cavity** is normal. There is no evidence of inflammation or effusion. The abdominal **lymph nodes** are normal/not visible.

ULTRASONOGRAPHIC FINDINGS

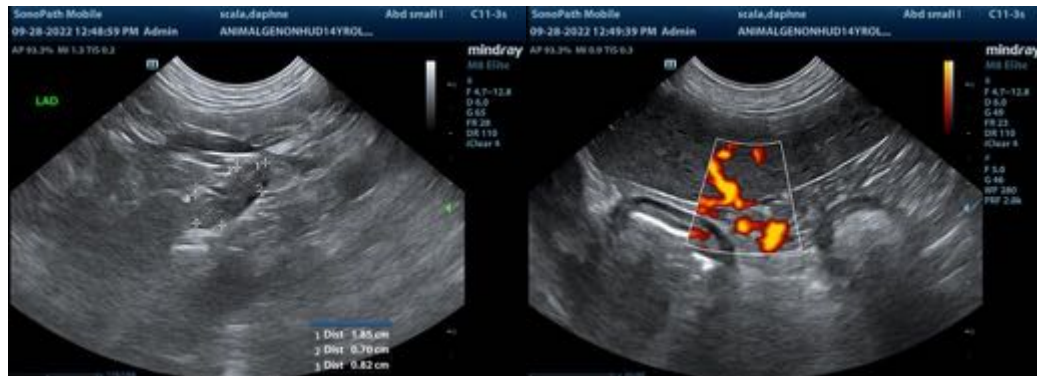Primary Findings

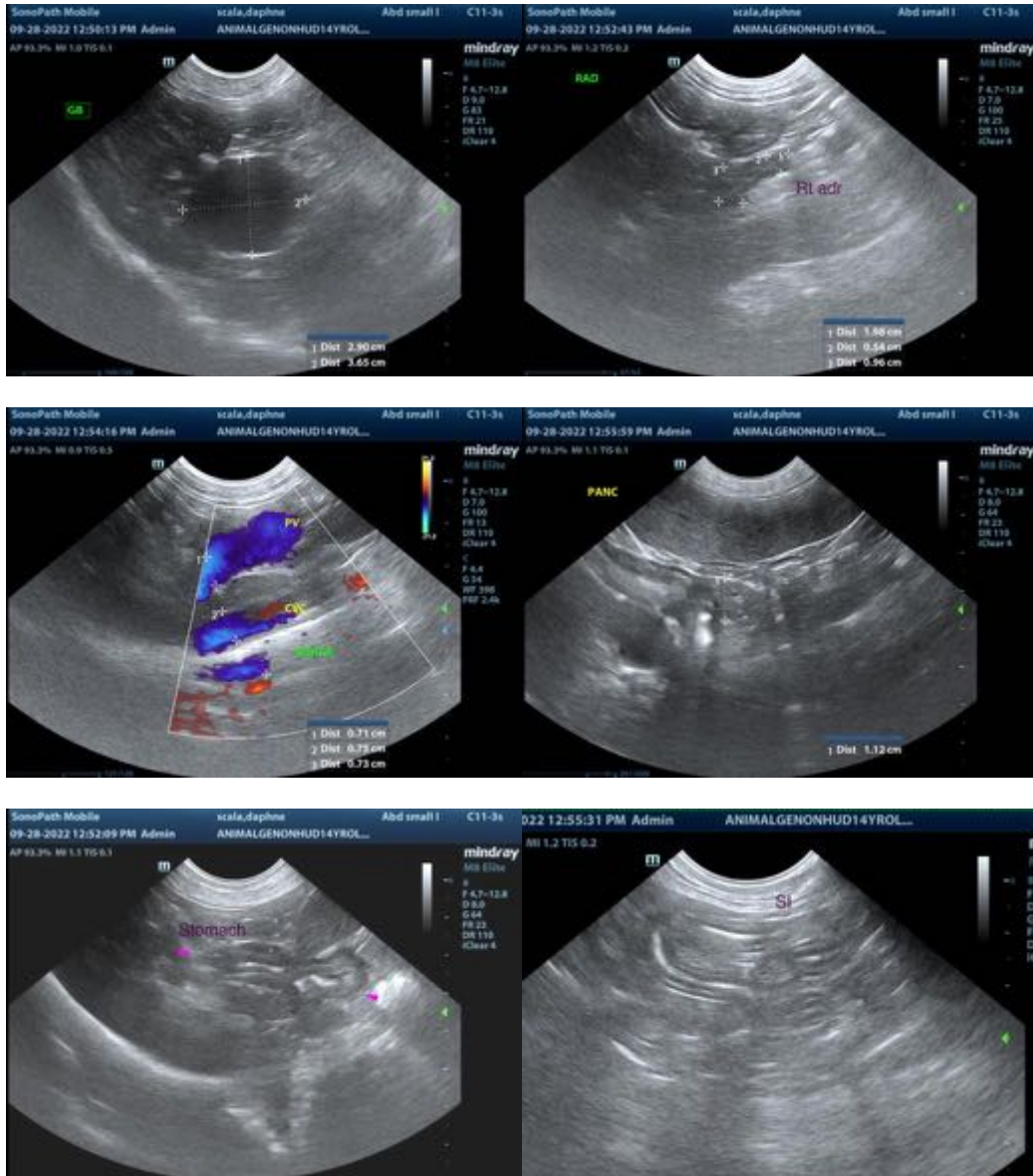
- The splenic parenchymal changes are most consistent with a benign process such as lymphoid hyperplasia, extramedullary hematopoiesis, splenitis or antigenic stimulation with a low possibility of infiltrative neoplasia (i.e., lymphoma, mast cell neoplasia).

*An obvious cause for the patient's lethargy and thrombocytopenia is not definitively identified in this study.

INTERPRETATION OF THE FINDINGS & FURTHER RECOMMENDATIONS

Given the thrombocytopenia, consider a comprehensive tick panel (send to NC State Vector-borne Disease Lab) as well as three-view thoracic radiographs to assess for occult disease in the chest. Consider initiation of doxycycline while awaiting test results.





The information and recommendations provided are based on the images presented by the referring veterinarian/sonographer. No evaluation can be communicated regarding pathology that was not visible in the image/video clips provided.

Thank you for this referral. If the clinical or image interpretation does not parallel your findings or if I can be of any further assistance, please contact me.

Andrea Nicastro, MPH, DVM, Diplomate DACVIM (Small Animal Internal Medicine)
info@SonoPath.com