

**PATIENT PRESENTING CLINICAL SIGNS**

Allie Weeks History: Progressive weight loss (approx. 2 lbs since May 2021), slight PU/PD. No current meds.

**SPECIES** Abnormal PE/Chem/CBC/UA Results: ALP 263, (history of mild elevation), LDDT was normal in Oct. 2020. U/A: 1+ protein, UPC 0.1, USG 1.054.

Canine

**ULTRASONOGRAPHIC EXAMINATION OF THE ABDOMEN**

**BREED** *Urinary System*

Maltese Mix The urinary bladder, trigone, and pelvic urethra are normal in thickness and the mucosal surface is smooth. The bladder lumen is moderately distended with anechoic urine. No masses, inflammatory changes or calculi are observed. Ureteral papillae and visualized portion of the proximal urethra, visible to a depth of 2.0 cm, are normal.

**SEX**

Spayed Female The left kidney presented normal size (3.96 cm in length); normal shape and architecture with smooth peripheral margins. There is a normal 1:3 cortex to medulla ratio with normal corticomedullary distinction. There is no evidence of pyelectasia, nephroliths, infarcts or hydroureter. Renal vasculature is normal.

**AGE**

11 Years The right kidney presented normal size (4.33 cm in length); normal shape and architecture with smooth peripheral margins. There is a normal 1:3 cortex to medulla ratio with normal corticomedullary distinction. There is no evidence of pyelectasia, nephroliths, infarcts or hydroureter. Renal vasculature is normal.

**WEIGHT**

15.8 Pounds *Adrenal Glands*  
The left adrenal gland is normal size (0.41 cm at cranial pole) (0.36 cm at caudal pole) (1.40 cm in length); normal shape; homogenous parenchyma. The glandular echogenicity and detail are unremarkable. Capsule, cortex, and medullary definition are normal. The phrenicoabdominal vein and surrounding vasculature are normal.

**INTERPRETED BY**

Andrea Nicastro, DMV,  
Diplomate DACVIM  
(Small Animal  
Internal Medicine)

The right adrenal gland is normal size (1.19 cm at cranial pole) (0.46 cm at caudal pole) (1.32 cm in length); normal shape; homogenous parenchyma. The glandular echogenicity and detail are unremarkable. Capsule, cortex, and medullary definition are normal. The phrenicoabdominal vein and surrounding vasculature are normal.

*Spleen*

**HOSPITAL NAME**

Millburn VH The spleen is subjectively normal in size, measuring 1.30 cm in width at the level of the hilus with a normal curvilinear peripheral contours. Several ill-defined hypoechoic nodules/areas are observed throughout the organ. Splenic vasculature is normal with no evidence of thrombosis.

*Liver*

**REFERRING VET**

Dr. Turowsky The liver is subjectively enlarged with slightly swollen peripheral contours. The parenchyma is isoechoic relative to the spleen and diffusely homogeneous in appearance. No distinct focal lesions are observed. Vascular and biliary tracts are of normal volume with no evidence of congestion.

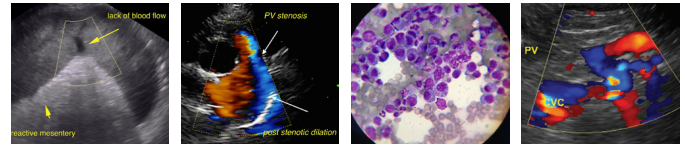
**INVOICE NUMBER**

13330 The gall bladder lumen is moderately distended. The wall is thin and smooth. Luminal contents are anechoic. The cystic and common bile ducts are normal.

*Gastrointestinal*

**DATE**

9/28/21



**PATIENT** Allie Weeks  
The stomach and intestine are free of stasis and exhibit normal peristaltic activity. The gastric lumen is not distended. The gastric wall and pylorus are normal in thickness with a normal layering pattern. The small intestinal lumen is segmentally dilated with gas and chyme. The small intestinal wall thickness is normal with a normal layering pattern and appropriate mural detail. Discreet masses are not identified. The colonic wall is normal. No obstructive or overt infiltrative disease is noted.

**SPECIES** Canine  
**Pancreas**  
The region of the pancreas is isoechoic relative to surrounding omental fat. No obvious parenchymal abnormalities are observed. There is no evidence of regional inflammation or effusion.

**BREED** Maltese Mix  
**Free Abdomen**  
The peritoneal cavity is normal. There is no evidence of inflammation or effusion.  
The abdominal lymph nodes are normal/not visible.

**SEX** Spayed Female  
**ULTRASONOGRAPHIC FINDINGS**

- The diffuse hepatic changes are non-specific and could be consistent with vacuolar hepatopathy, regenerative nodular hyperplasia, and/or age-related remodeling. Inflammatory and infiltrative disease are considered unlikely.
- The splenic parenchyma changes are most consistent with a benign process such as lymphoid hyperplasia, extramedullary hematopoiesis or splenitis with a low possibility of infiltrative neoplasia (i.e., lymphoma, mast cell neoplasia).

**AGE** 11 Years  
**WEIGHT** 15.8 Pounds  
\*An obvious cause for the patients' weight loss is not identified in the study. Considerations include primary gastrointestinal disease (i.e., inflammatory bowel disease, food allergy), occult neoplasia, underlying metabolic disorder, other.

**INTERPRETATION OF THE FINDINGS & FURTHER RECOMMENDATIONS**

- 3 view thoracic radiographs are recommended to assess for occult neoplasia
- A fine needle aspirate of the spleen can also be considered to evaluate for round cell neoplasia. A 25-gauge needle should be used for aspiration and clotting time should be assessed prior to the procedure
- Other diagnostic considerations include the following:
  1. Malabsorption panel
  2. A fecal evaluation for ova/Giardia
  3. A resting cortisol level to screen for hypoadrenocorticism. If resting cortisol level is < 2.0 mcg/dL, an ACTH stimulation test is recommended
  4. A thorough neurologic examination as primary brain tumors can present with weight loss as the sole clinical sign
  5. Depending on the results of the above diagnostics, endoscopic or surgical gastrointestinal biopsies may be warranted

**INTERPRETED BY**

Andrea Nicastro, DMV,  
Diplomate DACVIM  
(Small Animal  
Internal Medicine)

**HOSPITAL NAME**

Millburn VH

**REFERRING VET**

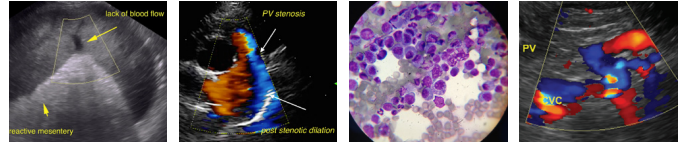
Dr. Turowsky

**INVOICE NUMBER**

13330

**DATE**

9/28/21



**PATIENT**

Allie Weeks

**SPECIES**

Canine

**BREED**

Maltese Mix

**SEX**

Spayed Female

**AGE**

11 Years

**WEIGHT**

15.8 Pounds

**INTERPRETED BY**

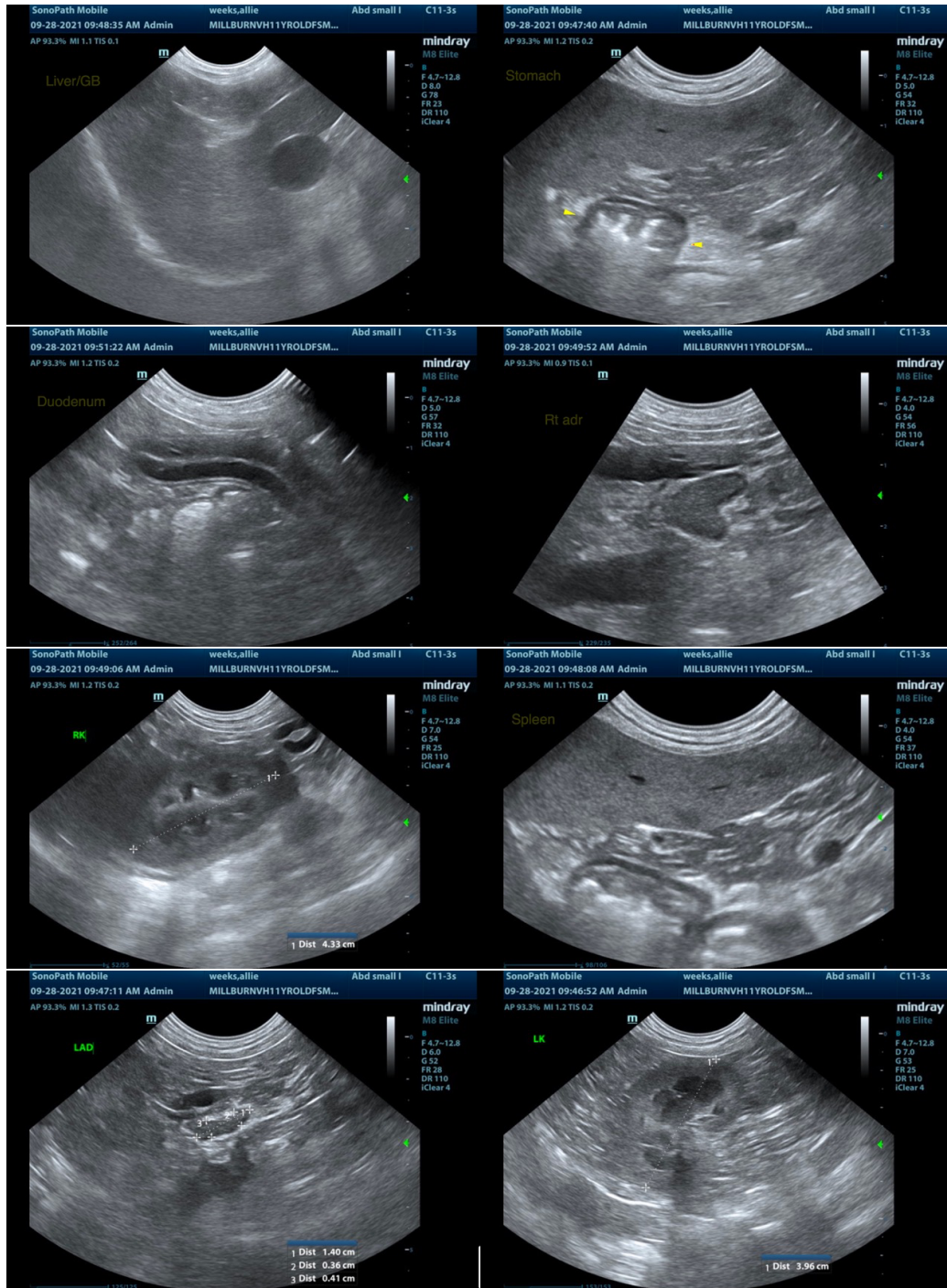
Andrea Nicastro, DMV,  
Diplomate DACVIM  
(Small Animal  
Internal Medicine)

**HOSPITAL NAME**

Millburn VH

**REFERRING VET**

Dr. Turowsky

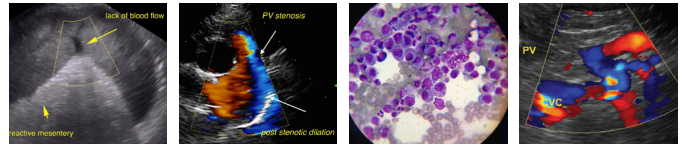


**INVOICE NUMBER**

13330

**DATE**

9/28/21



**PATIENT**

Allie Weeks

**SPECIES**

Canine

**BREED**

Maltese Mix

**SEX**

Spayed Female

**AGE**

11 Years

**WEIGHT**

15.8 Pounds

**INTERPRETED BY**

Andrea Nicastro, DMV,  
Diplomate DACVIM  
(Small Animal  
Internal Medicine)

**HOSPITAL NAME**

Millburn VH

**REFERRING VET**

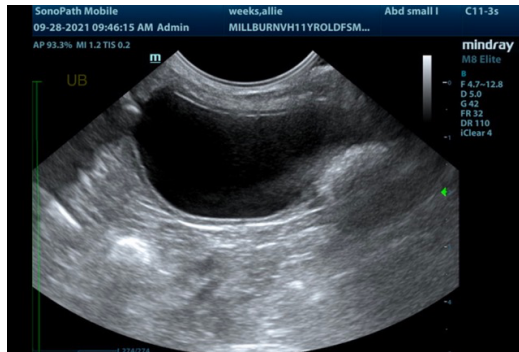Dr. Turowsky

**INVOICE NUMBER**

13330

**DATE**

9/28/21



The information and recommendations provided are based on the images presented by the referring veterinarian. No evaluation can be communicated regarding pathology that was not visible in the image/video clips provided.

Thank you for this referral. If the clinical or image interpretation does not parallel your findings or if I can be of any further assistance please contact me.

**Andrea Nicastro, DVM, Diplomate DACVIM (Small Animal Internal Medicine)**  
info@SonoPath.com