



PATIENT PRESENTING CLINICAL SIGNS

Mia Casale Abnormal PE/Chem/CBC/UA Results: 8/25/22: WBC 18,200 (neutrophils), HCT 20%, retic 13.07, 476, 400, albumin 2.6, rest WNL. T4: 0.7. U/A: UTI, USG 1.016, 51-100 rods, 2+ blood, 21-50 WBC, pH 7.5, rest WNL.

SPECIES

Canine

BREED

Rhodesian Ridgeback

SEX

Spayed Female

AGE

10 years

WEIGHT

74 lbs

INTERPRETED BY

Andrea Nicastro,
DVM, Diplomate
ACVIM (*Small Animal
Internal Medicine*)

**IMAGING
PERFORMED BY**

Kelly Vazquez

HOSPITAL NAME

Hillsdale AH

REFERRING VET

Dr. Kenneth Fischer

INVOICE

11712

DATE

9.27.22

ULTRASONOGRAPHIC EXAMINATION OF THE ABDOMEN

Urinary System

The **urinary bladder** is moderately distended with anechoic urine. The wall in the region of the apex is mildly thickened (up to 0.44 cm) with a slightly irregular mucosal surface. Luminal contents are mostly anechoic. No cystic calculi are observed. The region of the trigone and the proximal urethra, visible to a depth of 2-3 cm, are normal.

The **left kidney** is normal size (7.09 cm in length); normal shape and architecture with smooth peripheral margins. There is a normal 1:3 cortex to medulla ratio with minimal loss of corticomedullary distinction. There is no evidence of pyelectasia, nephroliths, infarcts or hydronephrosis. Renal vasculature is normal.

The **right kidney** is normal size (5.51 cm in length); normal shape and architecture with smooth peripheral margins. There is a normal 1:3 cortex to medulla ratio with minimal to mild loss of corticomedullary distinction. There is no evidence of pyelectasia, nephroliths, infarcts or hydronephrosis. Renal vasculature is normal.

Adrenal Glands

The **left adrenal gland** is normal size (0.48 cm at cranial pole) (0.60 cm at caudal pole) (2.78 cm in length); normal shape; homogenous parenchyma. The glandular echogenicity and detail are unremarkable. Capsule, cortex, and medullary definition are normal. The phrenicoabdominal vein and surrounding vasculature are normal.

The region of the **right adrenal gland** is evaluated. No obvious pathology is observed.

Spleen

The **spleen** is subjectively enlarged with irregular peripheral contours. At the cranial aspect, a 4.30 cm isoechoic to mildly heterogeneous swelling/mass is visualized. Adjacent to the mass, an ill-defined hypoechoic to mildly heterogeneous area is observed (external to the spleen). At the caudal aspect, a well-demarcated hypoechoic area measuring 3.25 x 1.76 cm is visualized. The mesentery surrounding this region is hyperechoic. The remaining parenchyma is relatively homogenous. Splenic vasculature at the hilum appears normal.

Liver

The **liver** is subjectively enlarged with irregular peripheral contours. Throughout the liver, numerous, varying-sized hypoechoic to heterogeneous masses are visualized. Several of the masses cause capsular expansion and distortion of the normal hepatic architecture. Hepatic vasculature and intrahepatic biliary tracts are of normal volume with no evidence of congestion.

The **gall bladder** lumen is moderately distended. The wall is thin and smooth. Luminal contents are anechoic. The cystic and common bile ducts are normal/not seen.

Gastrointestinal

The **gastric lumen** is mildly to moderately distended with ingesta. The gastric wall is normal in thickness with a normal layering pattern. The small intestinal lumen is segmentally dilated with chyme. An approximately 2.00 cm small intestinal mass (suspected to be jejunum) is visualized. The wall in this region is thickened (up to 0.85 cm) with a complete loss of the normal layering pattern. The mesentery effacing the

serosal surface in this region is hyperechoic. In the remaining small intestinal segments, the wall is normal in thickness with a normal layering pattern. The colonic wall is normal. There is no obvious evidence of an obstructive pattern.

Pancreas

The region of the **pancreas** is isoechoic relative to surrounding omental fat. No obvious parenchymal abnormalities are observed. There is no evidence of regional inflammation or effusion.

Free Abdomen

Trace free fluid is observed. The abdominal **lymph nodes** are normal/not visible.

Other

The **uterine stump** is visible and is prominent in size (0.90 cm in width). There is no obvious evidence of luminal distention.

ULTRASONOGRAPHIC FINDINGS

Primary Findings

- Diffuse hepatic masses. Neoplasia (i.e., round cell tumor) is considered likely with a lower possibility of multifocal inflammatory disease.
- Splenic mass with suspected adjacent thrombus. Again, neoplasia is suspected. The lesion at the caudal aspect of the spleen may represent a region of infarction, neoplasia, extramedullary hematopoiesis, or other pathology.
- Focal small intestinal mass. Neoplasia is suspected with a lower possibility of a severe focal inflammatory process.
- The free fluid is likely secondary to splenic, hepatic and/or bowel pathology.

Secondary Findings

- Prominent uterine stump, which may be secondary to Incurin therapy. Stump pyometra is a consideration. Correlation with the patient's clinical history is recommended.
- The thickened urinary bladder wall is suggestive of cystitis.

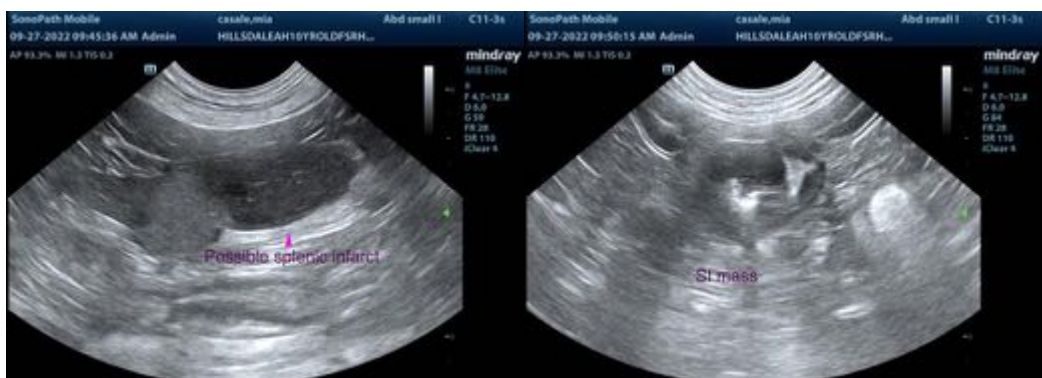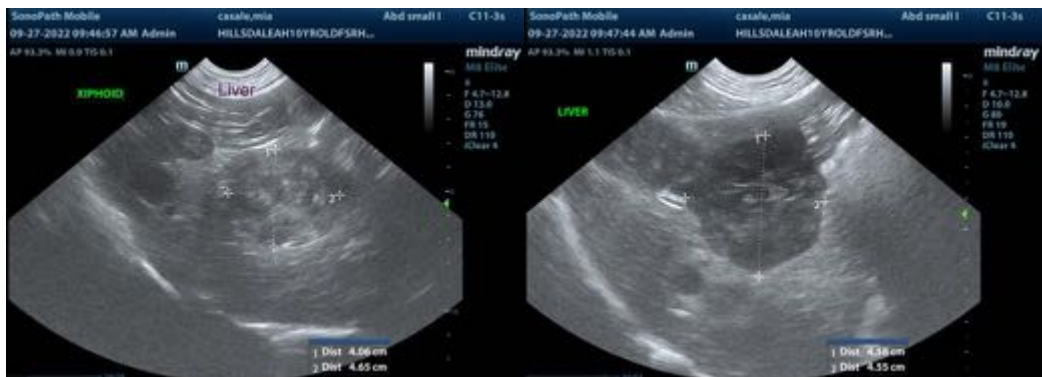
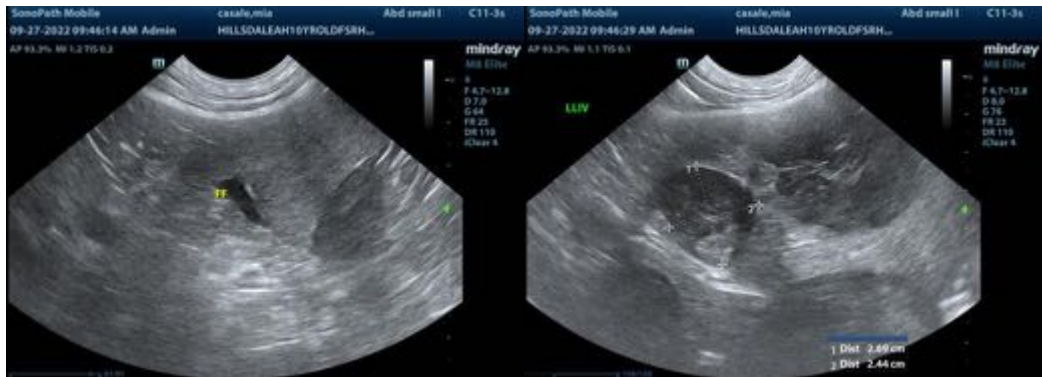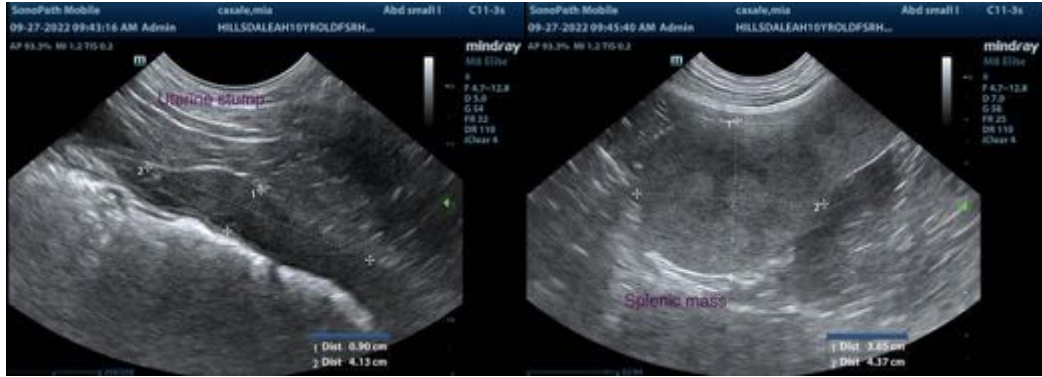INTERPRETATION OF THE FINDINGS & FURTHER RECOMMENDATIONS

Three-view thoracic radiographs are recommended to assess for pulmonary metastases.

Consider fine-needle aspirates of the splenic and hepatic masses if clotting status is appropriate. Twenty-five gauge-needles should be used.

Regarding the urinary bladder and uterine changes, consider the following:

1. Urine culture and sensitivity
2. Vaginal cytology
3. Discontinuation of Incurin with a repeat ultrasound in 3-4 weeks to reassess the uterine stump.



The information and recommendations provided are based on the images presented by the referring veterinarian/sonographer. No evaluation can be communicated regarding pathology that was not visible in the image/video clips provided.

Thank you for this referral. If the clinical or image interpretation does not parallel your findings or if I can be of any further assistance, please contact me.

Andrea Nicastro, MPH, DVM, Diplomate DACVIM (Small Animal Internal Medicine)
info@SonoPath.com