



**PATIENT PRESENTING CLINICAL SIGNS**

Lila Wilner History: not eating / vomiting / adr

**SPECIES ULTRASONOGRAPHIC EXAMINATION OF THE ABDOMEN**

Canine *Urinary System*

**BREED** Pointer  
The urinary bladder is moderately distended with anechoic urine. The wall in the ventroapical region is mildly thickened (up to 0.46 cm) with a mildly irregular mucosal surface. The bladder wall tapers to a normal thickness as it extends toward the urinary bladder neck. No cystic calculi are observed. The region of the trigone and the visible portion of the proximal urethra are normal.

**SEX** Female  
The left kidney is normal size (6.68 cm in length); normal shape and architecture with smooth peripheral margins. There is a normal 1:3 cortex to medulla ratio with normal corticomedullary distinction. Mild pyelectasia is present (0.31 cm in the longitudinal plane). There is no evidence of nephroliths, infarcts or hydroureter.

**AGE** 12 Yrs.  
The right kidney is normal size (6.44 cm in length); normal shape and architecture with smooth peripheral margins. There is a normal 1:3 cortex to medulla ratio with normal corticomedullary distinction. Mild pyelectasia is present (0.28 cm in the longitudinal plane). There is no evidence of nephroliths, infarcts or hydroureter.

**WEIGHT Adrenal Glands**

67 lbs.  
The left adrenal gland is normal size (0.64 cm at cranial pole) (0.78 cm at caudal pole) (3.10 cm in length); normal shape; homogenous parenchyma. The glandular echogenicity and detail are unremarkable. Capsule, cortex, and medullary definition are normal. The phrenicoabdominal vein and surrounding vasculature are normal.

**INTERPRETED BY**

Andrea Nicastro, DVM,  
Diplomate ACVIM  
(Small Animal Internal  
Medicine)

The right adrenal gland is not definitively visualized.

*Spleen*

The spleen is normal in size (1.70 cm in width at the level of the hilus) with a normal capsular contour. The parenchyma is mottled in appearance. A 1.90 x 1.83 cm hypoechoic nodule is observed at the caudal pole. The lesion causes capsular expansion. In addition, a 2.57 x 1.50 cm heterogeneous swelling/mass is observed at the cranial aspect. This lesion also causes capsular expansion. Myelolipomas are observed adjacent to vessels at the hilus. Splenic vasculature appears normal with no evidence of thrombosis. A 2.06 x 1.59 cm hypoechoic mass is also present and contains ill-defined mineralized foci.

**IMAGING PERFORMED BY**

Dr. Scott

**HOSPITAL NAME**

Ho Ho Kus VH

*Liver*

The liver is subjectively enlarged with irregular peripheral contours. A 3.86 x 2.81 cm hyperechoic to slightly heterogeneous mass is observed in the left caudal aspect. The mass causes capsular expansion. The remaining hepatic parenchyma is hypoechoic relative to the spleen and diffusely mottled in appearance. Vascular and biliary tracts are of normal volume with no evidence of congestion. The gall bladder lumen is moderately distended. The wall is normal in thickness. Several polypoid like lesions are arising from the luminal surface. A moderate amount of aggregated echogenic suspended sludge in a partially stellate pattern is observed within the lumen. The cystic and common bile ducts are normal/not seen.

**REFERRING VET**

Dr. Eisenberg

**INVOICE**

11259

*Gastrointestinal*

**DATE**

9/24/21



## PATIENT

Lila Wilner

The stomach and intestine are free of stasis and exhibit normal peristaltic activity. The gastric lumen is not distended. The gastric wall and pylorus are normal in thickness with a normal layering pattern. The pyloric outflow tract is patent. The small intestinal lumen is not dilated. The small intestinal wall thickness is normal with a normal layering pattern and appropriate mural detail. Discreet masses are not identified. A portion of the descending colonic wall is thickened (up to 0.67 cm) with retention of the normal layering pattern. No obstructive disease is noted.

## SPECIES

Canine

### *Pancreas*

## BREED

Pointer

The region of the pancreas is isoechoic relative to surrounding omental fat. No obvious parenchymal abnormalities are observed. There is no evidence of regional inflammation or effusion.

### *Free Abdomen*

## SEX

Female

The peritoneal cavity is normal. There is no evidence of inflammation or effusion. The abdominal lymph nodes are normal/not visible.

## AGE

12 Yrs.

## ULTRASONOGRAPHIC FINDINGS

### Primary Findings:

- Multiple splenic nodules/masses. These changes are concerning for neoplasia with a lower possibility of benign pathology.
- Left caudal hepatic mass. Neoplasia (i.e., adenoma, adenocarcinoma) is considered likely with a lower possibility of benign change (i.e., regenerative nodular hyperplasia). The diffuse hepatic parenchymal changes are non-specific and could be secondary to infiltrative neoplasia, inflammatory disease, hepatotoxicosis (i.e., copper) and/or age-related pathology.
- The gallbladder changes are suggestive of a developing mucocele.

### Secondary Findings:

- The mild bilateral pyelectasia may be secondary to age-related remodeling, pyelonephritis or fluid therapy, if applicable.
- The colonic wall changes are most consistent with an inflammatory process.
- The urinary bladder wall changes are suggestive of cystitis. However, correlation with clinical findings is recommended.

## INTERPRETED BY

Andrea Nicastro, DVM,  
Diplomate ACVIM  
(*Small Animal Internal  
Medicine*)

## IMAGING PERFORMED BY

Dr. Scott

## HOSPITAL NAME

Ho Ho Kus VH

## REFERRING VET

Dr. Eisenberg

## INVOICE

11259

## DATE

9/24/21

## INTERPRETATION OF THE FINDINGS & FURTHER RECOMMENDATIONS

- Three-view thoracic radiographs are recommended to assess for pulmonary metastases.
- Fine needle aspirates of the hepatic and splenic masses are recommended if accessible and if clotting status is appropriate. 25-gauge needles should be used. If cytology results are inconclusive, surgical biopsies may be necessary to get a definitive diagnosis. Given the patient's clinical signs, if surgery is pursued gastrointestinal biopsies should also be obtained.
- Baseline labwork including a CBC chemistry panel, urinalysis and T4 is recommended to assess metabolic function if not already performed.
- Given the gall bladder changes, Ursodeoxycholic acid (Ursodiol) is recommended. Serial



**PATIENT**

sonographic monitoring (e.g., every 6-8 weeks) of the gall bladder is recommended to assess for progression to a fully-formed mucocele.

Lila Wilner

**SPECIES**

Canine

**BREED**

Pointer

**SEX**

Female

**AGE**

12 Yrs.

**WEIGHT**

67 lbs.

**INTERPRETED BY**

Andrea Nicastro, DVM,  
Diplomate ACVIM  
(Small Animal Internal  
Medicine)

**IMAGING  
PERFORMED BY**

Dr. Scott

**HOSPITAL NAME**

Ho Ho Kus VH

**REFERRING VET**

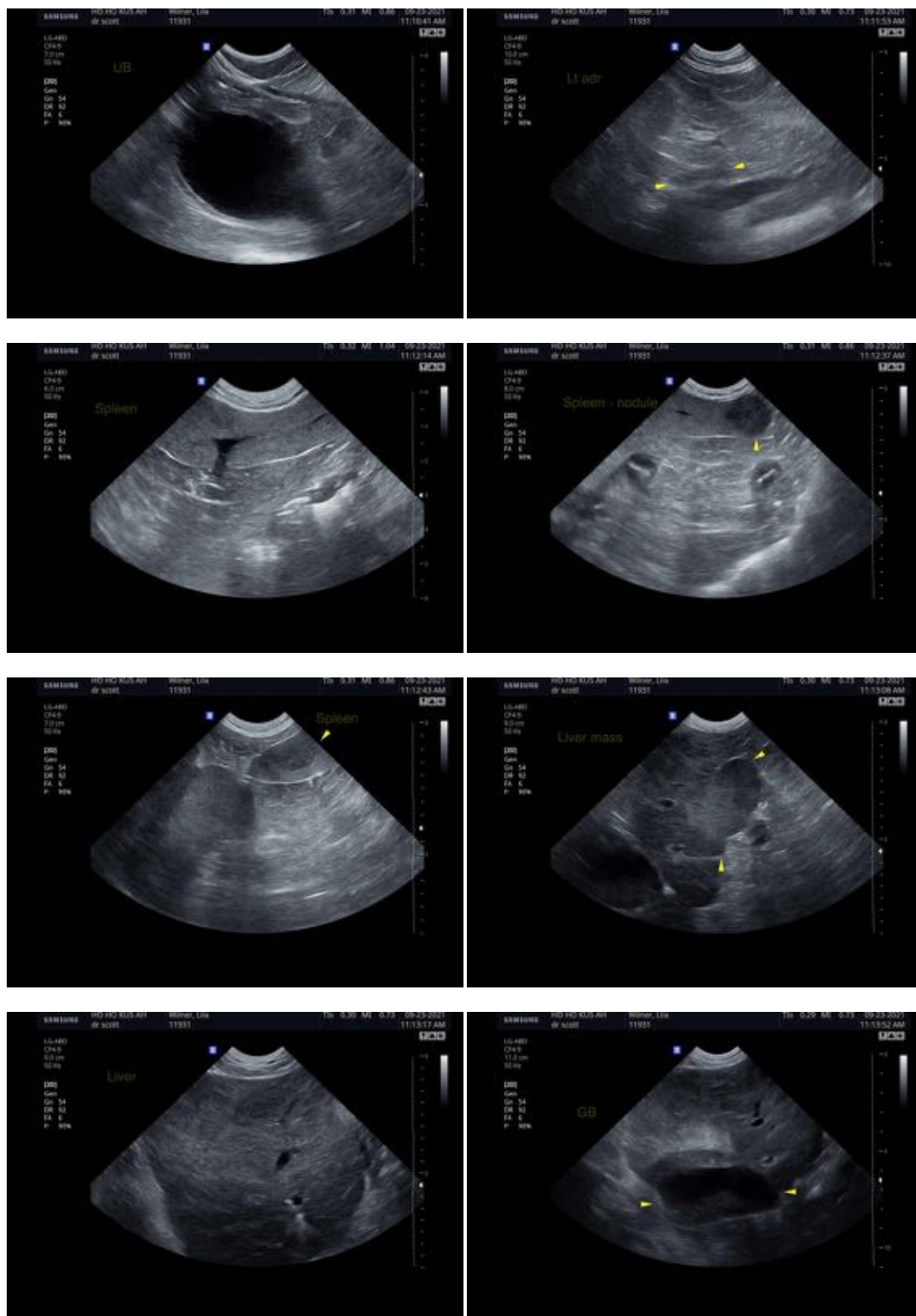
Dr. Eisenberg

**INVOICE**

11259

**DATE**

9/24/21





**PATIENT**

Lila Wilner

**SPECIES**

Canine

**BREED**

Pointer

**SEX**

Female

**AGE**

12 Yrs.

**WEIGHT**

67 lbs.

**INTERPRETED BY**

Andrea Nicastro, DVM,  
Diplomate ACVIM  
(*Small Animal Internal  
Medicine*)

**IMAGING  
PERFORMED BY**

Dr. Scott

**HOSPITAL NAME**

Ho Ho Kus VH

**REFERRING VET**

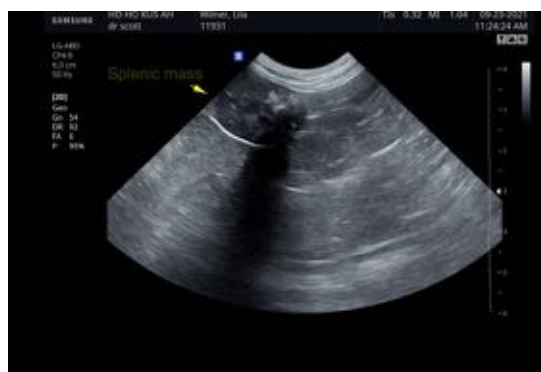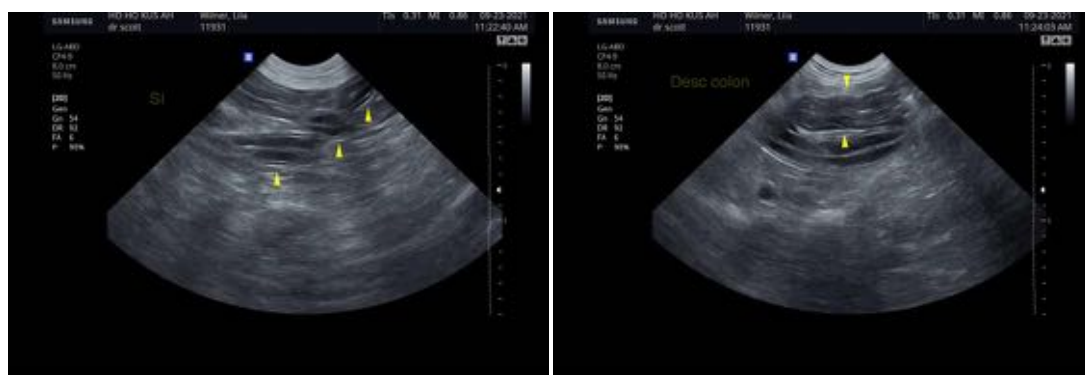
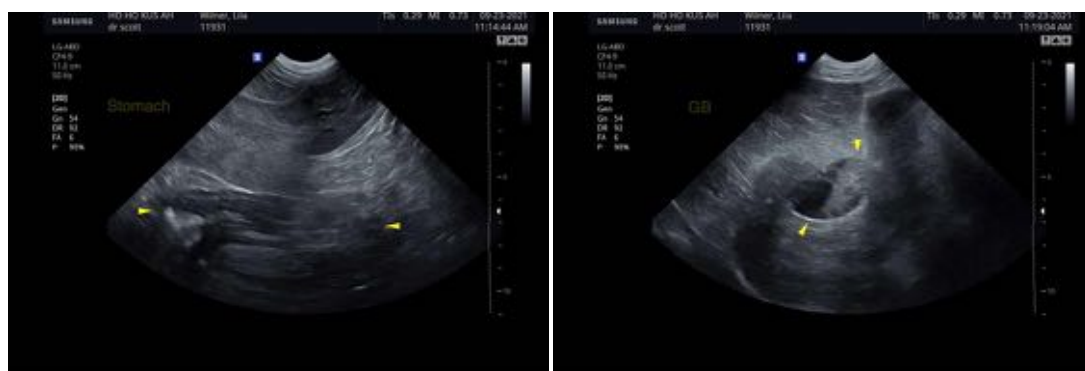
Dr. Eisenberg

**INVOICE**

11259

**DATE**

9/24/21



The information and recommendations provided are based on the images presented by the referring veterinarian. No evaluation can be communicated regarding pathology that was not visible in the image/video clips provided.

Thank you for this referral. If the clinical or image interpretation does not parallel your findings or if I can be of any further assistance please contact me.

Andrea Nicastro, DVM, Diplomate ACVIM (*Small Animal Internal Medicine*)

Andrea.nicastro@sonopath.com