

**DATE PRESENTING CLINICAL SIGNS**

9/24/21

History: Presenting Complaint: Diabetic Ketoacidosis; Vomiting; Not Eating. Date: 09-21-2021 Notes: O came home to V/D, very unlike patient to have accidents. Ate normally this AM, did not offer dinner. Seemed to drink a lot of water today. Lethargic, BG 206. Did not give insulin or meds this evening. Saw rDVM Sat for post-OP dental check after 3 wks. - all good. Assessment: PC: ADR, V/D, anorexia, abdominal distention/discomfort, Hx DM, Hx Cushing's, Hx hypertension. Plan: aFAST = scant FF between liver lobes. SWO: Concern for pancreatitis with multiple underlying conditions. Rec aggressive Tx incl BW, rads, IVF, UA. Ideally rec US but may not have availability until Friday - take it one day at a time. O consents to plan.

**PATIENT**

Chandler McDermott

**SPECIES**

Canine

Current Medications: Trilostane, Clavamox, Maropitant, Omeprazole, multiple eye medications, Metronidazole, Benazepril, insulin- NPH.

**BREED**

Chihuahua

Lab Results: Mildly anemic, hematocrit 33%, white count 18,000 with a mild neutrophilia, ALT 247, ALKP 1805, BUN 56 with a normal creatinine

**SEX**

Male Neutered

Radiographs: severe hepatomegaly and loss of detail cranial abdomen redundant trachea.

Date of Previous IntraPet Ultrasound: No previous IntraPet scans.

**AGE**

10/21/09

Sedation: Sedation not required for scan.

Stat Report: STAT report not requested by the veterinarian.

**WEIGHT**

11.6 lbs.

**ULTRASONOGRAPHIC EXAMINATION OF THE ABDOMEN****Urinary System**

The urinary bladder, trigone, and pelvic urethra are normal in thickness and the mucosal surface is smooth. The bladder lumen is distended. A small amount of suspended echogenic debris is observed within the lumen. No masses, inflammatory changes or calculi are observed. Ureteral papillae and visualized portion of the proximal urethra, visible to a depth of 2 cm, are normal.

The prostate is normal in size (0.85 cm in width) and shape. Parenchyma is homogenous. The prostatic urethra appears normal without evidence of dilation or obstruction.

**INTERPRETED BY**

Andrea Nicastro, DVM,  
Diplomate ACVIM  
(Small Animal Internal  
Medicine)

**HOSPITAL NAME**

Animal Emergency  
Hospital

The left kidney is normal size (4.27 cm in length); normal shape and architecture with smooth peripheral margins. The cortex is mildly thickened and there is mild to moderate loss of corticomedullary distinction. Hyperechoic shadowing diverticular foci are visualized. There is no evidence of pyelectasia, nephroliths, infarcts or hydroureter.

**REFERRING VET**

Dr. Jones

The right kidney is normal size (4.65 cm in length); normal shape and architecture with smooth peripheral margins. The cortex is mildly thickened and there is mild to moderate loss of corticomedullary distinction. Hyperechoic shadowing diverticular foci are visualized. A few small cortical cysts are seen. There is no evidence of pyelectasia, nephroliths, infarcts or hydroureter.

**INVOICE**

12256

**Adrenal Glands**

The left adrenal gland is mildly enlarged (0.58 cm at cranial pole) (0.86 cm at caudal pole) (2.11 cm in length) with a prominent caudal pole. The parenchyma is slightly hypoechoic with relatively normal glandular detail. No focal lesions are observed. The phrenicoabdominal vein and surrounding vasculature are normal.

The right adrenal gland is enlarged (1.20 cm at cranial pole) (0.93 cm at caudal pole) (1.70 cm in length) with an irregular shape and a subtly heterogeneous parenchyma. There was some loss of glandular detail. Surrounding vasculature appears normal. The mesentery effacing the serosal surface is hyperechoic.

### *Spleen*

The spleen is normal in size (1.36 cm in width at the level of the hilus) with a normal capsular contour. There is appropriate echogenicity and echotexture. A 0.93 x 0.82 cm irregular hypoechoic nodule is observed at the mid to caudal aspect. Splenic vasculature is normal.

### *Liver*

The liver is subjectively enlarged with rounded peripheral contours. The parenchyma is isoechoic relative to the spleen. A 3.41 x 2.38 cm irregular hyperechoic to heterogeneous mass is observed deep on the left side. The mass causes mild capsular expansion. The remaining parenchyma is homogeneous. Vascular and biliary tracts are of normal volume with no evidence of congestion. The gall bladder lumen is moderately distended. The wall is slightly thickened, irregular and hyperechoic. A small to moderate amount of aggregated echogenic stranding sludge is observed within the lumen. The cystic and common bile ducts are normal/not seen.

### *Gastrointestinal*

The stomach and intestine are free of stasis and exhibit normal peristaltic activity. The gastric lumen is not distended. The gastric wall and pylorus are normal in thickness with a normal layering pattern. The pyloric outflow tract is patent. The small intestinal lumen is not dilated. The small intestinal wall thickness is normal with a normal layering pattern and appropriate mural detail. Discreet masses are not identified. The colonic wall is normal. No obstructive disease is noted.

### *Pancreas*

The right limb of the pancreas is prominent in size with minimal deviation from the normal peripheral contours. The parenchyma is slightly hypoechoic relative to surrounding omental fat. No distinct focal lesions are observed. The pancreatic duct is not overtly dilated. The mesentery effacing the serosal surface is hyperechoic.

### *Free Abdomen*

Trace free fluid is observed. The abdominal lymph nodes are normal/not visible.

### *Other*

A brief echocardiogram reveals no evidence of pericardial effusion or obvious chamber enlargement. Several ring down lesions are observed within the thorax.

## **ULTRASONOGRAPHIC FINDINGS**

### **Primary Findings:**

- Hepatic mass. Neoplasia (i.e., adenoma, adenocarcinoma) is considered likely with a lower possibility of benign pathology (i.e., nodular hyperplasia).
- The splenic nodule could be consistent with a neoplastic lesion or a benign focus of lymphoid hyperplasia, extramedullary hematopoiesis or splenitis.
- The bilateral adrenomegaly is consistent with the previous diagnosis of hyperadrenocorticism. There is evidence of retroperitonitis adjacent to the right adrenal gland the significance of which is unclear.
- The pancreatic changes are consistent with mild acute or chronic active pancreatitis.

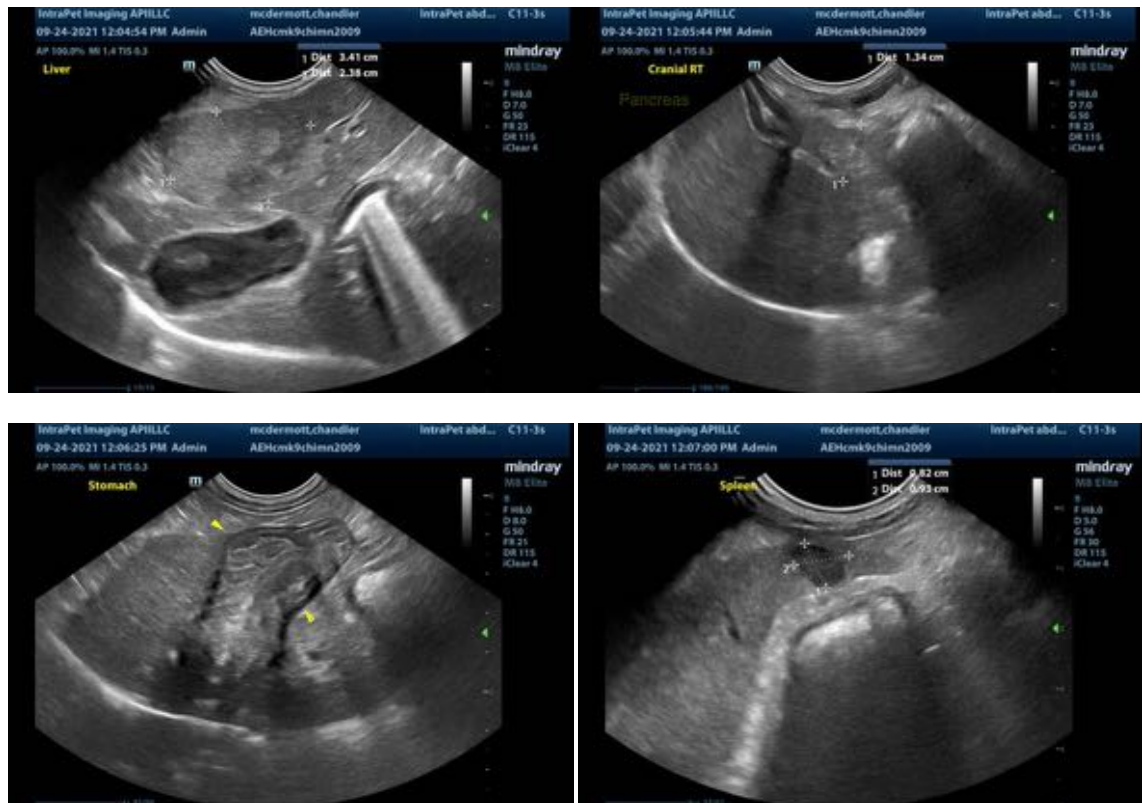
- The gallbladder changes could be consistent with cholestasis, fasting or possibly early mucocele formation.

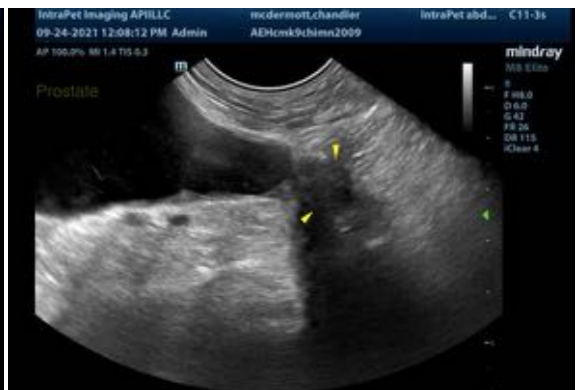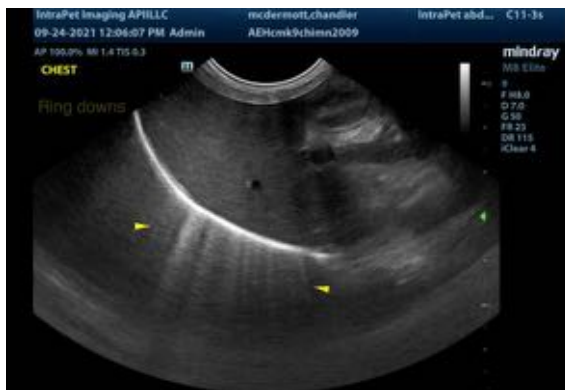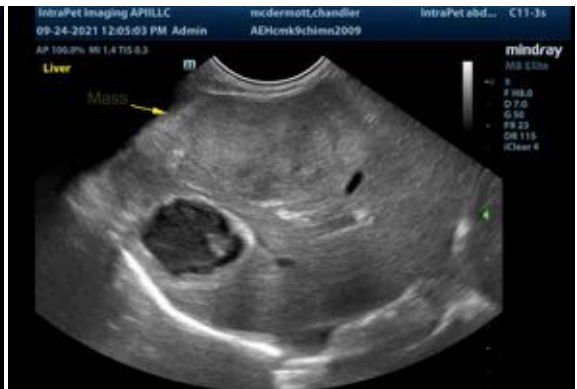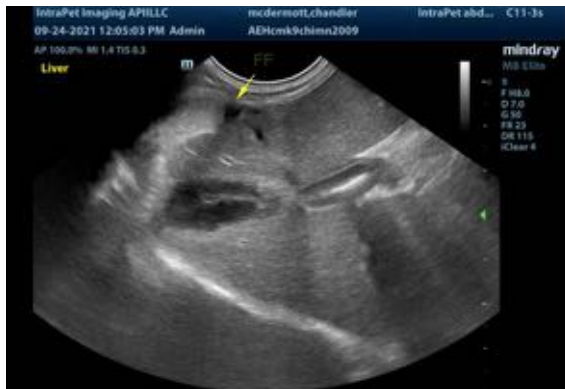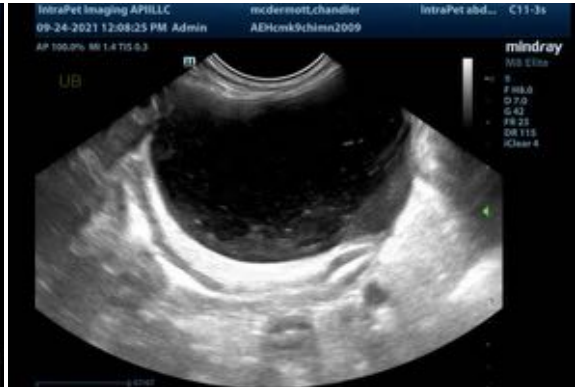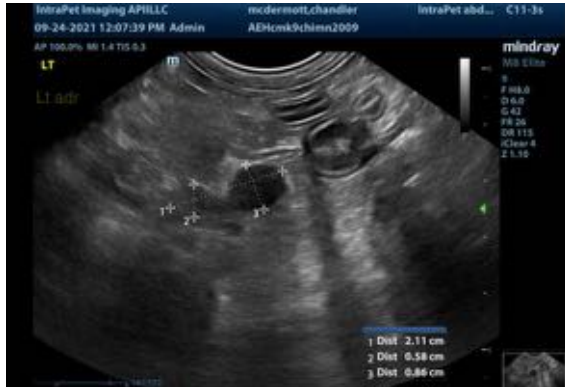**Secondary Findings:**

- Bilateral nephropathy with dystrophic mineralization and right cortical cysts.
- The ring down lesions in the thorax are suggestive of pulmonary parenchymal disease.

**INTERPRETATION OF THE FINDINGS & FURTHER RECOMMENDATIONS**

- Three-view thoracic radiographs are recommended to assess for pulmonary metastases.
- Consider fine needle aspirates of the hepatic mass and splenic nodule (if clotting status is appropriate). 25-gauge needles should be used. It should be noted that cytologic evaluation of primary hepatic tumors is often inconclusive, therefore surgical biopsy may be necessary to get a definitive diagnosis.
- Supportive care for pancreatitis is recommended including IV fluid therapy, gastric protectants, antiemetics and pain medication as needed as well as insulin therapy to address the diabetic ketoacidotic state.





The information and recommendations provided are based on the images presented by the referring veterinarian. No evaluation can be communicated regarding pathology that was not visible in the image/video clips provided.

Thank you for this referral. If the clinical or image interpretation does not parallel your findings or if I can be of any further assistance, please contact me.

Andrea Nicastro, DVM, Diplomate ACVIM (*Small Animal Internal Medicine*)  
 Andrea.nicastro@sonopath.com