

**DATE PRESENTING CLINICAL SIGNS**

9/23/2021

Feline / Domestic Shorthair / Female Spayed / 10-10-2008 / 8.02 Lbs.

History: Has been seen for hyperthyroidism since April 2020.

Recent exam showed NEW gr 3/6 heart murmur and about 1.5# weight loss. Dental disease present.

Elevated liver values on lab work.

PATIENT

Sofie Karnes

Current Medications: Methimazole 7.5mg AM and 5mg PM.

Lab Results: alt: 292, alp: 298 (previously normal as of April 2020)

t4: 4.2 - however, increased dose of Methimazole and owner reports some hair loss.

SPECIES

Feline

Radiographs: Not provided by the veterinarian.

Date of Previous IntraPet Ultrasound: No previous IntraPet scans.

Sedation: Alfaxan administered prior to scan.

Stat Report: STAT report not requested by the veterinarian.

BREED

Domestic shorthair

ULTRASONOGRAPHIC EXAMINATION OF THE ABDOMEN**SEX**

Female, spayed

Urinary System

The urinary bladder, trigone, and pelvic urethra are normal in thickness and the mucosal surface is smooth.

The bladder lumen is mildly distended with mostly anechoic urine. No masses, inflammatory changes or calculi are observed. Ureteral papillae and visualized portion of the proximal urethra, visible to a depth of 2 cm, are normal.

AGE

10/10/2008

The left kidney is normal size (3.63 cm in length); normal shape and architecture with smooth peripheral margins. There is a normal 1:3 cortex to medulla ratio with minimal loss corticomedullary distinction. There is no evidence of pyelectasia, nephroliths, infarcts or hydroureter. Renal vasculature is normal.

WEIGHT

8.02 lbs.

The right kidney is normal size (3.73 cm in length); normal shape and architecture with smooth peripheral margins. There is a normal 1:3 cortex to medulla ratio with minimal loss of corticomedullary distinction. There is no evidence of pyelectasia, nephroliths, infarcts or hydroureter. Renal vasculature is normal.

INTERPRETED BYAndrea Nicastro, DVM,
Diplomate ACVIM
(Small Animal Internal
Medicine)**Adrenal Glands**

The left adrenal gland is normal in size (0.45 cm width). Normal shape and glandular echogenicity. The phrenicoabdominal vein and surrounding vasculature are normal.

HOSPITAL NAMEEverhart Wellpet
Center

The right adrenal gland is normal in size (0.26 cm width). Normal shape and glandular echogenicity. The phrenicoabdominal vein and surrounding vasculature are normal.

Spleen

The spleen is subjectively normal in size (0.69 cm in width at the level of the hilus) with scalloping of the medial contour. There is appropriate echogenicity and echotexture. No focal lesions are observed. Splenic vasculature is normal.

REFERRING VET

Dr. Betta

Liver

The liver is subjectively prominent in size with slightly swollen peripheral contours. The parenchyma is hypoechoic relative to the spleen and diffusely homogeneous in appearance. No focal lesions are observed. Vascular and biliary tracts are of normal volume with no evidence of congestion. The gall bladder lumen is moderately distended. The wall is thin and smooth. A small to moderate amount of mostly gravity-dependent echogenic debris is observed within the lumen. The cystic and common bile ducts are normal/not seen.

INVOICE

12251

Gastrointestinal

The stomach and intestine are free of stasis and exhibit normal peristaltic activity. The gastric lumen is minimally fluid distended. The gastric wall and pylorus are normal in thickness with a normal layering pattern. The pyloric outflow tract is patent. The small intestinal lumen is not dilated. The small intestinal wall thickness is normal with a normal layering pattern and appropriate mural detail. There is disruption in the normal 1:3 muscularis: mucosal ratio in most segments. Discreet masses are not identified. The ileocecal colic junction and colonic wall are normal. No obstructive disease is noted.

Pancreas

The right limb is prominent to enlarged with slightly irregular peripheral contours. The parenchyma is hypoechoic relative to surrounding omental fat. No focal lesions are observed. The pancreatic duct is not overtly dilated. Surrounding mesentery is hyperechoic.

Free Abdomen

There is no evidence of free fluid. A few visible lymph nodes are observed in the mid-abdominal cavity, the largest measuring 0.64 cm in length. Surrounding mesentery is hyperechoic.

ULTRASONOGRAPHIC FINDINGS

Primary Findings:

- Hepatic changes are non-specific and could be consistent with hepatic lipidosis, inflammatory/infectious disease, infiltrative neoplasia (less likely), or other hepatopathy.
- The pancreatic changes are consistent with mild to moderate acute or chronic active pancreatitis.
- Bowel pattern consistent with inflammatory bowel disease with potential for emerging lymphoma.
- The prominent abdominal lymph nodes are most consistent with reactive lymphadenitis or lymphoid hyperplasia. Neoplastic infiltration is considered less likely.

Secondary Findings:

- Minor bilateral age-related renal changes.

*Given the sonographic changes, "triaditis" is a consideration in this patient.

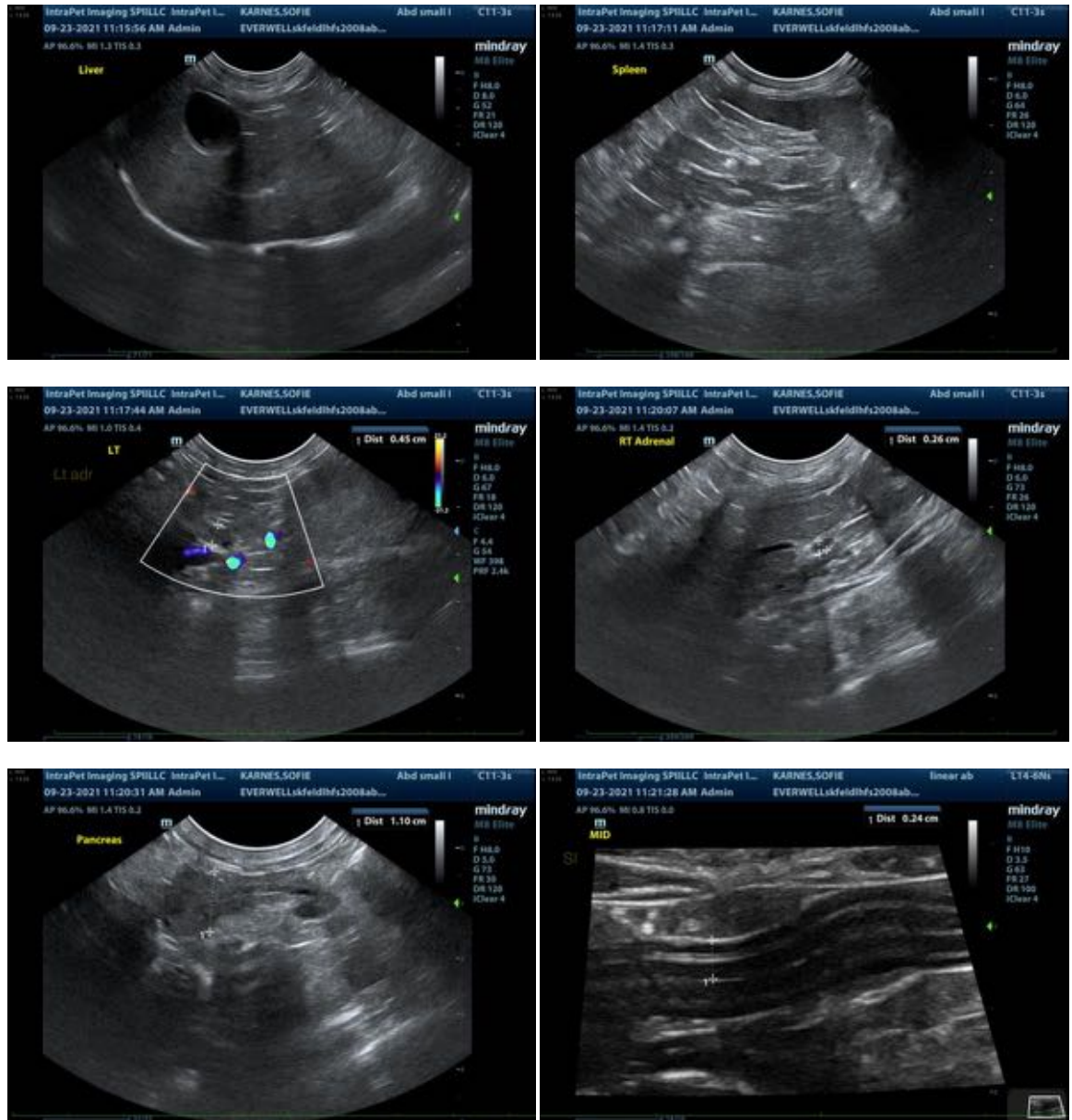
INTERPRETATION OF THE FINDINGS & FURTHER RECOMMENDATIONS

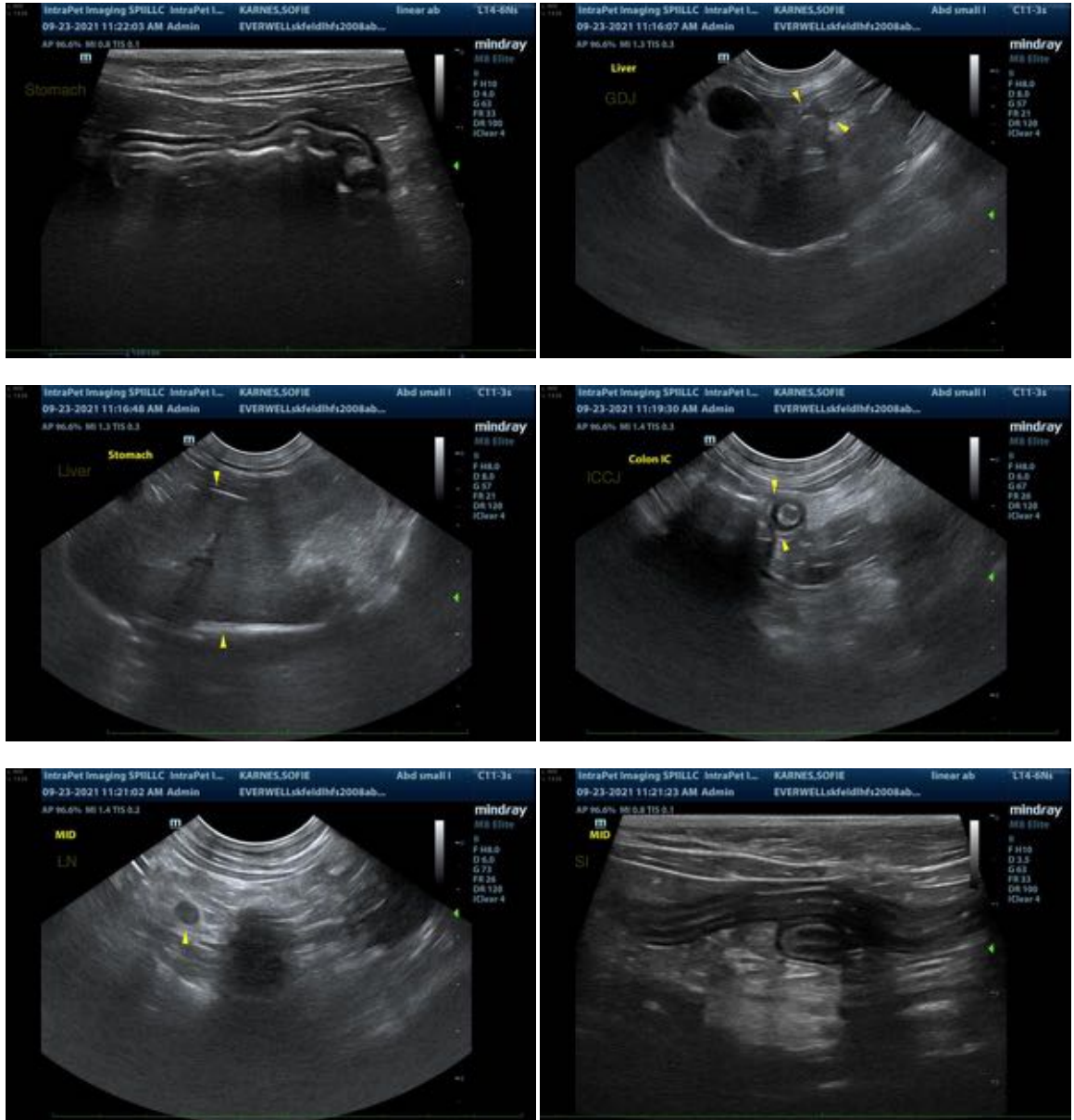
The following diagnostics can be considered:

1. Fine needle aspirate of the liver (if clotting status is appropriate). A 25-gauge needle should be used.
2. Serum cobalamin, folate, PLI and TLI
3. A fecal evaluation for ova/Giardia
4. Three-view thoracic radiographs to assess cardiopulmonary status.
5. Empirical treatment for pancreatitis/cholangiohepatitis/hepatic lipidosis is recommended. While awaiting test results, nutritional support is also strongly encouraged to help prevent/treat hepatic

lipidosis.

- Depending on the results of the above diagnostics/therapeutics, surgical gastrointestinal liver +/- pancreatic biopsies may be warranted.





The information and recommendations provided are based on the images presented by the referring veterinarian. No evaluation can be communicated regarding pathology that was not visible in the image/video clips provided.

Thank you for this referral. If the clinical or image interpretation does not parallel your findings or if I can be of any further assistance please contact me.

Andrea Nicastro, DVM, Diplomate ACVIM (*Small Animal Internal Medicine*)
 Andrea.nicastro@sonopath.com

