

**DATE PRESENTING CLINICAL SIGNS**

9.22.2022 Chronic vomiting, hours after eating.

PATIENT

D'artagnen Corbin

Current Medications: None.
 Lab Results: Pending.
 Date of Previous IntraPet Ultrasound: 4/18/22.
 Sedation: Not required to complete full diagnostic ultrasound.
 Stat Report: Not requested.
 Imaging Performed By: Rachel Brillhart, RDMS.

SPECIES

Feline

ULTRASONOGRAPHIC EXAMINATION OF THE ABDOMEN**BREED**

Ragdoll

Urinary System

The **urinary bladder** is normal in thickness and the mucosal surface is smooth. The bladder is mildly distended. A small amount of suspended, echogenic debris is observed within the lumen. No masses, inflammatory changes or calculi are observed. The region of the trigone and the visible portion of the proximal urethra are normal.

SEX

Neutered Male

The **left kidney** is normal size (4.41 cm in length); normal shape and architecture with smooth peripheral margins. There is a normal 1:3 cortex to medulla ratio with mild loss of corticomedullary distinction. There is no evidence of pyelectasia, nephroliths, infarcts or hydroureter. Renal vasculature is normal.

AGE

1/1/2011

The **right kidney** is normal size (4.71 cm in length); normal shape and architecture with smooth peripheral margins. There is a normal 1:3 cortex to medulla ratio with mild loss of corticomedullary distinction. There is no evidence of pyelectasia, nephroliths, infarcts or hydroureter. Renal vasculature is normal.

WEIGHT

15lbs

Adrenal Glands

The **left adrenal gland** is normal size (0.41 cm width). Normal shape and glandular echogenicity. The phrenicoabdominal vein and surrounding vasculature are normal.

INTERPRETED BY

Andrea Nicastro,
 DMV, Diplomate
 DACVIM (Small Animal
 Internal Medicine)

The **right adrenal gland** is normal size (0.37 cm width). Normal shape and glandular echogenicity. The phrenicoabdominal vein and surrounding vasculature are normal.

Spleen

The **spleen** is prominent in size (1.11 cm in width at the level of the hilus) with normal curvilinear peripheral contours. There is appropriate echogenicity and echotexture. No focal lesions are observed. Splenic vasculature is normal.

HOSPITAL NAME

Stay Pet Veterinary

Liver

The **liver** is subjectively normal in size with normal curvilinear peripheral contours. The parenchyma is isoechoic relative to the spleen and homogenous in appearance. No focal lesions are observed. Hepatic vasculature and intrahepatic biliary tracts are of normal volume with no evidence of congestion.

REFERRING VET

Dr. Klimovitz

The **gall bladder** lumen is moderately distended. The wall is thin and smooth. A scant amount of echogenic debris is observed within the lumen. The cystic and common bile ducts are normal/not seen.

INVOICE

11689

Gastrointestinal

The **stomach and intestine** are free of stasis and exhibit normal peristaltic activity. The gastric lumen is not distended. The gastric wall and pylorus are normal in thickness with a normal layering pattern. The pyloric outflow tract is patent. The small intestinal lumen is not dilated. The small intestinal wall thickness is normal with a normal layering pattern and appropriate mural detail. There is disruption in the normal 1:3 muscularis: mucosal ratio in most segments. Discreet masses are not identified. The ileocecal colic junction and colonic wall are normal. No obstructive disease is noted.

Pancreas

The **pancreas** is diffusely visible/prominent with minimal deviation from the normal peripheral contours. The parenchyma is slightly hypoechoic relative to surrounding omental fat. No distinct focal lesions are observed. The pancreatic duct is mildly dilated (0.27 cm in diameter).

Free Abdomen

There is no evidence of free fluid. The abdominal **lymph nodes** are normal/not visible.

ULTRASONOGRAPHIC FINDINGS

Primary Findings

- The small intestinal wall changes are consistent with inflammatory bowel disease. There is some potential for emerging lymphoma. However, neoplasia is considered unlikely at this time. Changes are similar to the previous sonogram.
- The pancreatic changes are suggestive of chronic pancreatitis (mild).

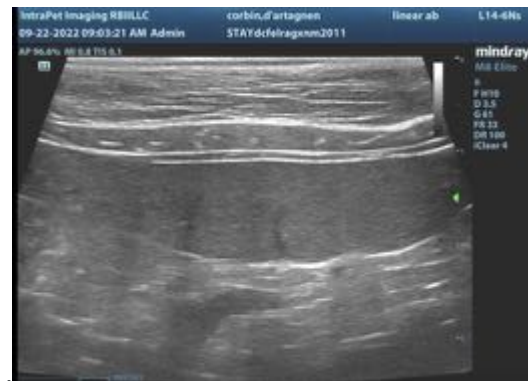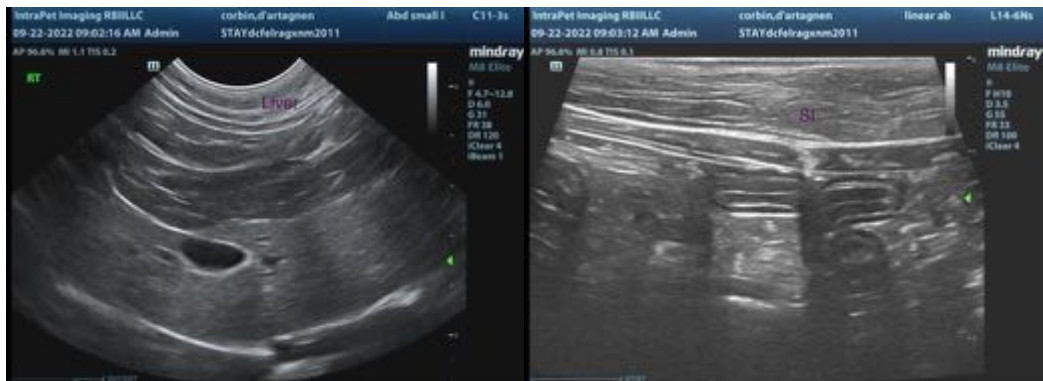
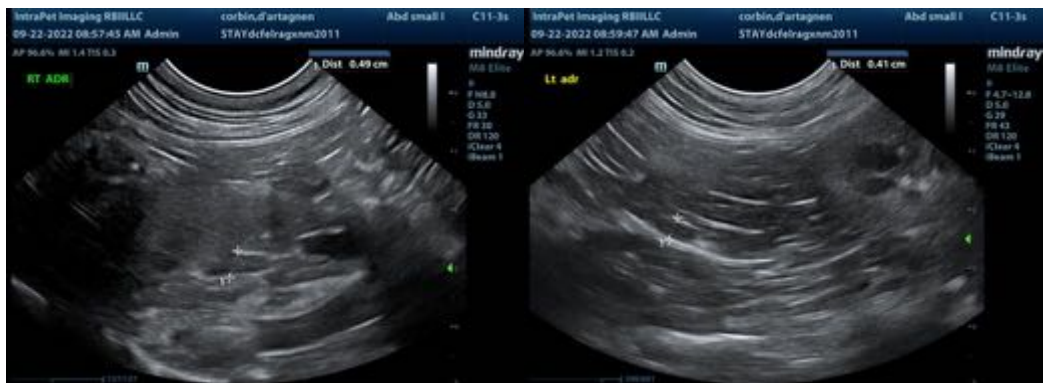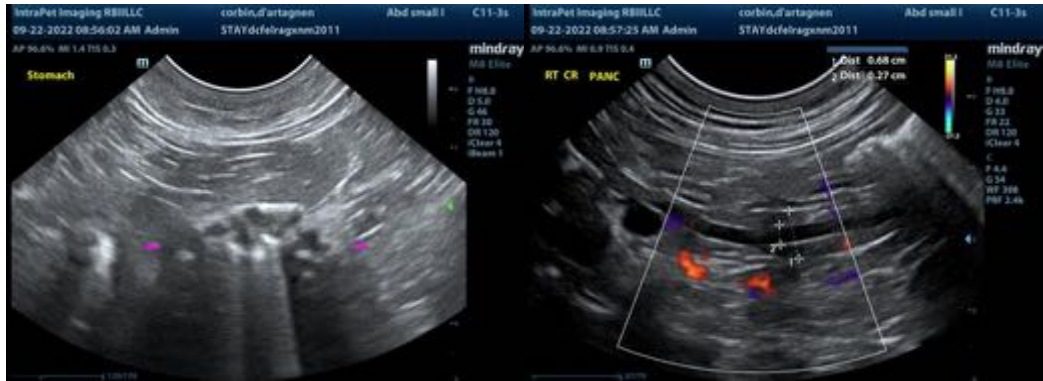
Secondary Findings

- The mild splenomegaly may be a normal variant for this large breed cat. Other differentials include lymphoid hyperplasia, extramedullary hematopoiesis, splenitis, antigenic stimulation, or less likely, infiltrative neoplasia.

INTERPRETATION OF THE FINDINGS & FURTHER RECOMMENDATIONS

The following diagnostic/treatment recommendations can be considered:

1. Serum cobalamin, folate, PLI and TLI
2. A fecal evaluation for ova/Giardia
3. A 6-week limited antigen diet trial to assess for food allergies
4. For patients where chronic vomiting is present but additional diagnostics are not to be performed, consider triple therapy as empirical treatment for Helicobacter gastritis:
 - a. Amoxicillin: 10-22 mg/kg PO q 12 hours x 14-21 days
 - b. Metronidazole: 10-15 mg/kg PO q 12 hours for 14-21 days
 - c. Omeprazole: 0.7 mg/kg PO q 24 hours for 14-21 days
 - d. (+/- the addition of Bismuth subsalicylate: 3.85 mg/kg PO q 6-8 hours x 14-21 days)
5. Also consider heartworm antigen and antibody testing as heartworm disease can be a cause of chronic vomiting in cats.
6. If the above diagnostics/therapeutics are inconclusive, endoscopic, or surgical gastrointestinal biopsies may be warranted. Three-view thoracic radiographs are recommended prior to any anesthetic event.



The information and recommendations provided are based on the images presented by the referring veterinarian/sonographer. No evaluation can be communicated regarding pathology that was not visible in the image/video clips provided.

Thank you for this referral. If the clinical or image interpretation does not parallel your findings or if I can be of any further assistance, please contact me.

Andrea Nicastro, MPH, DVM, Diplomate DACVIM (Small Animal Internal Medicine)
info@SonoPath.com