



PATIENT PRESENTING CLINICAL SIGNS

Lily Cruz

History: Patient presented 9/6/22 because she started being lethargic and being a picky eater with her dry diet on Saturday (9/4/22). She ate well wet diet on Sunday (9/5/22). She is drinking less amount of water and was feeling warm. She was taken to Banfield 9/5/22 where CBC revealed mild lymphopenia, chemistry revealed increased ALT 205 and globulin 5.7, and 3dx was negative. Patient was presented for recheck 9/20/22 after being hospitalized due to fever of unknown origin and elevated ALT. She is eating well and has good energy. She is on Denamarin SID. Patient finished course of lactulose (given due to not defecating for a few days) and doxycycline.

SPECIES

Feline

BREED

DSH

Abnormal PE/Chem/CBC/UA Results: Lab-work 9/20/22: CHEM: TP - 9.0 g/dL (5.7-8.9) GLOB - 5.7 g/dL (2.8-5.1) ALT - 646 U/L (12-130)

ULTRASONOGRAPHIC EXAMINATION OF THE ABDOMEN

SEX

Spayed Female

Urinary System

The **urinary bladder** wall is normal in thickness and the mucosal surface is smooth. The bladder lumen is moderately distended with anechoic urine. No masses, inflammatory changes or calculi are observed. The region of the trigone and the visible portion of the proximal urethra are normal.

AGE

8 years

The **left kidney** is normal size (4.29 cm in length); normal shape and architecture with smooth peripheral margins. There is a normal 1:3 cortex to medulla ratio with moderate loss of corticomedullary distinction. There is no evidence of pyelectasia, nephroliths, infarcts or hydroureter.

WEIGHT

16.8 lbs

The **right kidney** is normal size (4.09 cm in length); normal shape and architecture with smooth peripheral margins. There is a normal 1:3 cortex to medulla ratio with moderate loss of corticomedullary distinction. There is no evidence of pyelectasia, nephroliths, infarcts or hydroureter.

INTERPRETED BY

Andrea Nicastro,
DVM, Diplomate
ACVIM (*Small Animal
Internal Medicine*)

Adrenal Glands

The **left adrenal gland** is normal size (0.22 cm width). Normal shape and glandular echogenicity. The phrenicoabdominal vein and surrounding vasculature are normal.

The **right adrenal gland** is normal size (0.24 cm width). Normal shape and glandular echogenicity. The phrenicoabdominal vein and surrounding vasculature are normal.

IMAGING PERFORMED BY

Dr. G. Ferrer, DVM

Spleen

The **spleen** is normal in size (0.91 cm in width at the level of the hilus) with a normal capsular contour. There is appropriate echogenicity and echotexture. No focal lesions are observed. Splenic vasculature is normal.

HOSPITAL NAME

Paseos VC

Liver

The **liver** is subjectively normal in size with normal contours and structure. There is appropriate echogenicity and echotexture. No overt structural evidence of inflammatory, infiltrative, or regenerative pathology is evident. Vascular and biliary tracts are of normal volume with no evidence of congestion. No pathological hepatic lymphadenopathy observed.

REFERRING VET

Dra. Martes, DVM

The **gall bladder** lumen is moderately distended. The wall is thin and smooth. Luminal contents are anechoic. The cystic and common bile ducts are normal.

INVOICE

11669

Gastrointestinal

The **gastric lumen** is not distended. The gastric wall is normal in thickness with a normal layering pattern. The small intestinal lumen is not dilated. The small intestinal wall thickness is normal with a normal layering pattern and appropriate mural detail. Discreet masses are not identified. The ileoceocolic junction and colonic wall are normal. There is no evidence of an obstructive pattern.

DATE

9.21.22

Pancreas

The right limb is visualized with minimal deviation from the normal peripheral contours. The parenchyma is slightly hyperechoic relative to surrounding omental fat and mottled in appearance. No distinct focal lesions are observed. The pancreatic duct is not overtly dilated.

Free Abdomen

There is no evidence of free fluid. A 1.06 cm medial iliac **lymph node** is visualized. A few prominent colic lymph nodes are visualized, the largest measuring 0.97 cm in length. Surrounding mesentery is mildly hyperechoic.

ULTRASONOGRAPHIC FINDINGS

Primary Findings

- An obvious cause for the elevated liver enzymes is not identified in the study. However, a microscopic hepatopathy (i.e., bacterial cholangiohepatitis, lymphoplasmacytic hepatitis, hepatic lipidosis, reactive hepatopathy, infiltrative neoplasia (less likely)) cannot be excluded.
- An obvious cause for the patient's fever is also not identified in this study. Considerations include bacterial cholangiohepatitis, viral disease or other infection (i.e., bacterial, protozoal), inflammation or autoimmune disease.

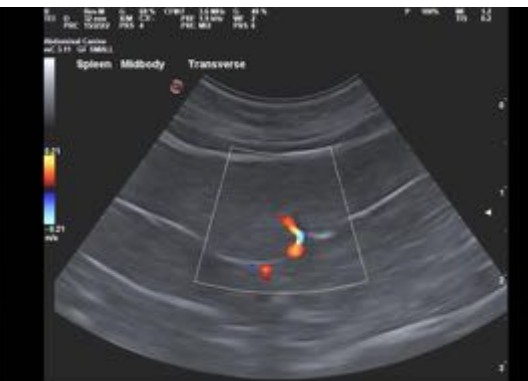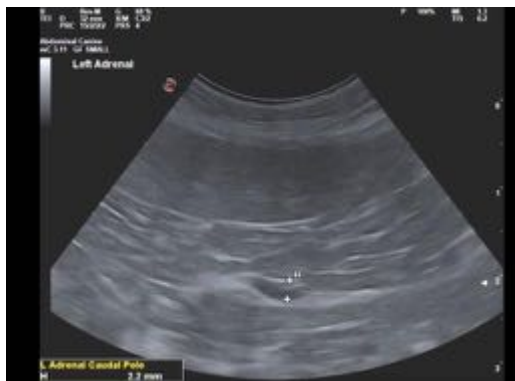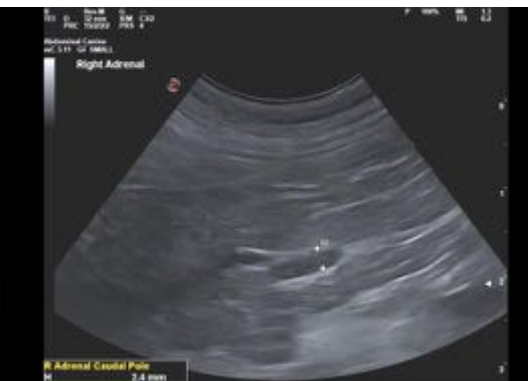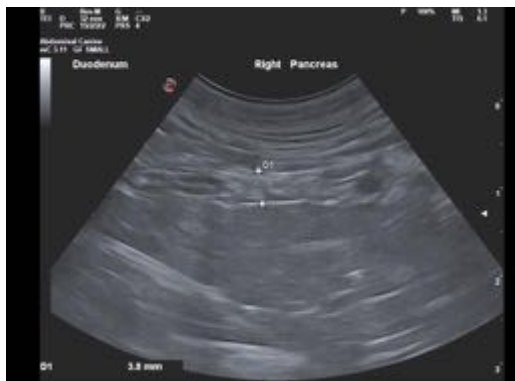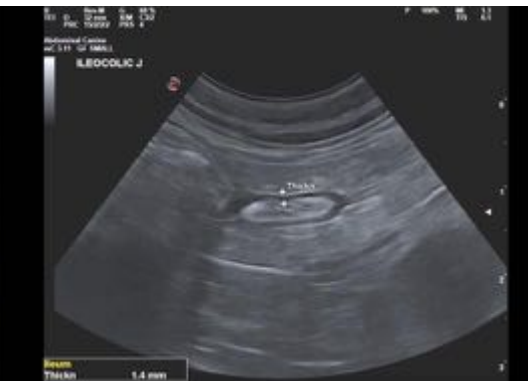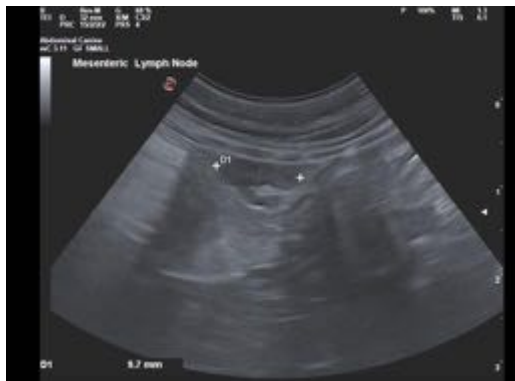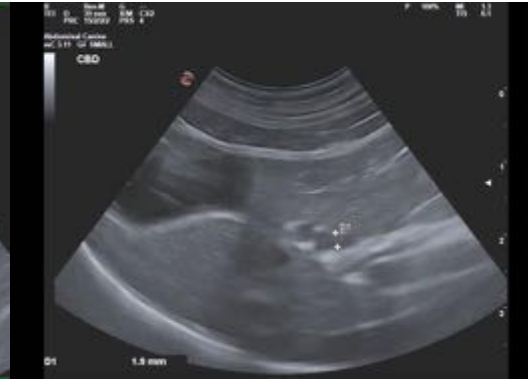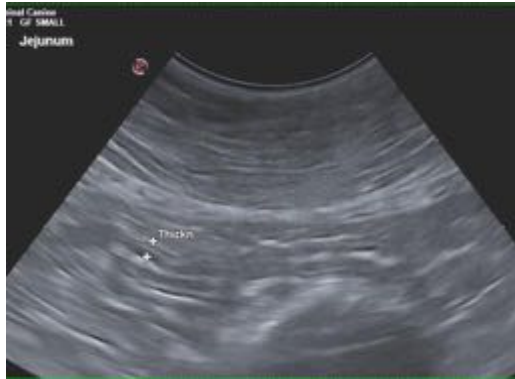Secondary Findings

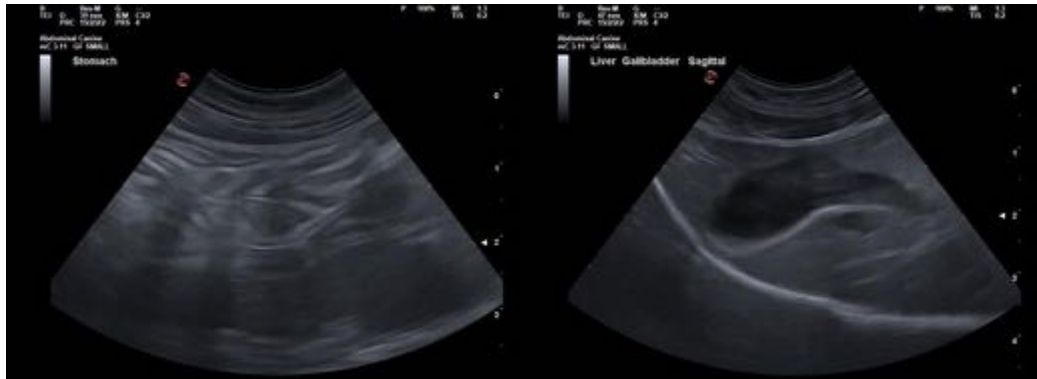
- Bilateral chronic age-related renal changes
- The pancreatic changes are most consistent with age-related remodeling/fibrosis. Mild, chronic, pancreatitis is also possible, particularly if the patient's clinical history is consistent with this diagnosis.
- The lymph node changes are most consistent with reactive lymphadenitis or lymphoid hyperplasia.

INTERPRETATION OF THE FINDINGS & FURTHER RECOMMENDATIONS

Further workup for fever of unknown origin could include the following:

- Fine needle aspirate of the liver (if clotting status is appropriate)
- Three-view thoracic radiographs to assess for occult disease/infection in the chest.
- Urine culture and sensitivity to evaluate for occult pyelonephritis.
- Testing for infectious diseases (i.e., feline leukemia, FIV, FIP, toxoplasmosis +/- vector-borne diseases)
- fPLI to assess for low-grade pancreatitis.
- Echocardiogram can also be considered to assess for endocarditis.
- While awaiting test results, broad-spectrum antibiotic therapy is recommended, along with symptomatic care.





The information and recommendations provided are based on the images presented by the referring veterinarian/sonographer. No evaluation can be communicated regarding pathology that was not visible in the image/video clips provided.

Thank you for this referral. If the clinical or image interpretation does not parallel your findings or if I can be of any further assistance, please contact me.

Andrea Nicastro, MPH, DVM, Diplomate DACVIM (Small Animal Internal Medicine)
info@SonoPath.com