

PATIENT

Kiara Vega

SPECIES

Canine

BREED

Shih Tzu

SEX

Spayed Female

AGE

12 years

WEIGHT

16 lbs

INTERPRETED BY

Andrea Nicastro,
DVM, Diplomate
ACVIM (*Small Animal
Internal Medicine*)

IMAGING PERFORMED BY

Dr. G. Ferrer DVM

HOSPITAL NAME

Paseos VC

REFERRING VET

Dra. Martes

INVOICE

11668

DATE

9.21.22

PRESENTING CLINICAL SIGNS

History: Patient was presented for evaluation of lethargy and hyporexia since 9-15-22. Patient does not have vomiting or diarrhea. Patient had mammary gland tumors removed at another clinic previously; owner reports they were benign.

Abnormal PE/Chem/CBC/UA Results: CBC - lymphopenia and eosinopenia Chemistry - hypoglobulinemia 4.8 fecal - negative Radiographs -(added here as supporting documents) multiple soft tissue opacities on thorax; left renomegaly; large soft tissue opacity dorsal to bladder; linear mineralized opacity/material seen at abdomen PE - cataract OU, mild hyperemia OD, mild calculus accumulation, firm swelling at left abdominal area (painful when palpated); firm lobulated subcutaneous mass at caudo-ventral abdomen

ULTRASONOGRAPHIC EXAMINATION OF THE ABDOMEN

Urinary System

The **urinary bladder** wall is normal in thickness and the mucosal surface is smooth. The bladder is moderately distended. A scant amount of echogenic debris is suspended within the lumen. No masses, inflammatory changes or calculi are observed. Ureteral papillae and visualized portion of the proximal urethra, visible to a depth of 1-2 cm, are normal.

The **left kidney** is enlarged (>8.00 cm) with an irregular shape. A >6.00 cm heterogenous mass effect is arising from the medial aspect. The mass causes disruption of the normal renal architecture. The mass has ill-defined cavitated areas. In the visible portion of the lateral cortex, there is mild loss of corticomedullary distinction. There is no evidence of pyelectasia, nephroliths, infarcts or hydroureter. Renal vasculature is normal. The mesentery effacing the serosal surface of the kidney is hyperechoic.

The **right kidney** is enlarged (>6.20 cm in length), with an irregular shape. A >3.60 cm heterogenous mass is arising from the cranial aspect. The lesion causes disruption of the normal renal architecture. In addition, at least two smaller hypoechoic nodules are observed at the caudolateral aspect. In the remainder of the kidney, there is moderate loss of corticomedullary distinction and trace pyelectasia. There is no evidence of hydroureter.

Adrenal Glands

The **left adrenal gland** is normal size (0.48 cm at cranial pole) (0.61 cm at caudal pole) (2.17 cm in length); with a normal shape and smooth peripheral contours. A 0.60 x 0.35 cm hypoechoic nodule is observed at the cranial pole. Glandular echogenicity and detail at the caudal pole are normal. The phrenicoabdominal vein and surrounding vasculature are normal.

The **right adrenal gland** is normal size (0.38 cm at cranial pole) (0.35 cm at caudal pole) (2.05 cm in length); normal shape; homogenous parenchyma. The glandular echogenicity and detail are unremarkable. Capsule, cortex, and medullary definition are normal. The phrenicoabdominal vein and surrounding vasculature are normal.

Spleen

The **spleen** is normal in size (1.36 cm in width at the level of the hilus) with a normal capsular contour. There is appropriate echogenicity and echotexture. No focal lesions are observed. Splenic vasculature is normal.

Liver

The **liver** is subjectively normal in size with normal curvilinear peripheral contours. The parenchyma is hypoechoic relative to the spleen and homogenous in appearance. There is an increase in portal markings. Hepatic vasculature and intrahepatic biliary tracts are of normal volume with no evidence of congestion.

The **gall bladder** is moderately distended. The wall is hyperechoic and normal in thickness. A small amount of aggregated, echogenic, partially dependent debris/sludge is observed within the lumen. The cystic and common bile ducts are normal/not seen.

Gastrointestinal

The **stomach and intestine** are free of stasis and exhibit normal peristaltic activity. The gastric lumen is not distended. The gastric wall and pylorus are normal in thickness with a normal layering pattern. The pyloric outflow tract is patent. The small intestinal lumen is not dilated. The small intestinal wall thickness is normal with a normal layering pattern and appropriate mural detail. Discreet masses are not identified. The colonic wall is normal. There is no evidence of an obstructive pattern.

Pancreas

A portion of the **pancreas** is obscured by the renomegaly. In the visualized portions, no obvious pathology is observed.

Free Abdomen

No obvious evidence free fluid. One to two severely enlarged, hypoechoic, cavitated **lymph nodes** are observed at the aortic trifurcation. Surrounding mesentery is hyperechoic.

ULTRASONOGRAPHIC FINDINGS

Primary Findings

- Bilateral renal masses. Metastatic disease neoplasia (i.e., adenocarcinoma, round cell tumor, sarcoma) is considered likely with a lower possibility of a benign inflammatory process.
- The enlarged caudal abdominal lymph nodes are also concerning for metastatic disease.
- Peritonitis/retroperitonitis is present, likely secondary to renal and lymph node pathology.

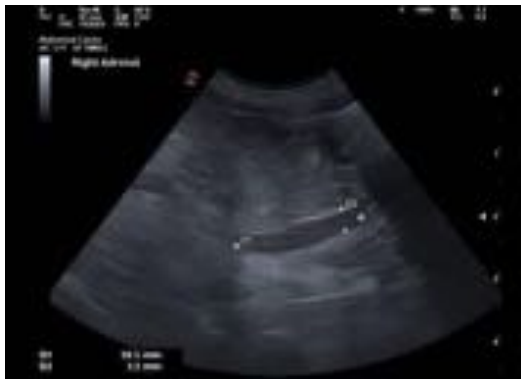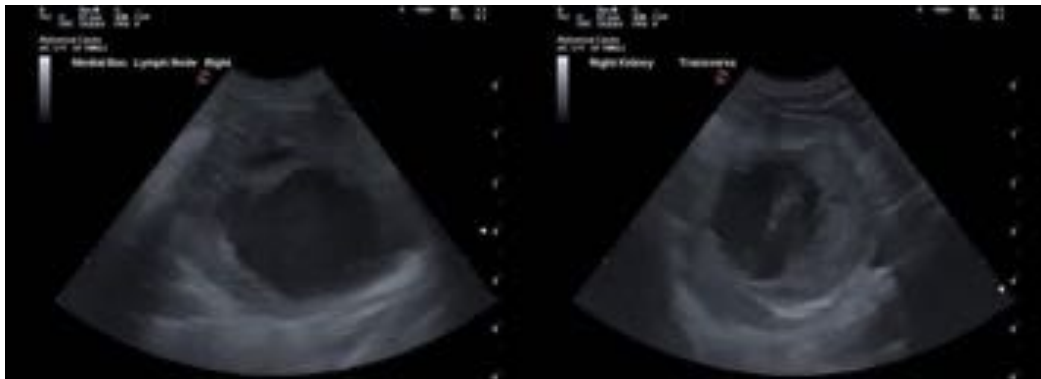
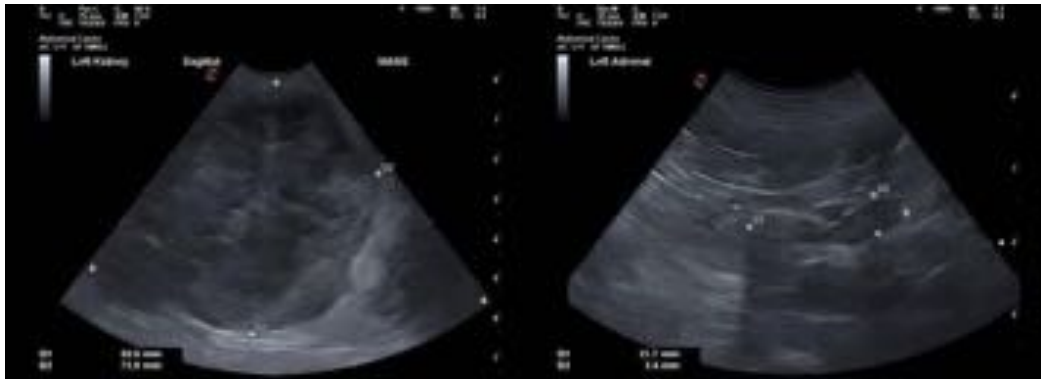
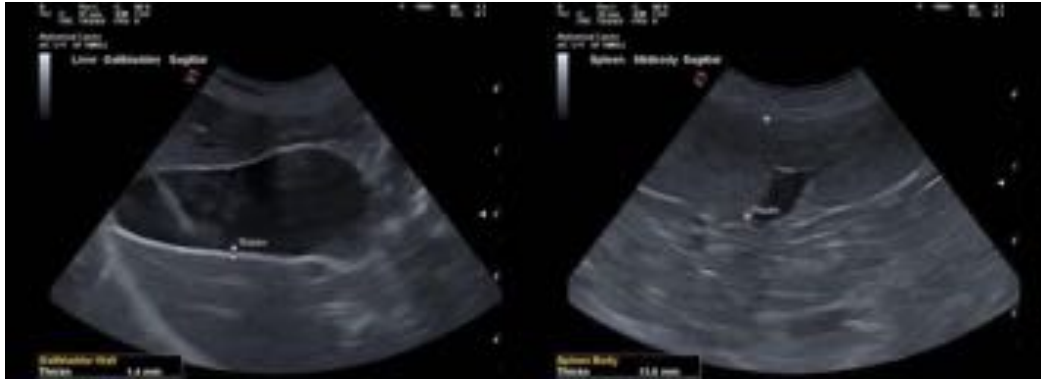Secondary Findings

- The left adrenal nodule trends toward the benign (i.e., benign nodular hyperplasia) with a lower possibility of an emerging tumor.
- The increase in hepatic portal markings may be secondary to an inflammatory process or may be a normal variant for this patient. Correlation with the patient's liver values is recommended.

INTERPRETATION OF THE FINDINGS & FURTHER RECOMMENDATIONS

Three-view thoracic radiographs are recommended to assess for pulmonary metastases.

Further diagnostics/treatments should be based on cytology results obtained at the end of this study. If cytology results are inconclusive, biopsies of the renal and lymph node masses may be necessary to get a definitive diagnosis.



The information and recommendations provided are based on the images presented by the referring veterinarian/sonographer. No evaluation can be communicated regarding pathology that was not visible in the image/video clips provided.

Thank you for this referral. If the clinical or image interpretation does not parallel your findings or if I can be of any further assistance, please contact me.

Andrea Nicastro, MPH, DVM, Diplomate DACVIM (Small Animal Internal Medicine)
info@SonoPath.com