

PATIENT

Alex Kneeld

SPECIES

Canine

BREED

Puggle

SEX

Neutered Male

AGE

11 years

WEIGHT

29.5 lbs

INTERPRETED BY

Andrea Nicastro,
DVM, Diplomate
ACVIM (*Small Animal
Internal Medicine*)

**IMAGING
PERFORMED BY**

Dr Lynette Reyes

HOSPITAL NAME

Chain of Lakes AC

REFERRING VET

Dr Lynette Reyes

INVOICE

11667

DATE

9.21.22

PRESENTING CLINICAL SIGNS

History: Per presented at the end of August for having urinary accidents and frequent urination at home. X-rays showed no uroliths, but possible stone seen on bladder scanning with ultrasound. Pet was started on U/D and treated with antibiotic since UA showed bacteria. After antibiotic treatment, accidents stopped but still urinating frequently. X-rays today showed an enlarged prostate and possible radiolucent urolith? Urine culture pending today

Abnormal PE/Chem/CBC/UA Results: SG: 1.033 UPC: 0.5 Prot: 2+ Occ blood: 3+ WBC: 11-20

ULTRASONOGRAPHIC EXAMINATION OF THE ABDOMEN

Urinary System

The **urinary bladder** is contracted. The wall is of appropriate thickness for the level of repletion. A 0.31 cm cystic calculus is observed. The region of the trigone and the visible portion of the proximal are normal.

The **prostate** is enlarged (2.03 cm in width) with a slightly irregular shape. The parenchyma is heterogenous with an ill-defined focus of mineralization. There appears to be an extension of prostatic tissue into the proximal urethra. The prostatic urethra is not overtly dilated.

The **left kidney** is normal in size (4.75 cm in length) with a normal shape, smooth peripheral margins, and normal internal architecture. There is mild loss of corticomedullary distinction. Several hyperechoic shadowing diverticular foci are observed. There is no evidence of pyelectasia, infarcts or hydronephrosis. Renal vasculature is normal.

The **right kidney** is normal in size (5.58 cm in length) with a normal shape, smooth peripheral margins, and normal internal architecture. There is mild loss of corticomedullary distinction. Several hyperechoic shadowing diverticular foci are observed. There is no evidence of pyelectasia, infarcts or hydronephrosis. Renal vasculature is normal.

Adrenal Glands

The **left adrenal gland** is normal size (0.48 cm at cranial pole) (0.51 cm at caudal pole); normal shape; homogenous parenchyma. The glandular echogenicity and detail are unremarkable. Capsule, cortex, and medullary definition are normal. The phrenicoabdominal vein and surrounding vasculature are normal.

The caudal pole of the **right adrenal gland** is well-visualized and is normal in size (0.51 cm in width); with a normal shape, glandular echogenicity and detail. Surrounding vasculature is normal.

Spleen

The **spleen** is subjectively normal in size (1.26 cm in width at the level of the hilus). The parenchyma is mostly homogenous in appearance. A 0.77 cm hypoechoic nodule is observed at the cranial aspect. The lesion causes slight capsular expansion. The remaining peripheral margins are curvilinear. Splenic vasculature is normal with no evidence of thrombosis.

Liver

The **liver** is subjectively prominent in size with swollen curvilinear peripheral contours. The parenchyma is isoechoic relative to the spleen and exhibits mild heterogeneity. No distinct focal lesions are observed. Hepatic vasculature and biliary tracts are of normal volume with no evidence of congestion. The portal vein to caudal vena cava ratio is approximately 1: 1.

The **gall bladder** lumen is moderately distended. The wall is thin and smooth. Luminal contents are anechoic. The cystic and common bile ducts are normal/not seen.

Gastrointestinal

The **stomach and intestine** are free of stasis and exhibit normal peristaltic activity. The gastric lumen is not distended. The gastric wall and pylorus are normal in thickness with a normal layering pattern. The pyloric outflow tract is patent. The small intestinal lumen is not dilated. The small intestinal wall thickness is normal with a normal layering pattern and appropriate mural detail. Discreet masses are not identified. The colonic wall is normal. There is no evidence of an obstructive pattern.

Pancreas

The region of the **pancreas** is isoechoic relative to surrounding omental fat. No obvious parenchymal abnormalities are observed. There is no evidence of regional inflammation or effusion.

Free Abdomen

There is no evidence of free fluid. The abdominal **lymph nodes** are normal/not visible.

ULTRASONOGRAPHIC FINDINGS

Primary Findings

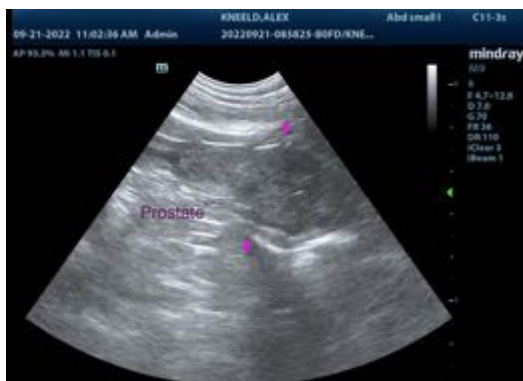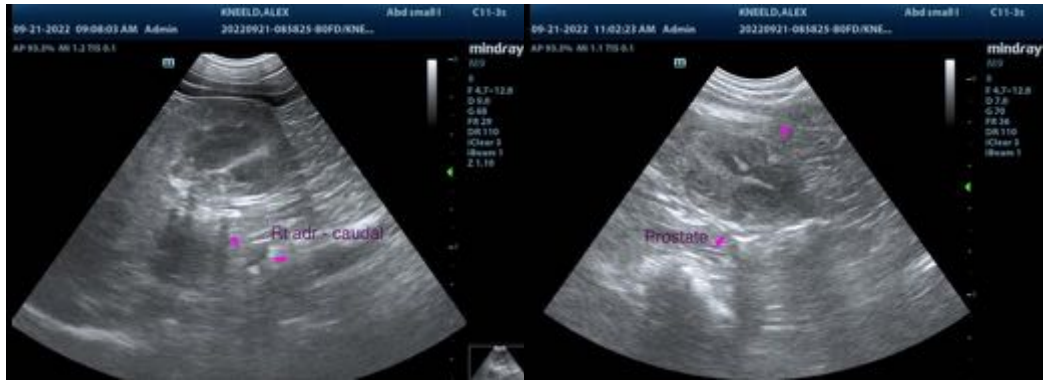
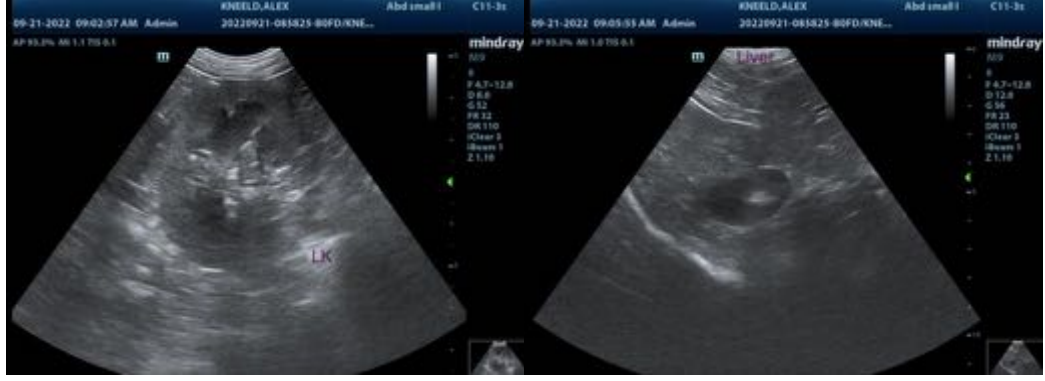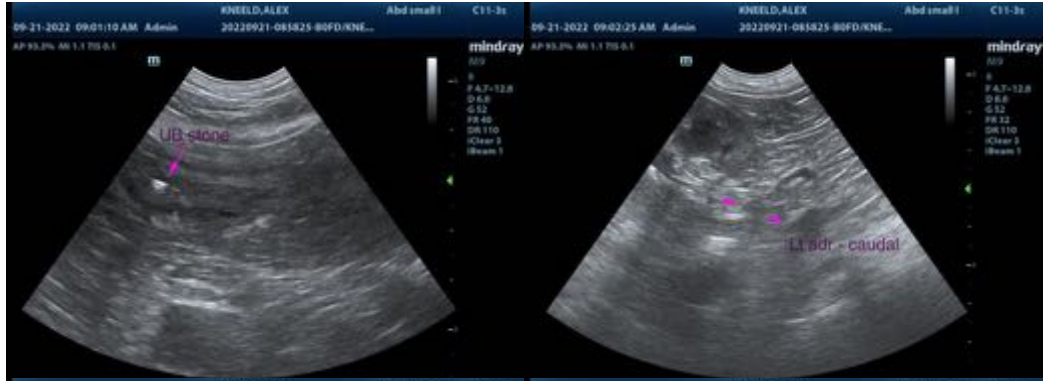
- The prostate changes are concerning for infiltrative neoplasia (i.e., adenocarcinoma, transitional cell carcinoma).
- Small cystic calculus
- The splenic nodule could be consistent with an emerging tumor. Alternatively, a focus of lymphoid hyperplasia, extramedullary hematopoiesis, other, is also possible.
- The diffuse hepatic changes are non-specific and could be consistent with vacuolar hepatopathy, regenerative nodular hyperplasia, and/or age-related remodeling. Inflammatory and infiltrative disease are considered less likely. Correlation with the patient's liver values is recommended.
- Minor, bilateral, age-related renal changes with subtle dystrophic mineralization

INTERPRETATION OF THE FINDINGS & FURTHER RECOMMENDATIONS

Three-view thoracic radiographs are recommended to assess for pulmonary metastases.

A urine BRAF test is recommended to further evaluate for lower urinary tract neoplasia. It should be noted however, that a negative BRAF test does not exclude the possibility of cancer. Therefore, if a negative result is obtained, further testing (i.e., traumatic urethra catheterization or surgical biopsy of the prostate) may be warranted.

Regarding the splenic nodule, consider an ultrasound-guided FNA.



The information and recommendations provided are based on the images presented by the referring veterinarian/sonographer. No evaluation can be communicated regarding pathology that was not visible in the image/video clips provided.

Thank you for this referral. If the clinical or image interpretation does not parallel your findings or if I can be of any further assistance, please contact me.

Andrea Nicastro, MPH, DVM, Diplomate DACVIM (Small Animal Internal Medicine)
info@SonoPath.com