

**DATE PRESENTING CLINICAL SIGNS**

9/21/2021

Acute onset anorexia x 24-36 hour, vomited foam 3 times in past 24 hours. No interest in food and laying around a lot. Usually, great appetite and a hooligan of energy.

**PATIENT**

Lolo Pagano

Radiographs: asymmetric gas pattern in SI, colon has formed stool, stomach has irregular gas shape centrally with undefined gastric walls.

Date of Previous IntraPet Ultrasound: No previous.

Sedation: Sedation not necessary.

Stat Report: Not indicated.

**SPECIES**

Feline

**BREED**

Domestic shorthair

**SEX**

Male, neutered

**AGE**

5/11/2021

**WEIGHT**

5.3 lbs.

**INTERPRETED BY**

Andrea Nicastro, DVM,  
 Diplomate ACVIM  
 (Small Animal Internal  
 Medicine)

**HOSPITAL NAME**

Stay Pet Veterinary

**REFERRING VET**

Dr. Klimovitz

**INVOICE**

12234

**ULTRASONOGRAPHIC EXAMINATION OF THE ABDOMEN****Urinary System**

The urinary bladder, trigone, and pelvic urethra are normal in thickness and the mucosal surface is smooth. The bladder lumen is moderately distended with anechoic urine. No masses, inflammatory changes or calculi are observed. Ureteral papillae and visualized portion of the proximal urethra, visible to a depth of 2 cm, are normal.

The left kidney is normal size (3.16 cm in length); normal shape and architecture with smooth peripheral margins. There is a normal 1:3 cortex to medulla ratio with normal corticomedullary distinction. There is no evidence of pyelectasia, nephroliths, infarcts or hydroureter.

The right kidney is normal size (3.58 cm in length); normal shape and architecture with smooth peripheral margins. There is a normal 1:3 cortex to medulla ratio with normal corticomedullary distinction. There is no evidence of pyelectasia, nephroliths, infarcts or hydroureter.

**Adrenal Glands**

The left adrenal gland is normal in size (xxx cm length; xxx cm width). Normal shape and glandular echogenicity. The phrenicoabdominal vein and surrounding vasculature are normal.

The right adrenal gland is normal in size (xxx cm length; xxx cm width). Normal shape and glandular echogenicity. The phrenicoabdominal vein and surrounding vasculature are normal.

**Spleen**

The spleen is normal in size (0.54 cm in width at the level of the hilus) with a normal capsular contour. There is appropriate echogenicity and echotexture. No focal lesions are observed. Splenic vasculature is normal.

**Liver**

The liver is subjectively normal in size with normal contours and structure. There is appropriate echogenicity and echotexture. No overt structural evidence of inflammatory, infiltrative or regenerative pathology is evident. Vascular and biliary tracts are of normal volume with no evidence of congestion. No pathological hepatic lymphadenopathy observed. The gall bladder lumen is moderately distended. The wall is thin and smooth. Luminal contents are anechoic. The cystic and common bile ducts are normal/not seen. The portal vein: caudal vena cava ratio is approximately 1:1.

**Gastrointestinal**

The gastric lumen is not distended. The gastric wall and pylorus are normal in thickness with a normal layering pattern. The pyloric outflow tract is patent. In a segment of jejunum, soft shadowing material is visualized within the lumen. Proximal to this region, the lumen is fluid distended and hypomotile. In the remaining small intestinal segments, the wall thickness is normal with a normal layering pattern and appropriate mural detail. In these segments, the lumen is not dilated. The ileocecal colic junction and colonic wall are normal.

### ***Pancreas***

The region of the pancreas is isoechoic relative to surrounding omental fat. No obvious parenchymal abnormalities are observed. There is no evidence of regional inflammation or effusion.

### ***Free Abdomen***

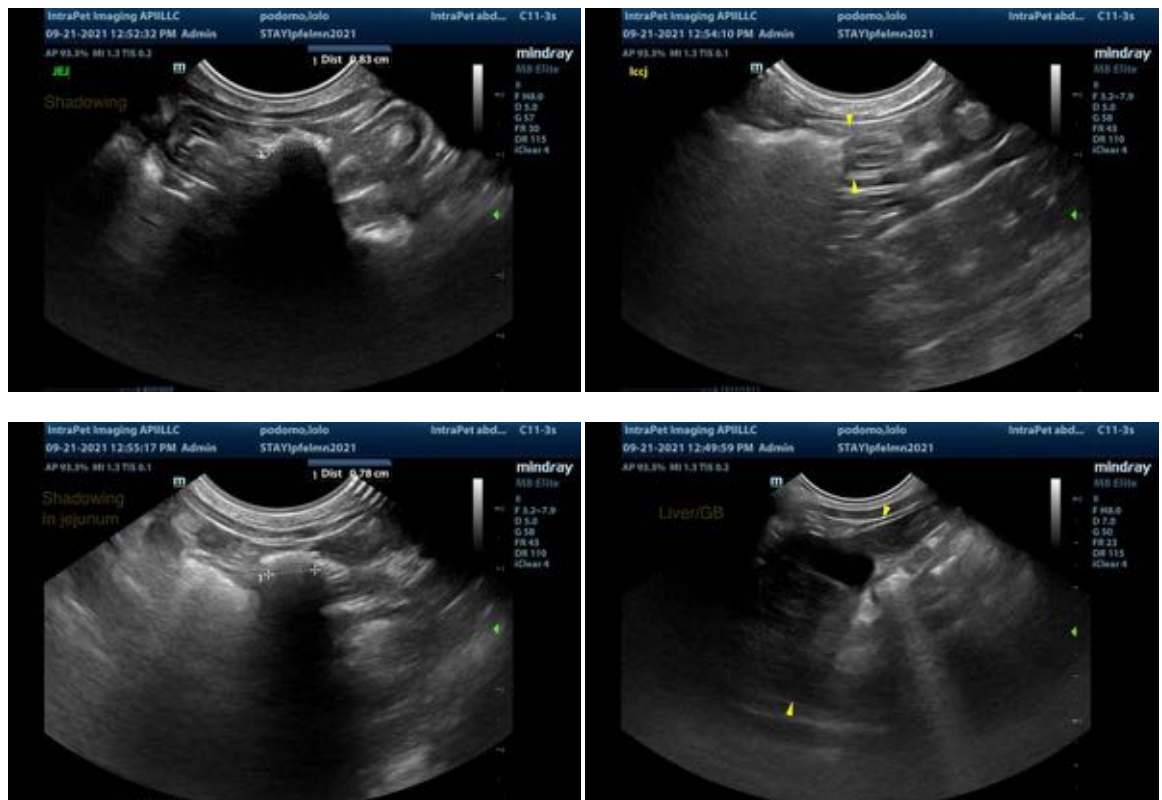
There is no evidence of free fluid. A few prominent mesenteric lymph nodes are visualized.

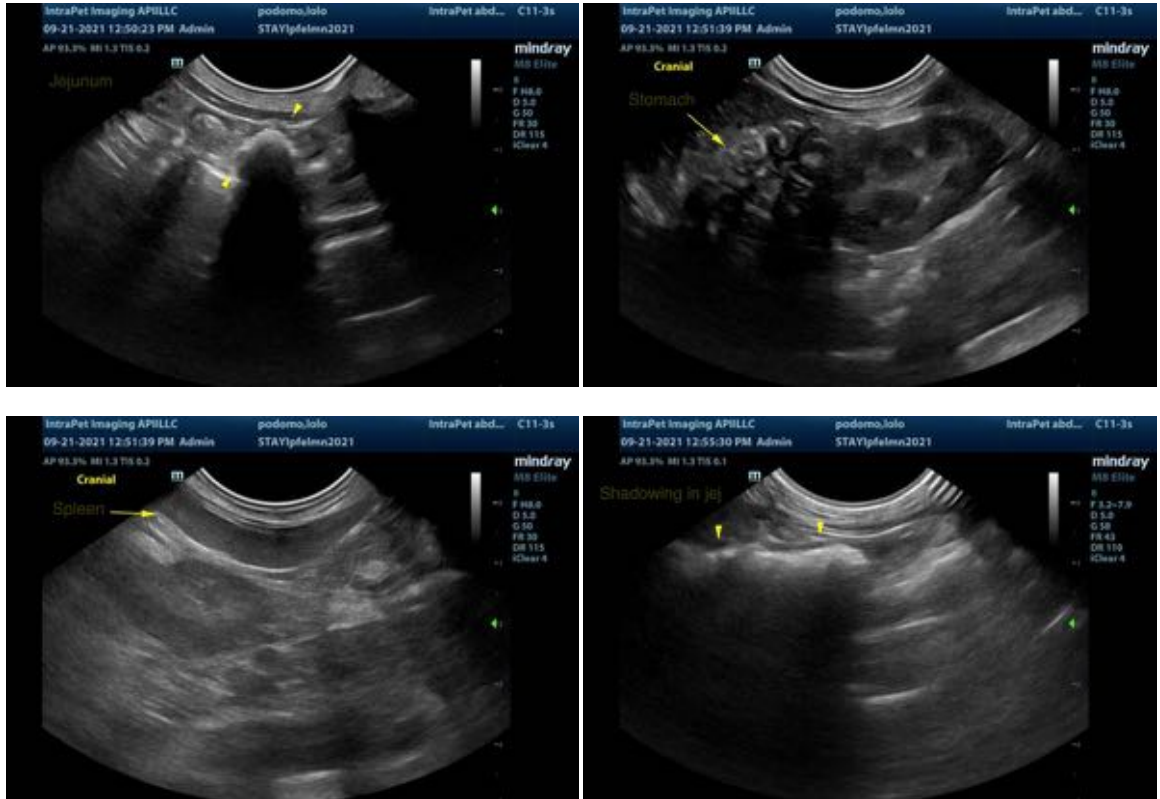
### **ULTRASONOGRAPHIC FINDINGS**

- Suspected jejunal foreign body/obstruction.
- The abdominal lymphadenopathy may be secondary to immunologic immaturity and/or reactive change.

### **INTERPRETATION OF THE FINDINGS & FURTHER RECOMMENDATIONS**

- Three-view thoracic radiographs are recommended to assess for aspiration pneumonia.
- An abdominal exploratory is recommended to assess for/remove the small intestinal foreign body.





The information and recommendations provided are based on the images presented by the referring veterinarian. No evaluation can be communicated regarding pathology that was not visible in the image/video clips provided.

Thank you for this referral. If the clinical or image interpretation does not parallel your findings or if I can be of any further assistance please contact me.

Andrea Nicastro, DVM, Diplomate ACVIM (*Small Animal Internal Medicine*)  
Andrea.nicastro@sonopath.com