



PATIENT

Blu Humphrey

SPECIES

Canine

BREED

Rottweiler

SEX

Male, intact

AGE

9 Months

WEIGHT

100.1 lbs.

INTERPRETED BY

Andrea Nicastro, DVM,
Diplomate ACVIM
(*Small Animal Internal
Medicine*)

**IMAGING
PERFORMED BY**

Dr. Harold Mike Beard

HOSPITAL NAME

Animal Care VC

REFERRING VET

Dr. Harold Mike Beard

INVOICE

13992

DATE

9/20/22

PRESENTING CLINICAL SIGNS

History: Weight loss, urinates a lot, diarrhea (chronic). Has had giardia in the past.
Abnormal PE/Chem/CBC/UA Results: CBC = increase WBC, eosinophilia, lymphocytosis, basophilia.
Chemistry = increased phosphorus (8.8), increased amylase (1624). UA = dilute urine, hematuria, white cells in urine.

ULTRASONOGRAPHIC EXAMINATION OF THE ABDOMEN

Urinary System

The urinary bladder wall is normal in thickness and the mucosal surface is smooth. The bladder lumen is distended. A small amount of suspended echogenic debris is observed within the lumen. No masses, inflammatory changes or calculi are observed. The region of the trigone is normal.

The prostate is not definitively visualized due to its pelvic location.

The left kidney is normal size (9.36 cm in length); normal shape and architecture with smooth peripheral margins. There is a normal 1:3 cortex to medulla ratio with normal corticomedullary distinction. There is no evidence of pyelectasia, nephroliths, infarcts or hydroureter.

The right kidney is normal size (8.58 cm in length); normal shape and architecture with smooth peripheral margins. There is a normal 1:3 cortex to medulla ratio with normal corticomedullary distinction. There is no evidence of pyelectasia, nephroliths, infarcts or hydroureter.

Adrenal Glands

The region of the adrenal glands is evaluated. No obvious pathology is observed.

Spleen

The spleen is normal in size (2.03 cm in width at the level of the hilus) with a normal capsular contour. The parenchyma is subtly mottled in appearance. No focal lesions are observed. Splenic vasculature is normal.

Liver

The liver is subjectively normal in size with normal contours and structure. There is appropriate echogenicity and echotexture. No overt structural evidence of inflammatory, infiltrative or regenerative pathology is evident. Vascular and biliary tracts are of normal volume with no evidence of congestion. No pathological hepatic lymphadenopathy observed. The gall bladder lumen is moderately distended. The wall is thin and smooth. Luminal contents are anechoic. The cystic and common bile ducts are normal/not seen.

Gastrointestinal

The gastric lumen is mildly distended with ingesta. The gastric wall is normal in thickness with a normal layering pattern. The small intestinal lumen is segmentally dilated with gas and chyme (mild). The small intestinal wall thickness is normal with a normal layering pattern and appropriate mural detail. Discreet masses are not identified. The colonic wall is normal. The colonic lumen contains granular appearing fecal material. No obstructive disease is noted.

Pancreas



PATIENT

Blu Humphrey

The region of the pancreas is isoechoic relative to surrounding omental fat. No obvious parenchymal abnormalities are observed. There is no evidence of regional inflammation or effusion.

SPECIES

Canine

Free Abdomen

The peritoneal cavity is normal. There is no evidence of inflammation or effusion. The abdominal lymph nodes are normal/not visible.

BREED

Rottweiler

ULTRASONOGRAPHIC FINDINGS

SEX

Male, intact

- The splenic parenchymal changes are most consistent with a benign process such as lymphoid hyperplasia, extramedullary hematopoiesis, splenitis or antigenic stimulation with a low possibility of infiltrative neoplasia (i.e., lymphoma, mast cell neoplasia).

*An obvious cause for the patient's clinical signs is not identified in this study.

AGE

9 Months

INTERPRETATION OF THE FINDINGS & FURTHER RECOMMENDATIONS

WEIGHT

100.1 lbs.

- Regarding the urinary tract signs, a urine culture and sensitivity is recommended.
- Regarding the gastrointestinal signs, consider the following:
 - A fecal evaluation for ova/Giardia, if not already performed. Prophylactic deworming with Fenbendazole is also recommended.
 - Supplementation with a probiotic with a high colony count (i.e., Provable Forte or Visbiome).
 - Also consider fiber supplementation (i.e., Metamucil or Konsyl).
 - Malabsorption panel including serum cobalamin, folate, TLI and PLI (send to Texas A&M).
 - Consider a resting cortisol level to screen for hypoadrenocorticism.
 - Consider a 6-week hydrolyzed protein or limited antigen diet trial.
 - Depending on the results of the above diagnostics, GI biopsies (i.e., endoscopic or surgical) may be necessary to get a definitive diagnosis.

INTERPRETED BY

Andrea Nicastro, DVM,
Diplomate ACVIM
(Small Animal Internal
Medicine)

IMAGING PERFORMED BY

Dr. Harold Mike Beard

HOSPITAL NAME

Animal Care VC

REFERRING VET

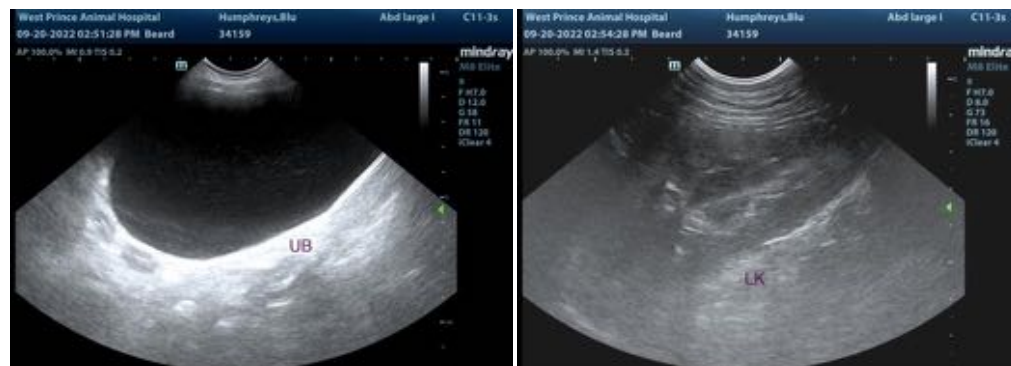Dr. Harold Mike Beard

INVOICE

13992

DATE

9/20/22





PATIENT

Blu Humphrey

SPECIES

Canine

BREED

Rottweiler

SEX

Male, intact

AGE

9 Months

WEIGHT

100.1 lbs.

INTERPRETED BY

Andrea Nicastro, DVM,
Diplomate ACVIM
(Small Animal Internal
Medicine)

IMAGING PERFORMED BY

Dr. Harold Mike Beard

HOSPITAL NAME

Animal Care VC

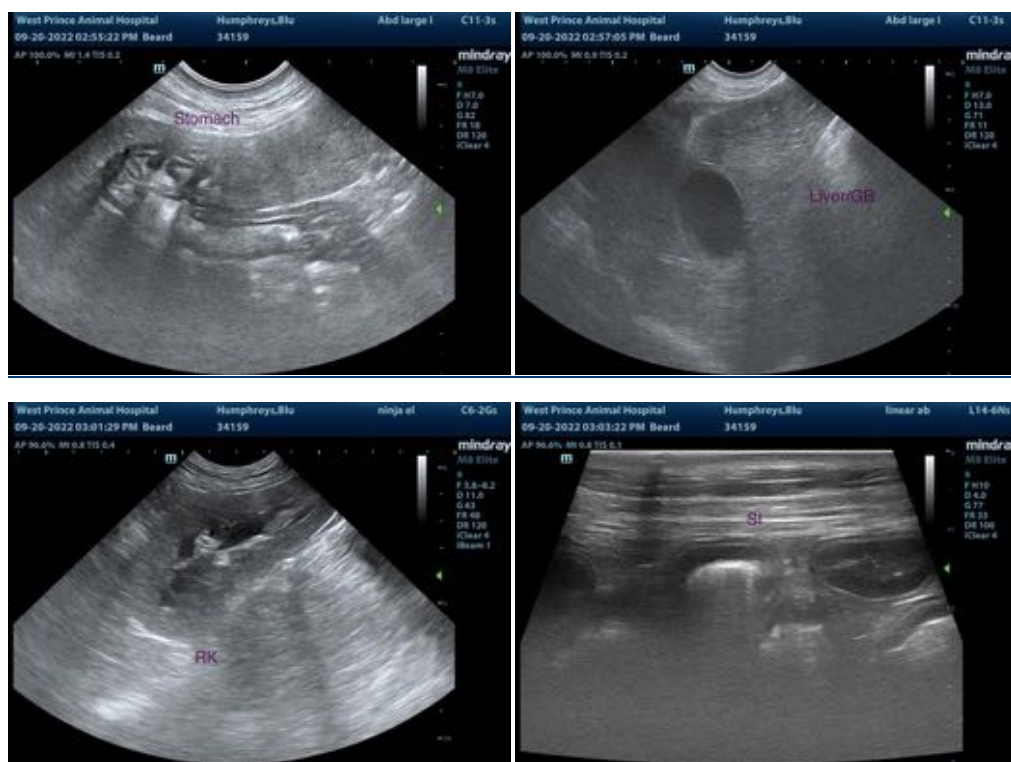
REFERRING VET

Dr. Harold Mike Beard

INVOICE

13992

DATE
9/20/22



The information and recommendations provided are based on the images presented by the referring veterinarian/sonographer. No evaluation can be communicated regarding pathology that was not visible in the image/video clips provided.

Thank you for this referral. If the clinical or image interpretation does not parallel your findings or if I can be of any further assistance please contact me.

Andrea Nicastro, MPH, DVM, Diplomate DACVIM (Small Animal Internal Medicine)
info@SonoPath.com