



**PATIENT**

Rosie Kalman

**PRESENTING CLINICAL SIGNS**

History: History of mast cell on caudal abdomen near mid-line, grade 2.

Abnormal PE/Chem/CBC/UA Results: CBC/Chem: WNL. Chest radiographs are unremarkable.

**SPECIES**

Canine

**ULTRASONOGRAPHIC EXAMINATION OF THE ABDOMEN**

*Urinary System*

**BREED**

Labrador

The urinary bladder, trigone, and pelvic urethra are normal in thickness and the mucosal surface is smooth. The bladder lumen is moderately distended with anechoic urine. No masses, inflammatory changes or calculi are observed. Ureteral papillae and visualized portion of the proximal urethra, visible to a depth of 2 cm, are normal.

**SEX**

Female Spayed

The left kidney is normal size (5.97 cm in length); normal shape and architecture with smooth peripheral margins. There is a normal 1:3 cortex to medulla ratio with normal corticomedullary distinction. There is no evidence of pyelectasia, nephroliths, infarcts or hydroureter. Renal vasculature is normal.

**AGE**

7 years

The right kidney is normal size (4.76 cm in length); normal shape and architecture with smooth peripheral margins. There is a normal 1:3 cortex to medulla ratio with normal corticomedullary distinction. There is no evidence of pyelectasia, nephroliths, infarcts or hydroureter. Renal vasculature is normal.

**WEIGHT**

67 lbs.

*Adrenal Glands*

The left adrenal gland is normal size (0.55 cm at cranial pole) (0.47 cm at caudal pole) (2.27 cm in length); normal shape; homogenous parenchyma. The glandular echogenicity and detail are unremarkable. Capsule, cortex, and medullary definition are normal. The phrenicoabdominal vein and surrounding vasculature are normal.

**INTERPRETED BY**

Andrea Nicastro, DVM,  
Diplomate ACVIM  
(*Small Animal Internal  
Medicine*)

The caudal pole of the right adrenal gland is visualized and is normal size (0.67 cm in width) with a normal shape, glandular echogenicity, and detail. The phrenicoabdominal vein and surrounding vasculature are normal.

**IMAGING PERFORMED BY**

Kelly Vazquez, CVT

*Spleen*

The spleen is normal in size (1.43 cm in width at the level of the hilus) with a normal capsular contour. The parenchyma is subtly mottled in appearance. At least one small hypoechoic nodule is observed. Splenic vasculature is normal.

**HOSPITAL NAME**

Veterinary Wellness  
Center

*Liver*

The liver is subjectively normal in size with normal curvilinear peripheral contours. The parenchyma is hypoechoic relative to the spleen with minor changes consistent with age-related remodeling. No focal lesions are observed. Hepatic vasculature and biliary tracts are of normal volume with no evidence of congestion. The gall bladder lumen is moderately distended. The wall is thin and smooth. Luminal contents are anechoic. The cystic and common bile ducts are normal/not seen.

**REFERRING VET**

Dr. Sepulveda

*Gastrointestinal*

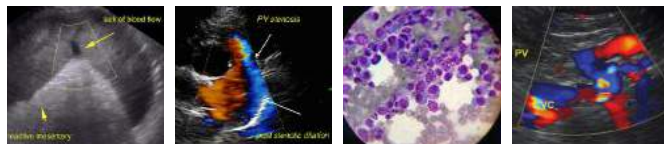
**INVOICE**

11847kk

The gastric lumen is mildly to moderately distended with ingesta. The gastric wall is normal in thickness with a normal layering pattern. The small intestinal lumen is segmentally dilated with chyme. The small intestinal wall thickness is normal with a normal layering pattern and appropriate mural detail. Discreet masses are not identified. The colonic wall is normal. No obstructive disease is noted.

**DATE**

9/17/21



**PATIENT**

***Pancreas***

Rosie Kalman

The region of the pancreas is isoechoic relative to surrounding omental fat. No obvious parenchymal abnormalities are observed. There is no evidence of regional inflammation or effusion.

**SPECIES**

***Free Abdomen***

Canine

The peritoneal cavity is normal. There is no evidence of inflammation or effusion. The abdominal lymph nodes are normal/not visible.

**BREED**

Labrador

**ULTRASONOGRAPHIC FINDINGS**

**SEX**

Female Spayed

- The splenic parenchyma changes are most consistent with a benign process such as lymphoid hyperplasia, extramedullary hematopoiesis or splenitis with a low possibility of infiltrative neoplasia (i.e., lymphoma, mast cell neoplasia).
- The hepatic parenchymal changes are most consistent with age-related remodeling. However, microscopic metastatic disease cannot be completely excluded.

**AGE**

7 years

**INTERPRETATION OF THE FINDINGS & FURTHER RECOMMENDATIONS**

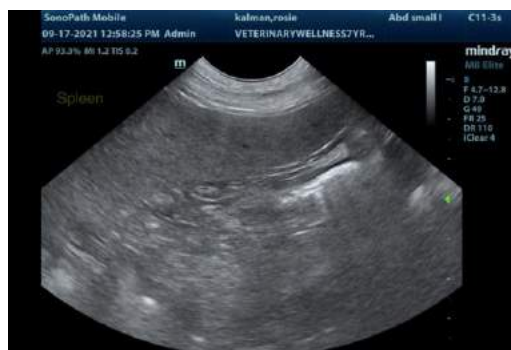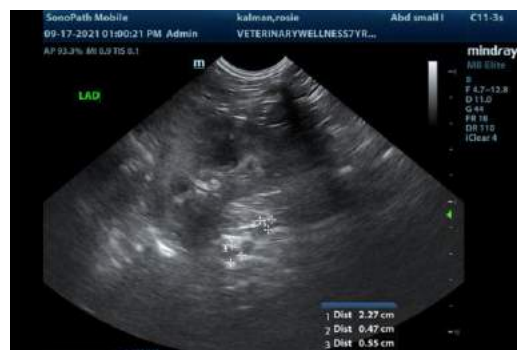**WEIGHT**

67 lbs.

1. To assess for mast cell disease in the spleen and liver, consider fine needle aspirates if the patient's clotting status is normal. Diphenhydramine should be administered at 2.2 mg/kg subcutaneously 15 minutes prior to aspiration to reduce the risk of mast cell degranulation.
2. Baseline lab work including a CBC chemistry panel, urinalysis and T4 is recommended to assess metabolic function if not already performed.

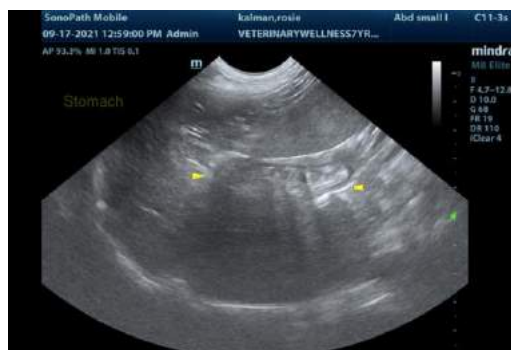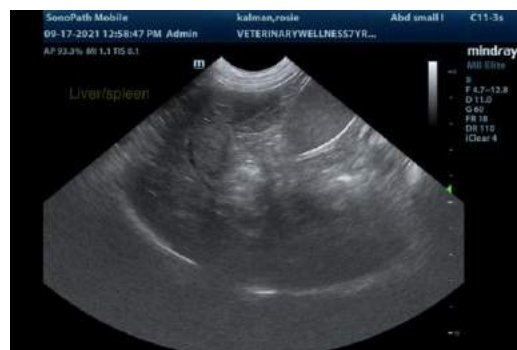**INTERPRETED BY**

Andrea Nicastro, DVM,  
Diplomate ACVIM  
(Small Animal Internal  
Medicine)



**IMAGING PERFORMED BY**

Kelly Vazquez, CVT



**HOSPITAL NAME**

Veterinary Wellness  
Center

**REFERRING VET**

Dr. Sepulveda

**INVOICE**  
11847kk

**DATE**  
9/17/21



## PATIENT

Rosie Kalman

## SPECIES

Canine

## BREED

Labrador

## SEX

Female Spayed

## AGE

7 years

## WEIGHT

67 lbs.

## INTERPRETED BY

Andrea Nicastro, DVM,  
Diplomate ACVIM  
(*Small Animal Internal  
Medicine*)

## IMAGING PERFORMED BY

Kelly Vazquez, CVT

## HOSPITAL NAME

Veterinary Wellness  
Center

## REFERRING VET

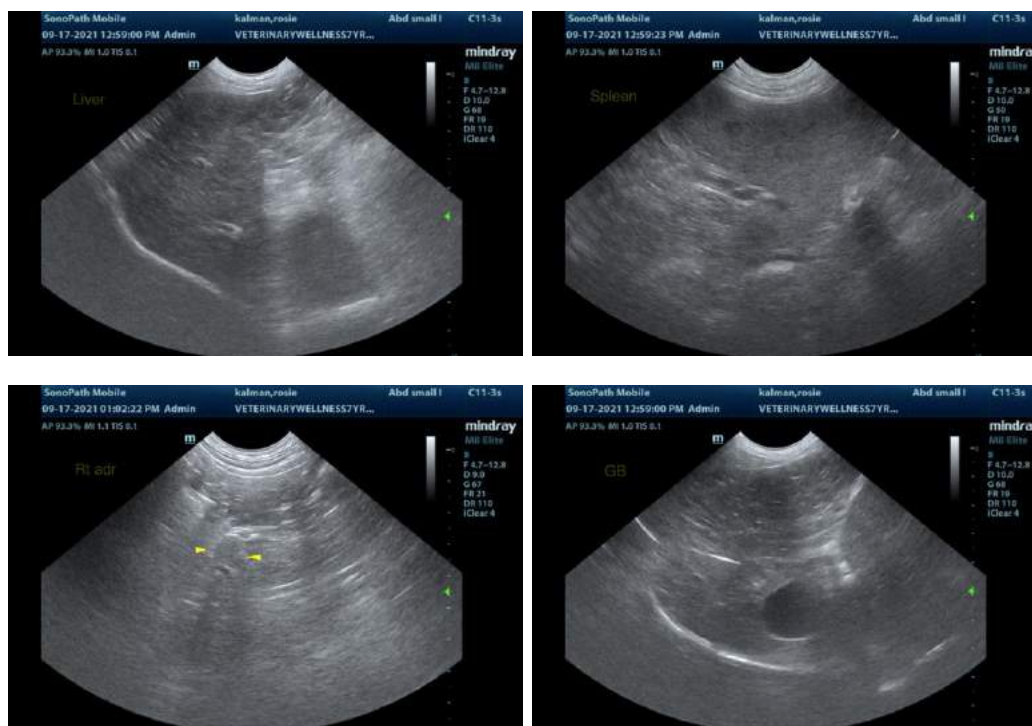
Dr. Sepulveda

## INVOICE

11847kk

## DATE

9/17/21



The information and recommendations provided are based on the images presented by the referring veterinarian. No evaluation can be communicated regarding pathology that was not visible in the image/video clips provided.

Thank you for this referral. If the clinical or image interpretation does not parallel your findings or if I can be of any further assistance, please contact me.

Andrea Nicastro, DVM, Diplomate ACVIM (*Small Animal Internal Medicine*)  
Andrea.nicastro@sonopath.com