



PATIENT

Berkely Asselin

SPECIES

Canine

BREED

Boxer

SEX

Female Spayed

AGE

11 Years 2 Months

WEIGHT

60.7 lbs.

INTERPRETED BY

Andrea Nicastro, DVM,
Diplomate ACVIM
(Small Animal Internal
Medicine)

IMAGING PERFORMED BY

Potomac Mobile
Veterinary Ultrasound

HOSPITAL NAME

Banfield Leesburg

REFERRING VET

Dr. Jarrett

INVOICE

11848kk

DATE

9/17/21

PRESENTING CLINICAL SIGNS

History: Elevation in liver enzymes in the past. Previously suspected to have gall bladder disease and was put on Actigall and did well. Currently acting a bit lethargic/seems a bit off. Leaking urine some. The patient is also having an echocardiogram performed.

Abnormal PE/Chem/CBC/UA Results: ALT 338, ALP 523, GGT 152, WBC 5.76 Lymp 0.53.

ULTRASONOGRAPHIC EXAMINATION OF THE ABDOMEN

Urinary System

The urinary bladder, trigone, and pelvic urethra are normal in thickness and the mucosal surface is smooth. The bladder lumen is moderately distended with anechoic urine. No masses, inflammatory changes or calculi are observed. Ureteral papillae and visualized portion of the proximal urethra, visible to a depth of 2 cm, are normal.

The prostate is not definitively visualized due to its pelvic location.

The left kidney is normal size (6.33 cm in length); normal shape and architecture with smooth peripheral margins. There is a normal 1:3 cortex to medulla ratio with minimal loss of corticomedullary distinction. There is no evidence of pyelectasia, nephroliths, infarcts or hydronephrosis. Renal vasculature is normal.

The right kidney is normal size (6.24 cm in length); normal shape and architecture with smooth peripheral margins. There is a normal 1:3 cortex to medulla ratio with normal corticomedullary distinction. There is no evidence of pyelectasia, nephroliths, infarcts or hydronephrosis. Renal vasculature is normal.

Adrenal Glands

The left adrenal gland is normal size (0.46 cm at cranial pole) (0.63 cm at caudal pole) (2.18 cm in length); normal shape; homogenous parenchyma. The glandular echogenicity and detail are unremarkable. Capsule, cortex, and medullary definition are normal. The phrenicoabdominal vein and surrounding vasculature are normal.

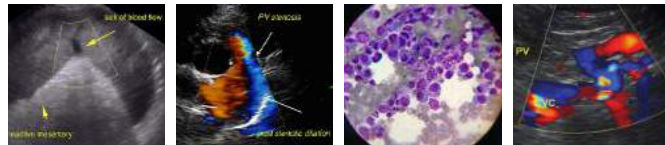
The right adrenal gland is normal size (0.54 cm at cranial pole) (0.59 cm at caudal pole) (2.74 cm in length); normal shape; homogenous parenchyma. The glandular echogenicity and detail are unremarkable. Capsule, cortex, and medullary definition are normal. The phrenicoabdominal vein and surrounding vasculature are normal.

Spleen

The spleen is normal in size (1.50 cm in width at the level of the hilus) with a normal capsular contour. There is appropriate echogenicity and echotexture. No focal lesions are observed. Splenic vasculature is normal.

Liver

The liver is subjectively normal in size with normal curvilinear peripheral contours. The parenchyma is hypochoic relative to the spleen and subtly mottled in appearance. No distinct focal lesions are observed. Hepatic vasculature and intrahepatic biliary tracts are of normal volume with no evidence of congestion. The gall bladder is of normal contours and contains some dependent echogenic debris. The wall is normal in thickness. No choleliths are observed. The cystic and common bile ducts are



PATIENT normal/not seen.

Berkely Asselin

Gastrointestinal

SPECIES

Canine

The gastric lumen is moderately gas-distended. In the region of the pyloric antrum, within the lesser curvature, a focal area of thickening (up to 1.14 cm) spanning approximately 3 ½ cm is visualized. Within this region there is apparent loss of the normal layering pattern. The serosal surface also appears disrupted. The remaining gastric wall is normal in thickness with a normal layering pattern. The small intestinal lumen is segmentally distended with gas and chyme. A small amount of shadowing material is observed within one segment of jejunal lumen. However, there is no overt dilation in this region. The small intestinal wall thickness is normal with a normal layering pattern and appropriate mural detail. The colonic wall is normal. There is no evidence of an obstructive pattern.

BREED

Boxer

Pancreas

SEX

Female Spayed

The region of the pancreas is isoechoic relative to surrounding omental fat. No obvious parenchymal abnormalities are observed. There is no evidence of regional inflammation or effusion.

AGE

11 Years 2 Months

Free Abdomen

The peritoneal cavity is normal. There is no evidence of inflammation or effusion. The abdominal lymph nodes are normal/not visible.

WEIGHT

60.7 lbs.

ULTRASONOGRAPHIC FINDINGS

- Non-specific diffuse hepatopathy. Differentials include inflammatory/immune-mediated disease, hepatotoxicosis (i.e., copper), leptospirosis (less likely if the liver enzyme elevations are chronic), reactive hepatopathy, infiltrative neoplasia (less likely) +/- concurrent and age-related pathology.
- The gastric wall lesion may represent an area of emerging neoplasia or a focus of inflammation or hypertrophy.

INTERPRETED BY

Andrea Nicastro, DVM,
Diplomate ACVIM
(*Small Animal Internal
Medicine*)

INTERPRETATION OF THE FINDINGS & FURTHER RECOMMENDATIONS

1. Three-view thoracic radiographs are recommended to assess cardiopulmonary status, if not already performed.
2. If an aggressive approach is desired, consider an abdominal exploratory with surgical biopsies of the liver and thickened gastric wall. Aerobic and anaerobic bile cultures and acquisition of additional hepatic tissue samples for copper quantitation are also recommended at the time of surgery. If a more conservative approach is desired, consider empirical treatment for cholangiohepatitis (amoxicillin-clavulanic acid, Denamarin Advanced). If no improvement in the liver values is seen within 7-10 days of initiating therapy, antibiotics should be discontinued, and hepatic tissue sampling reconsidered. If liver values improve, continue therapy for at least 4-6 weeks and 1 week beyond normalization of the liver values. If surgery is not pursued, a repeat abdominal ultrasound in 2-3 weeks is recommended to assess for progression of the gastric wall lesion.

**IMAGING
PERFORMED BY**

Potomac Mobile
Veterinary Ultrasound

HOSPITAL NAME

Banfield Leesburg

REFERRING VET

Dr. Jarrett

INVOICE

11848kk

DATE

9/17/21



PATIENT

Berkely Asselin

SPECIES

Canine

BREED

Boxer

SEX

Female Spayed

AGE

11 Years 2 Months

WEIGHT

60.7 lbs.

INTERPRETED BY

Andrea Nicastro, DVM,
Diplomate ACVIM
(Small Animal Internal
Medicine)

IMAGING PERFORMED BY

Potomac Mobile
Veterinary Ultrasound

HOSPITAL NAME

Banfield Leesburg

REFERRING VET

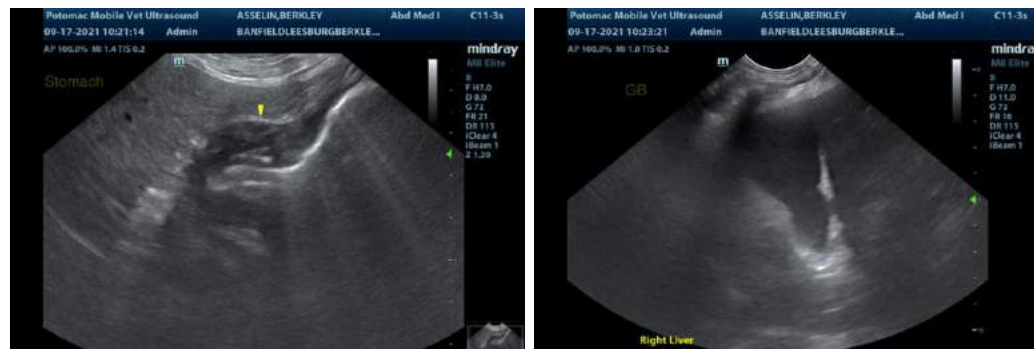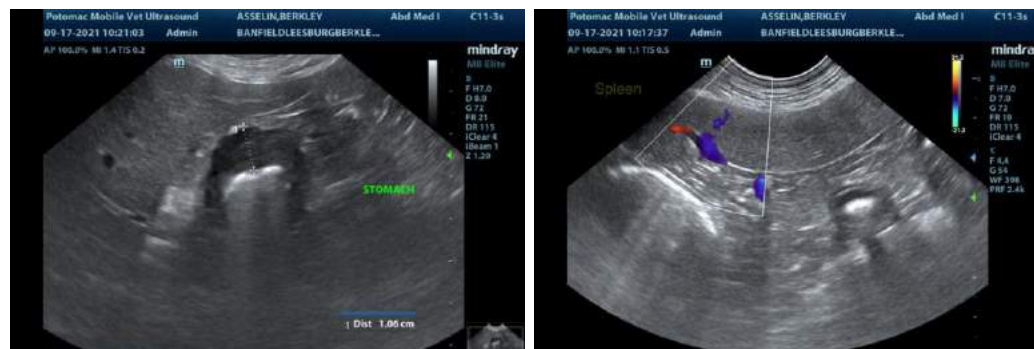
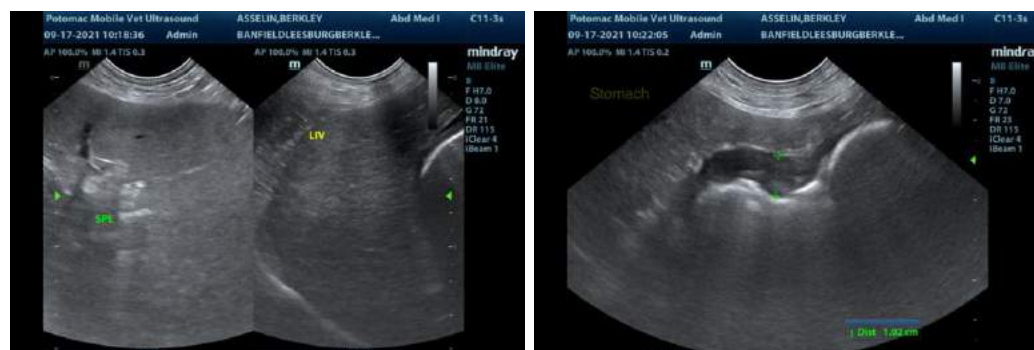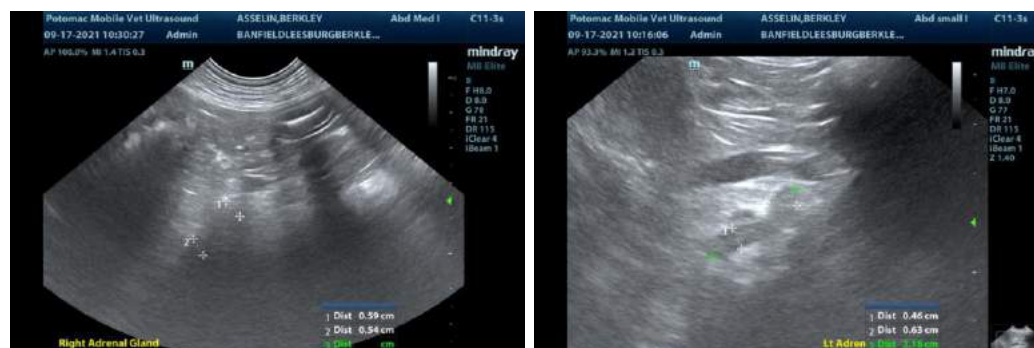
Dr. Jarrett

INVOICE

11848kk

DATE

9/17/21





PATIENT

Berkely Asselin

SPECIES

Canine

BREED

Boxer

SEX

Female Spayed

AGE

11 Years 2 Months

WEIGHT

60.7 lbs.

INTERPRETED BY

Andrea Nicastro, DVM,
Diplomate ACVIM
(*Small Animal Internal
Medicine*)

IMAGING PERFORMED BY

Potomac Mobile
Veterinary Ultrasound

HOSPITAL NAME

Banfield Leesburg

REFERRING VET

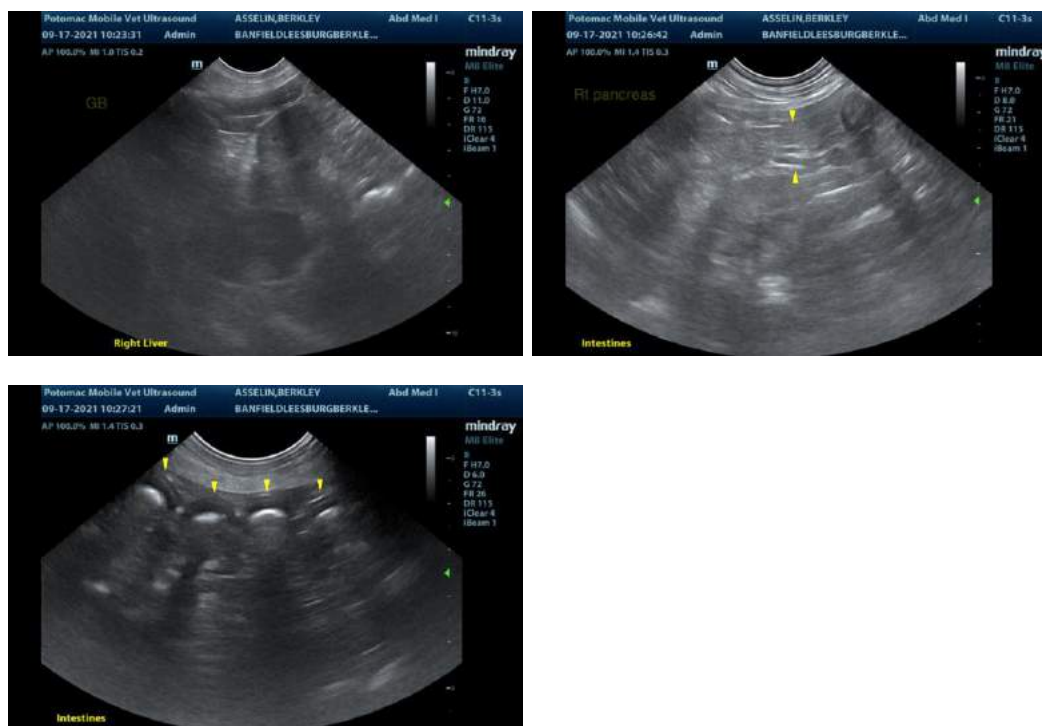
Dr. Jarrett

INVOICE

11848kk

DATE

9/17/21



The information and recommendations provided are based on the images presented by the referring veterinarian. No evaluation can be communicated regarding pathology that was not visible in the image/video clips provided.

Thank you for this referral. If the clinical or image interpretation does not parallel your findings or if I can be of any further assistance, please contact me.

Andrea Nicastro, DVM, Diplomate ACVIM (*Small Animal Internal Medicine*)
Andrea.nicastro@sonopath.com