

**DATE PRESENTING CLINICAL SIGNS**

9/16/21 History: decreased appetite for the past few weeks; has lost 3# since May.

**PATIENT** Current Medications: Not provided by the veterinarian.

Bella Blauvelt Lab Results: Increased ALT at 253 and ALKP at 239. Globulins are 4.2. Thrombocytosis. T4 is borderline low.

**SPECIES** Radiographs: Not provided by the veterinarian.

Canine Date of Previous IntraPet Ultrasound: No previous IntraPet scans.

**BREED** Sedation: not needed

Mixed Breed Dog Stat Report: not requested

**SEX ULTRASONOGRAPHIC EXAMINATION OF THE ABDOMEN**

Female Spayed *Urinary System*

The urinary bladder, trigone, and pelvic urethra are normal in thickness and the mucosal surface is smooth. The bladder lumen is moderately distended with anechoic urine. No masses, inflammatory changes or calculi are observed. Ureteral papillae and visualized portion of the proximal urethra, visible to a depth of 2 cm, are normal.

**AGE**

9/14/06

**WEIGHT**

14 lbs.

The left kidney is normal size (4.67cm in length); normal shape and architecture with smooth peripheral margins. There is a normal 1:3 cortex to medulla ratio with minimal loss of corticomedullary distinction. There is no evidence of pyelectasia, nephroliths, infarcts or hydroureter. Renal vasculature is normal.

**INTERPRETED BY**

Andrea Nicastro, DVM,  
Diplomate ACVIM  
(Small Animal Internal  
Medicine)

The right kidney is normal size (3.91 cm in length); normal shape and architecture with smooth peripheral margins. There is a normal 1:3 cortex to medulla ratio with minimal to mild loss of corticomedullary distinction. Trace pyelectasia is present (0.18 cm in the longitudinal plane). There is no evidence of nephroliths, infarcts or hydroureter. Renal vasculature is normal.

**HOSPITAL NAME**

Charm City VH

*Adrenal Glands*

The left adrenal gland is enlarged (0.66 cm at cranial pole) (1.22 cm at caudal pole) (2.82 cm in length) with a prominent caudal pole. The parenchyma is mildly heterogeneous in appearance with a few small hypoechoic to anechoic areas and loss of glandular detail. The phrenicoabdominal vein and surrounding vasculature appear normal.

**REFERRING VET**

Dr. Karbonik

The right adrenal gland is mildly enlarged (0.66 cm at cranial pole) (0.89 cm at caudal pole) (2.70 cm in length) with a slightly irregular shape. The parenchyma is subtly heterogeneous in appearance. No distinct focal lesions are observed. The phrenicoabdominal vein and surrounding vasculature appear normal.

**INVOICE**

11839kk

*Spleen*

The spleen is normal in size (0.85 cm in width at the level of the hilus) with a normal capsular contour. There is appropriate echogenicity and echotexture. A 0.65 cm hypoechoic nodule is observed within the parenchyma. In addition, a few small myelolipomas are observed in the region of the hilus. Splenic vasculature is normal.

*Liver*

The liver is subjectively normal in size with normal curvilinear peripheral contours. The parenchyma is hypoechoic relative to the spleen and subtly mottled in appearance. A 0.90 cm hyperechoic nodule is observed on the left side. Hepatic vasculature and intrahepatic biliary tracts are of normal volume with no

evidence of congestion. The gall bladder lumen is moderately distended. The wall is thin and smooth. A small to moderate amount of aggregated, echogenic, partially dependent debris is observed within the lumen. The debris is in a questionable, partial stellate pattern. The cystic and common bile ducts are normal/not seen.

### ***Gastrointestinal***

The stomach and intestine are free of stasis and exhibit normal peristaltic activity. The gastric lumen is not distended. The gastric wall and pylorus are normal in thickness with a normal layering pattern. The pyloric outflow tract is patent. The small intestinal lumen is not dilated. The small intestinal wall thickness is normal with a normal layering pattern and appropriate mural detail. Discreet masses are not identified. The colonic wall is normal. No obstructive disease is noted.

### ***Pancreas***

The region of the pancreas is isoechoic relative to surrounding omental fat. No obvious parenchymal abnormalities are observed. There is no evidence of regional inflammation or effusion.

### ***Free Abdomen***

The peritoneal cavity is normal. There is no evidence of inflammation or effusion. The abdominal lymph nodes are normal/not visible.

### ***Other***

A brief echocardiogram reveals no evidence of pericardial effusion.

## **ULTRASONOGRAPHIC FINDINGS**

### **Primary Findings:**

- Bilateral adrenomegaly, consistent with hyperplastic change.
- Non-specific diffuse hepatopathy. Differentials include inflammatory/immune-mediated disease, hepatotoxicosis (i.e., copper), emerging neoplasia, reactive hepatopathy +/- concurrent regenerative nodular hyperplasia, age-related remodeling and/or vacuolar hepatopathy.
- Gall bladder debris/sludge. Differentials include cholestasis, fasting, or early mucocele formation.

### **Secondary Findings:**

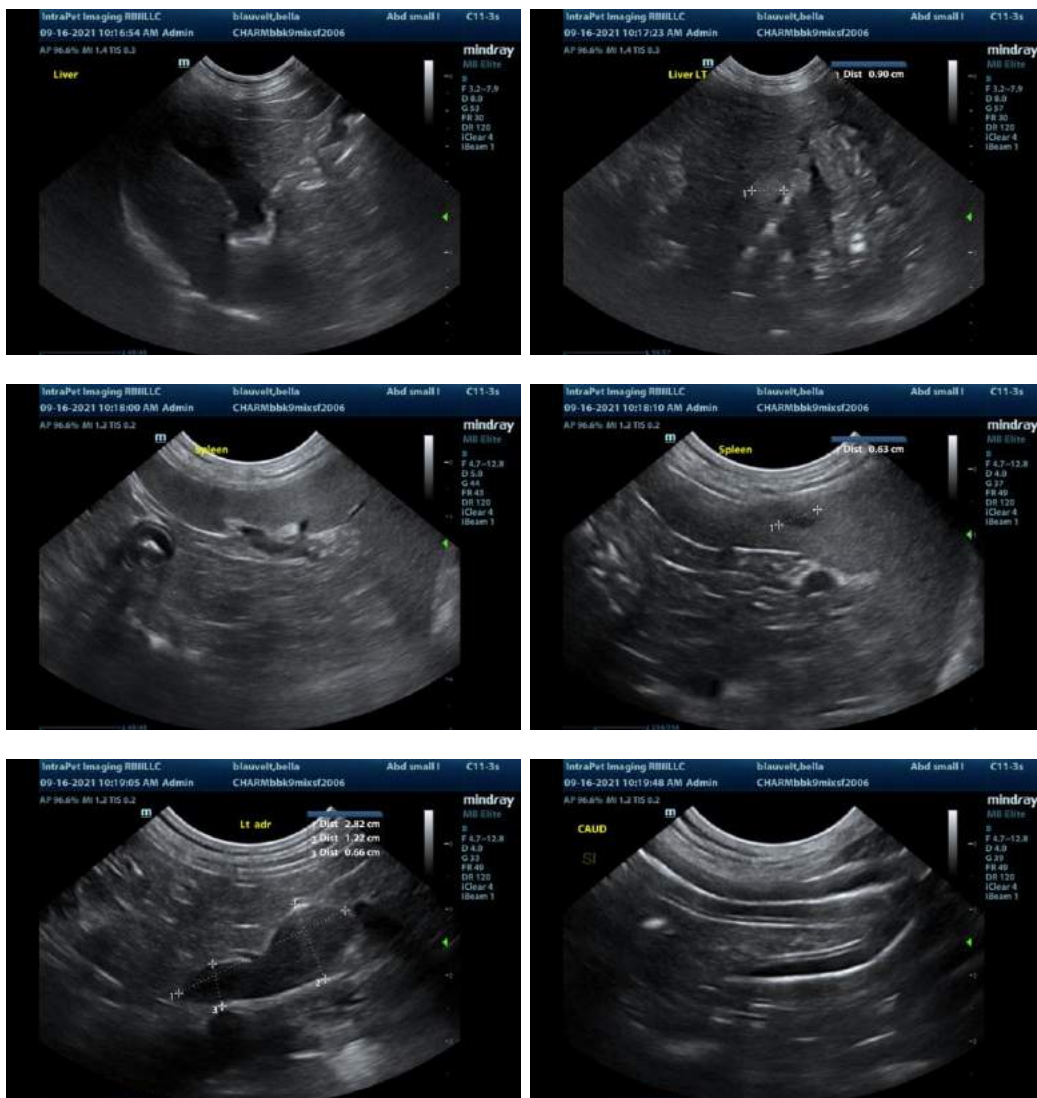
- Minor, bilateral, age-related renal changes with trace right pyelectasia.
- The hypoechoic splenic nodule trends towards the benign with a lower possibility of emerging neoplasia.

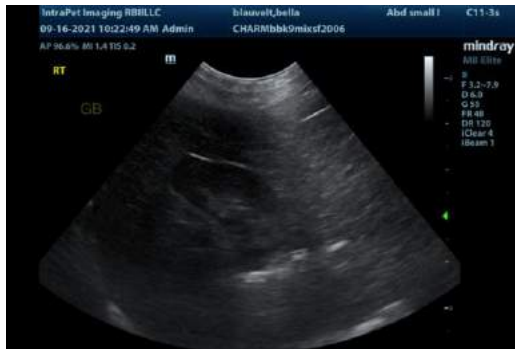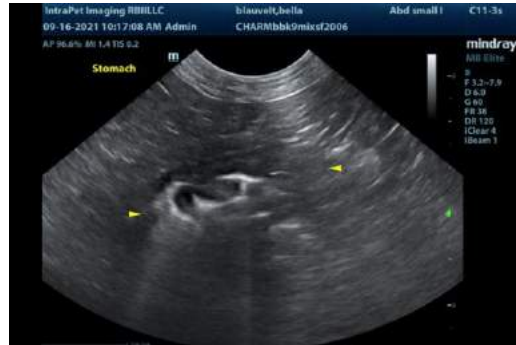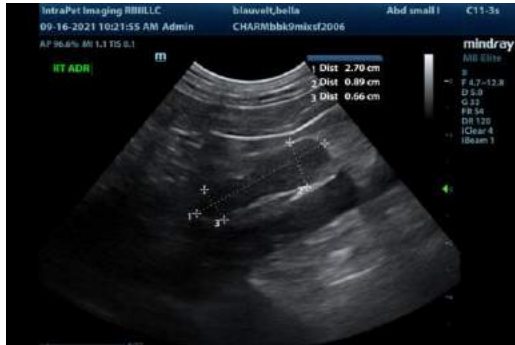## **INTERPRETATION OF THE FINDINGS & FURTHER RECOMMENDATIONS**

Consider the following diagnostics:

1. Pre- and post-prandial serum bile acids
2. Fine needle aspirate of the liver (if clotting status is appropriate). A 25-gauge needle should be used.
3. Leptospirosis testing (i.e., blood and urine PCR; serology) should also be considered, particularly if the disease is endemic to the patient's geographic region.

4. Three-view thoracic radiographs are recommended to assess for occult neoplasia.
5. Depending on the results of the above diagnostics, further GI work up (i.e., malabsorption panel, fecal evaluation for ova and Giardia +/- endoscopic or surgical gastrointestinal biopsies) may be necessary to get a definitive diagnosis.
6. Consider testing for hyperadrenocorticism with a low-dose dexamethasone suppression test or ACTH stimulation test if clinical signs (i.e., PU/PD) develop.





The information and recommendations provided are based on the images presented by the referring veterinarian. No evaluation can be communicated regarding pathology that was not visible in the image/video clips provided.

Thank you for this referral. If the clinical or image interpretation does not parallel your findings or if I can be of any further assistance, please contact me.

Andrea Nicastro, DVM, Diplomate ACVIM (*Small Animal Internal Medicine*)  
Andrea.nicastro@sonopath.com