

**DATE PRESENTING CLINICAL SIGNS**

9/14/21

Presented for eval for Dental. Inappetence. Abnormal labs.

PATIENT

Winkie Whittaker

Current Medications: Benazepril 5mg 1/2 PO QD
 Lab Results: elevated SDMA and Creatinine, 4+ Protein on UA
 Date of Previous IntraPet Ultrasound: No previous
 Sedation: not needed
 Stat Report: not requested

SPECIES

Canine

BREED

Mixed breed

SEX

Female, spayed

AGE

2013

WEIGHT

10 lbs.

INTERPRETED BY

Andrea Nicastro, DVM,
 Diplomate ACVIM
 (Small Animal Internal
 Medicine)

HOSPITAL NAME

Festival Veterinary
 Clinic

REFERRING VET

Dr. Cianelli

INVOICE

12081

ULTRASONOGRAPHIC EXAMINATION OF THE ABDOMEN**Urinary System**

The urinary bladder, trigone, and pelvic urethra are normal in thickness and the mucosal surface is smooth. The bladder lumen is moderately distended with anechoic urine. No masses, inflammatory changes or calculi are observed. Ureteral papillae and visualized portion of the proximal urethra, visible to a depth of 2 cm, are normal.

The left kidney is normal size (3.85 cm in length); normal shape and architecture with smooth peripheral margins. There is a normal 1:3 cortex to medulla ratio with normal corticomedullary distinction. There is no evidence of pyelectasia, nephroliths, infarcts or hydroureter. Renal vasculature is normal.

The right kidney is normal size (3.57 cm in length); normal shape and architecture with smooth peripheral margins. There is a normal 1:3 cortex to medulla ratio with minimal to mild loss of corticomedullary distinction. There is no evidence of pyelectasia, nephroliths, infarcts or hydroureter. Renal vasculature is normal.

Adrenal Glands

The left adrenal gland is normal size (0.40 cm at cranial pole) (0.35 cm at caudal pole) (1.08 cm in length); normal shape; homogenous parenchyma. The glandular echogenicity and detail are unremarkable. Capsule, cortex, and medullary definition are normal. The phrenicoabdominal vein and surrounding vasculature are normal.

The right adrenal gland is normal size (0.62 cm at cranial pole) (0.51 cm at caudal pole) (1.70 cm in length); normal shape; homogenous parenchyma. The glandular echogenicity and detail are unremarkable. Capsule, cortex, and medullary definition are normal. The phrenicoabdominal vein and surrounding vasculature are normal.

Spleen

The spleen is normal in size (1.26 cm in width at the level of the hilus) with a normal capsular contour. The parenchyma is slightly mottled in appearance. No focal lesions are observed. Splenic vasculature is normal.

Liver

The liver is subjectively normal in size with normal curvilinear peripheral contours. The parenchyma is hypoechoic relative to the spleen with minor changes consistent with age-related remodeling. No focal lesions are observed. Hepatic vasculature and biliary tracts are of normal volume with no evidence of congestion. The gall bladder lumen is moderately distended. The wall is thin and smooth. A small amount of aggregated echogenic suspended debris is observed within the lumen. The cystic and common bile ducts are normal/not seen.

Gastrointestinal

The stomach and intestine are free of stasis and exhibit normal peristaltic activity. The gastric lumen is not distended. The gastric wall and pylorus are normal in thickness with a normal layering pattern. The pyloric outflow tract is patent. The small intestinal lumen is not dilated. The small intestinal wall thickness is normal.

with a normal layering pattern and appropriate mural detail. Discreet masses are not identified. The colonic wall is normal. No obstructive disease is noted.

Pancreas

The pancreas is normal in size with normal peripheral contours. The pancreatic duct is normal. The base and limbs of the pancreas are isoechoic to surrounding omental fat. No focal lesions are observed. There is no evidence of peripancreatic inflammation or effusion.

Free Abdomen

The peritoneal cavity is normal. There is no evidence of inflammation or effusion. The abdominal lymph nodes are normal/not visible.

ULTRASONOGRAPHIC FINDINGS

Primary Findings:

- The clinical history and sonographic renal changes are consistent with a protein-losing nephropathy.

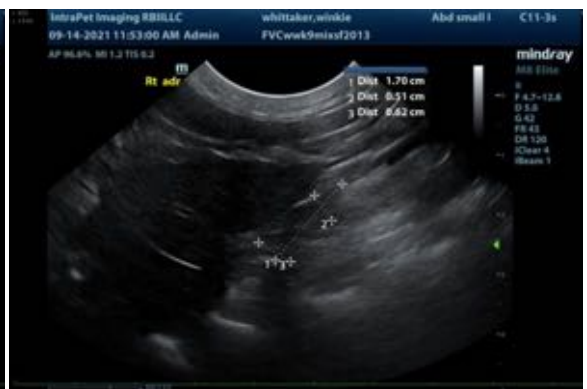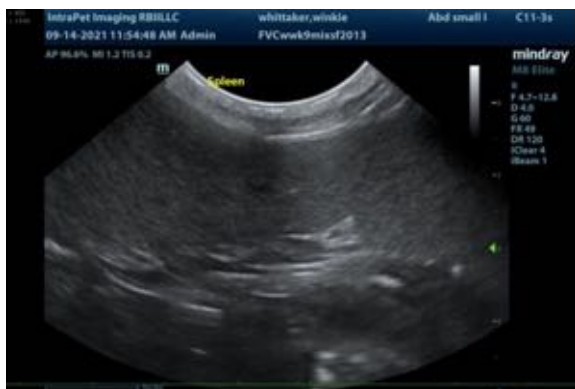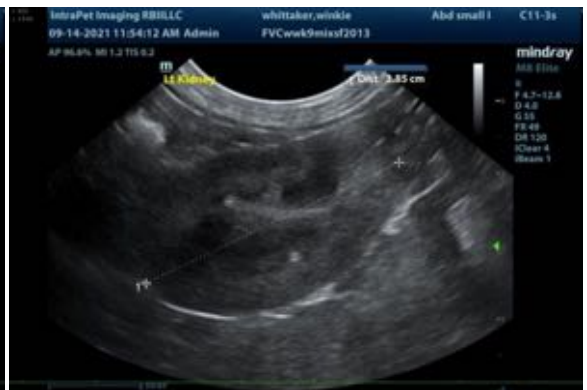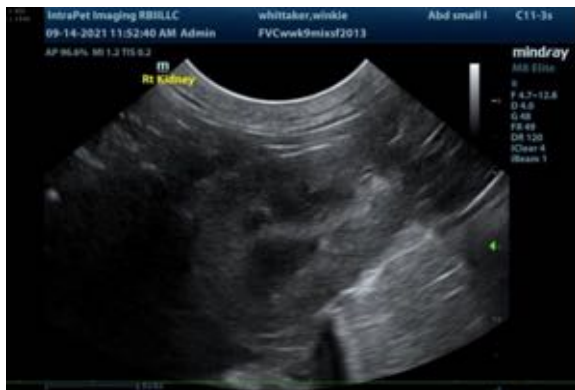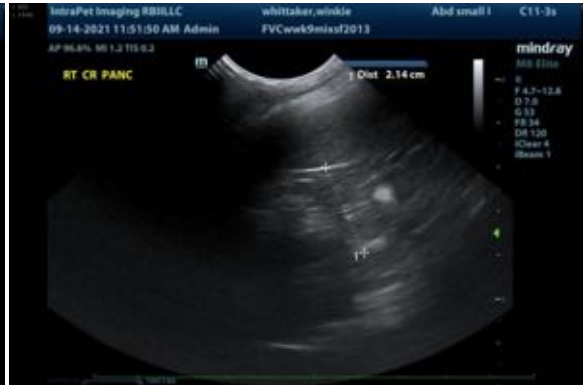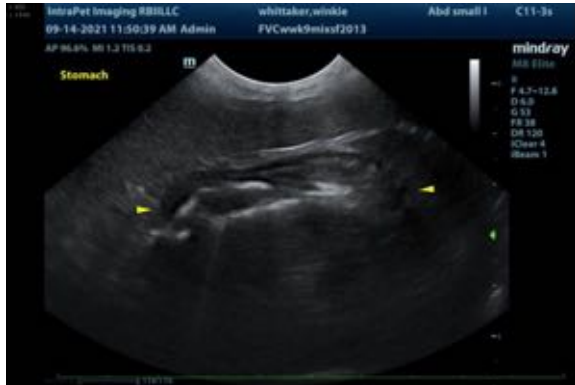Secondary Findings:

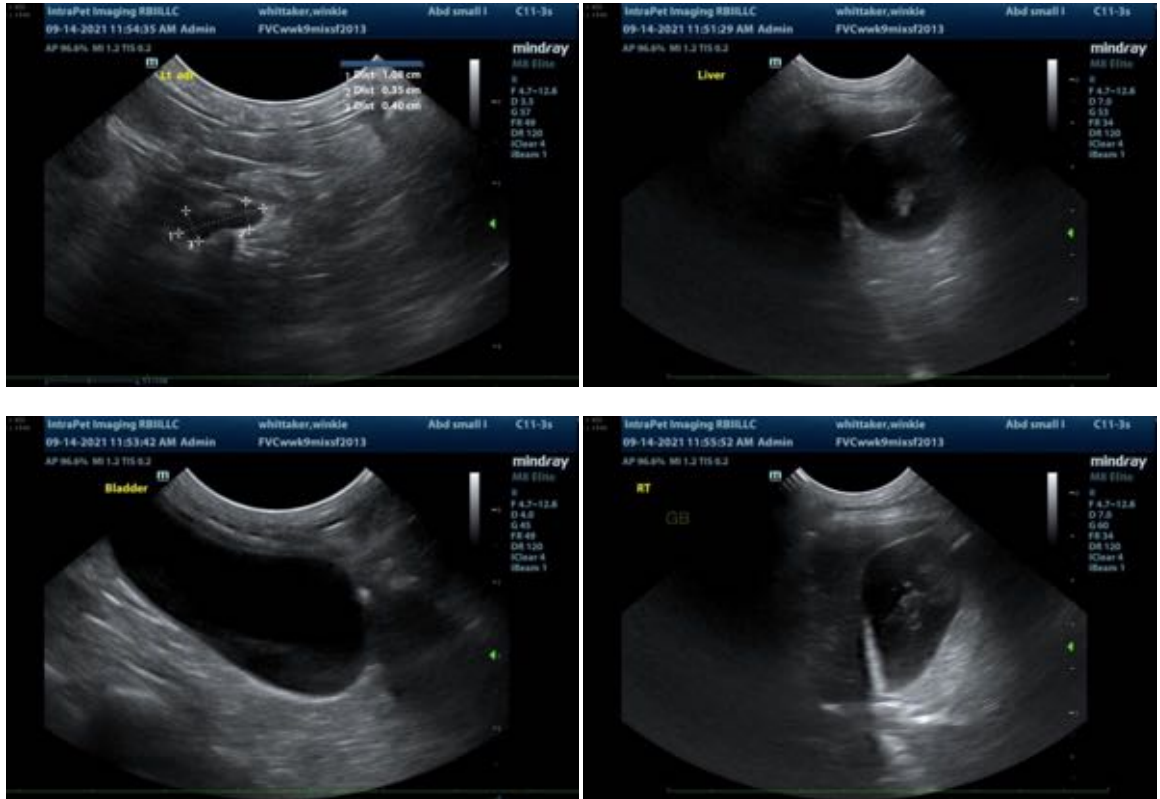
- The hepatic changes are consistent with age-related parenchymal remodeling and are not considered clinically significant at this time.
- The splenic parenchyma changes are most consistent with a benign process such as lymphoid hyperplasia, extramedullary hematopoiesis or splenitis with a low possibility of infiltrative neoplasia (i.e., lymphoma, mast cell neoplasia).

INTERPRETATION OF THE FINDINGS & FURTHER RECOMMENDATIONS

Consider the following diagnostic and treatment recommendations for protein-losing nephropathy:

- 1 Urine culture and sensitivity
- 2 UPC
- 3 Baseline blood pressure measurement with serial monitoring thereafter
- 4 Further testing for neoplasia (i.e., three-view thoracic radiographs) and infectious diseases (i.e., comprehensive tick panel).
- 5 Angiotensin II receptor blocker (e.g., Telmisartan)
- 6 Antithrombotic (e.g., Clopidogrel at 2.5 mg/kg PO q 24 hours)
- 7 Omega-3 fatty acids (65 mg/kg of DHA and EPA combined daily)
- 8 Prescription renal diet
- 9 Routine monitoring of UPC and bloodwork (CBC, chemistry panel) to assess for progressive disease





The information and recommendations provided are based on the images presented by the referring veterinarian. No evaluation can be communicated regarding pathology that was not visible in the image/video clips provided.

Thank you for this referral. If the clinical or image interpretation does not parallel your findings or if I can be of any further assistance please contact me.

Andrea Nicastro, DVM, Diplomate ACVIM (*Small Animal Internal Medicine*)
Andrea.nicastro@sonopath.com