

**DATE PRESENTING CLINICAL SIGNS**

9/14/2021

Vomiting.

History: Date: 09-13-2021 Notes: Has had a few episodes of diarrhea in the past. Responds to metronidazole. Has been on homemade diet

PATIENT

Mowgli Gupte

(chicken, some grains, homemade yogurt) for a few months. Just started transitioning kibble (Canidae) back into diet. Vomited once about 4-5 days ago but was still eating normally and no other issues. This afternoon she vomited (about 8 hours ago) multiple times in a row; would drink then vomit again; after they withheld water she would go 30-45 minutes between episodes. Vomiting mucus. Passed normal stool today.

SPECIES

Canine

Current Medications: Buprenorphine 0.6mg/mL, Pantoprazole (Protonix) 40mg/vial Injection (Per mL), Ondansetron 2mg/mL Injection (Per mL), Ampicillin 125mg/vial Injection (Per mL)

Lab Results: ALP 238, ALT 135

BREED

Golden retriever

Date of Previous IntraPet Ultrasound: No previous

Sedation: not needed

Stat Report: not requested

SEX

Male, neutered

ULTRASONOGRAPHIC EXAMINATION OF THE ABDOMEN**Urinary System**

The urinary bladder, trigone, and pelvic urethra are normal in thickness and the mucosal surface is smooth. The bladder lumen is moderately distended with anechoic urine. No masses, inflammatory changes or calculi are observed. Ureteral papillae and visualized portion of the proximal urethra, visible to a depth of 2 cm, are normal.

AGE

7/12/2020

WEIGHT

88.1 lbs.

The prostate is normal in size (1.39 cm in width) and shape. Parenchyma is homogenous. The prostatic urethra appears normal without evidence of dilation or obstruction.

The left kidney is normal size (7.78 cm in length); normal shape and architecture with smooth peripheral margins. There is a normal 1:3 cortex to medulla ratio with normal corticomedullary distinction. There is no evidence of pyelectasia, nephroliths, infarcts or hydroureter. Renal vasculature is normal.

INTERPRETED BY

Andrea Nicastro, DVM,
 Diplomate ACVIM
 (Small Animal Internal
 Medicine)

The right kidney is normal size (6.91 cm in length); normal shape and architecture with smooth peripheral margins. There is a normal 1:3 cortex to medulla ratio with normal corticomedullary distinction. There is no evidence of pyelectasia, nephroliths, infarcts or hydroureter. Renal vasculature is normal.

HOSPITAL NAME

Animal Emergency
 Hospital

Adrenal Glands

The left adrenal gland is normal size (0.57 cm at cranial pole) (0.66 cm at caudal pole) (2.71 cm in length); normal shape; homogenous parenchyma. The glandular echogenicity and detail are unremarkable. Capsule, cortex, and medullary definition are normal. The phrenicoabdominal vein and surrounding vasculature are normal.

REFERRING VET

Dr. Martinoli

The right adrenal gland is normal size (0.66 cm at cranial pole) (0.78 cm at caudal pole) (2.90 cm in length); normal shape; homogenous parenchyma. The glandular echogenicity and detail are unremarkable. Capsule, cortex, and medullary definition are normal. The phrenicoabdominal vein and surrounding vasculature are normal.

INVOICE

12080

Spleen

The spleen is normal in size (2.13 cm in width at the level of the hilus) with a normal capsular contour. There is appropriate echogenicity and echotexture. No focal lesions are observed. Splenic vasculature is normal.

Liver

The liver is subjectively normal in size with normal curvilinear peripheral contours. The parenchyma is hypoechoic relative to the spleen and heterogeneous in appearance. There is an increase in portal markings.

Hepatic vascular appears slightly dilated. The gall bladder lumen is moderately distended. The wall is diffusely thickened (up to 0.72 cm) and hypoechoic/edematous with a “double walled” effect. Luminal contents are anechoic. The cystic and common bile ducts are normal/not seen.

Gastrointestinal

The stomach and intestine are free of stasis and exhibit normal peristaltic activity. The gastric lumen is mildly gas distended. The gastric wall and pylorus are normal in thickness with a normal layering pattern. The pyloric outflow tract is patent. The small intestinal lumen is not dilated. The small intestinal wall thickness is normal with a normal layering pattern and appropriate mural detail. Discreet masses are not identified. The colonic wall is normal. No obstructive disease is noted.

Pancreas

The right limb of the pancreas is prominent in size with minimal deviation from the normal peripheral contours. The parenchyma is hypoechoic relative to surrounding omental fat. No distinct focal lesions are observed. The pancreatic duct is not overtly dilated. Surrounding mesentery is mildly hyperechoic.

Free Abdomen

Trace free fluid is observed. A 0.99 cm hypoechoic lymph node is observed in the right cranial quadrant.

Other

A brief echocardiogram reveals no evidence of pericardial effusion.

ULTRASONOGRAPHIC FINDINGS

Primary Findings:

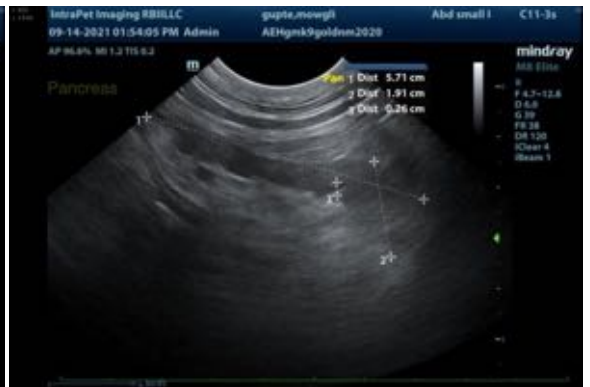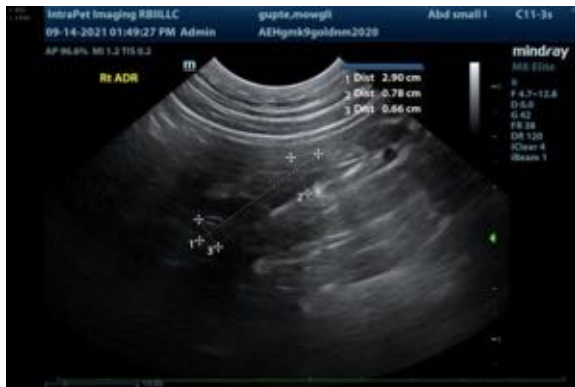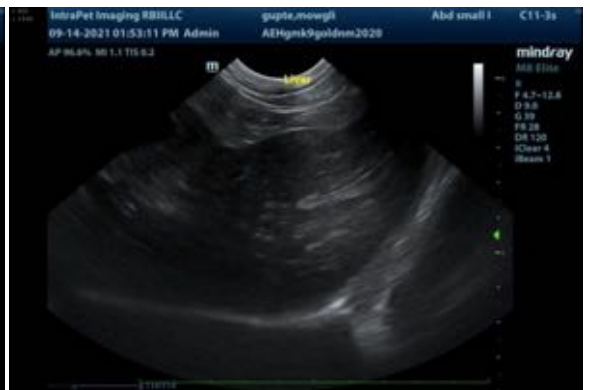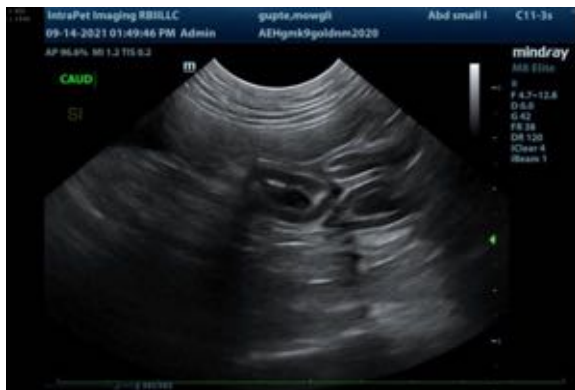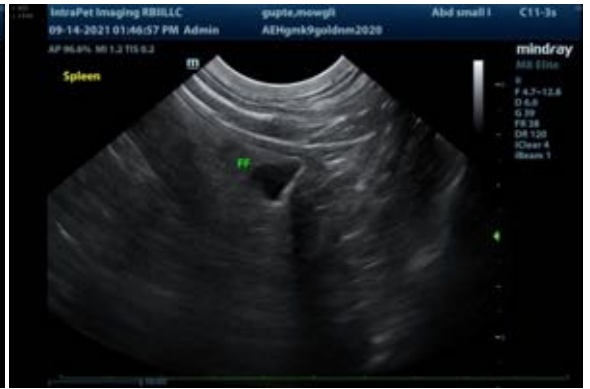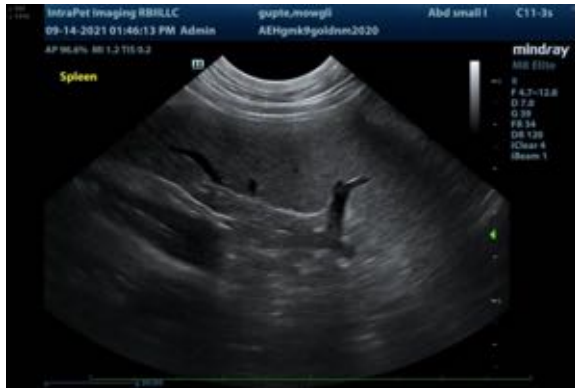- The pancreatic changes are consistent with mild to moderate pancreatitis with regional peritonitis.
- The hepatic parenchymal changes are most consistent with inflammatory disease with a lower possibility of hepatotoxicosis or infiltrative neoplasia. A reactive hepatopathy is also possible.
- The gallbladder wall changes could be consistent with cholecystitis, increased hydrostatic pressure (i.e., fluid overload), anaphylaxis, other.

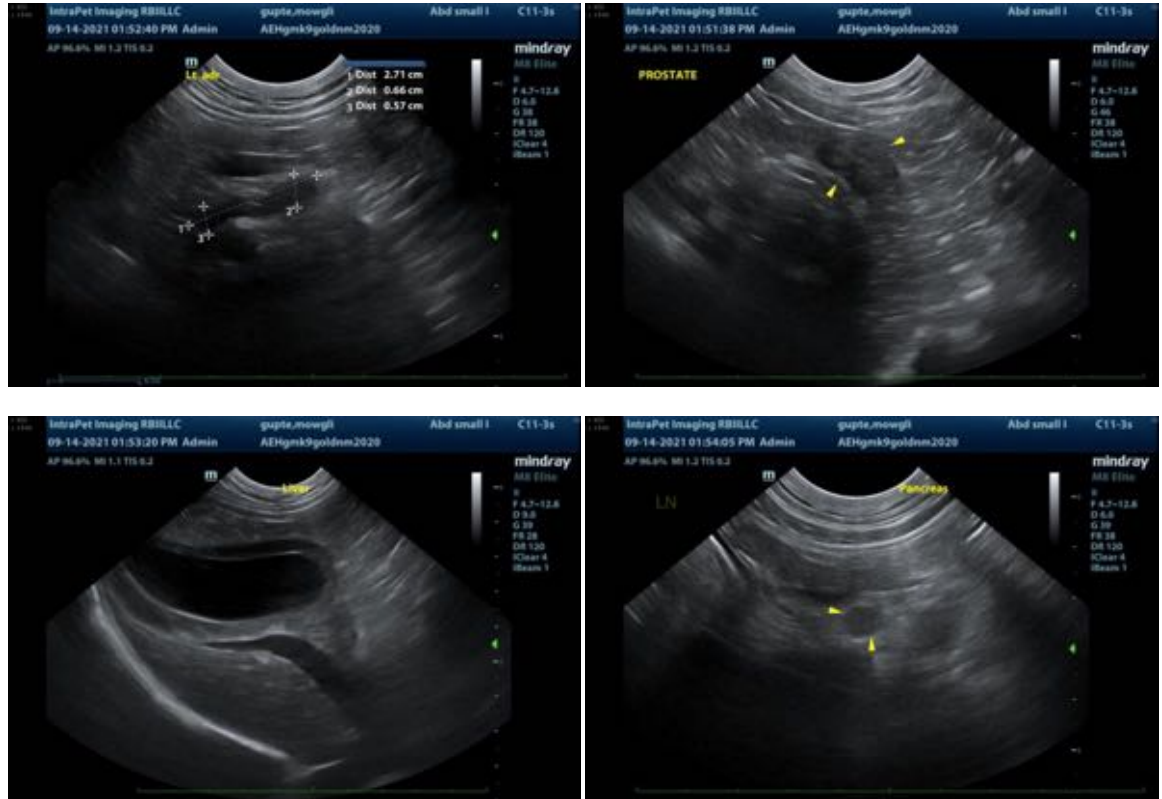
Secondary Findings:

- The prominent lymph node in the right cranial quadrant is likely due to reactive lymphadenitis.

INTERPRETATION OF THE FINDINGS & FURTHER RECOMMENDATIONS

- Supportive care for pancreatitis is recommended including IV fluid therapy, gastric protectants, antiemetics, pain medication as needed, +/- fresh frozen plasma. Consider serial sonographic monitoring of the pancreas to assess for progression.
- A fine needle aspirate of the liver can be considered if clotting status is appropriate. A 25-gauge needle should be used. If a more conservative approach is desired, consider empirical treatment for cholecystitis/cholangitis. If liver values do not show improvement within 7-10 days of initiating therapy, antibiotics should be discontinued and tissue sampling revisited.
- Leptospirosis testing (i.e., blood and urine PCR, serology) should also be considered.
- Three-view thoracic radiographs are also recommended to assess cardiopulmonary status.





The information and recommendations provided are based on the images presented by the referring veterinarian. No evaluation can be communicated regarding pathology that was not visible in the image/video clips provided.

Thank you for this referral. If the clinical or image interpretation does not parallel your findings or if I can be of any further assistance please contact me.

Andrea Nicastro, DVM, Diplomate ACVIM (*Small Animal Internal Medicine*)
 Andrea.nicastro@sonopath.com